

See discussions, stats, and author profiles for this publication at: <https://www.researchgate.net/publication/320300262>

Determination of Probable Reproduction Season of Individually Tagged Siberian and Diamond Sturgeon Broodstock, Which are Newly Rised, Via Steroid Hormones, Haematological Changes...

Article in *Fresenius Environmental Bulletin* · October 2017

CITATION

1

READS

175

1 author:



[Kübra ak](#)

Recep Tayyip Erdoğan Üniversitesi

12 PUBLICATIONS 16 CITATIONS

[SEE PROFILE](#)

DETERMINATION OF PROBABLE REPRODUCTION SEASON OF INDIVIDUALLY TAGGED SIBERIAN, *ACIPENSER BAERII*, AND DIAMOND, *A. GUELLENSTAEDTII*, STURGEON BROODSTOCK, WHICH ARE NEWLY RISED, VIA STEROID HORMONES, HAEMATOLOGICAL CHANGES AND ULTRASOUND IMAGERY

Kubra Ak*, Ilker Zeki Kurtoglu

Recep Tayyip Erdogan University, Faculty of Fisheries Sciences, Department of Aquaculture, Rize, Turkey

ABSTRACT

In this study, it is aimed to determine the gonadal development and gender of the Siberian (*Acipenser baerii*) and diamond (*A. gueldenstaedtii*) sturgeon species by using ultrasonography and blood parameters in aquaculture conditions.

A total of 15 Siberian and 15 diamond sturgeon individuals from broodstock candidates at the ages of 4+ years were selected and tagged. We used ultrasound examination and hematocrit, erythrocyte, leukocyte, hemoglobin values in blood, followed by calcium, sodium ions and steroids (estradiol (E₂), testosterone (T) and progesterone (P)) in blood plasma in monthly periods between December 2015 and June 2016.

Siberian sturgeon individuals were detected as 7 female and 8 male; and 7 females and 7 males were determined in diamond sturgeons, and 1 individual had no gender in ultrasound imaging.

Successful gender detection was performed by ultrasound imaging. Depending on the results of hemogram testing, probable gamete production period can be determined according to the changes of hematocrit, erythrocyte, leukocyte, hemoglobin and sex steroids. In this results, hemogram values increased between May and June in diamond sturgeon while peaking in January-February for Siberian sturgeon. However, there was no obvious change in calcium and sodium ions.

At the end of the study, it was concluded that blood analysis can be used effectively, when the main gamete maturation season of the newly produced broodstock population is decided. On the other hand, the ultrasonography is the easiest way to determine bloods' gender and maturation level.

KEYWORDS:

Maturity stage, sturgeon, ultrasonography, hematology, sex steroids.

INTRODUCTION

Sturgeons exist in the seas of Europe, Asia and America continents in northern hemisphere. They also exist along the coastal areas of Pacific and Atlantic Oceans, in the Mediterranean, in the Black Sea, Caspian Sea, and in the rivers that run to these seas and in several lakes [1].

Sturgeon are species with a high economic and ecologic value. However, overfishing, river reclamation works, water pollution, the banks built over rivers cause that this fish has almost become extinct [1].

In sturgeon species, the determination of gender and receiving gamete must be conducted without killing the fish in a reliable and practical way. The determination of gender and gonadal maturity stage especially in sturgeon species, which do not show sexual dimorphism, and which have late sexual maturity, is extremely important for broodstock management [2].

Endoscopy, gonadal biopsy, sex steroids, laparoscopy, morphology and ultrasonography methods are used to determine the gender and gonadal maturity in sturgeons [2, 3, 4, 5, 6, 7, 8].

There are many studies in the literature conducted to determine the gender and gonadal maturity in sturgeon, and many different methods have been reported in these studies. However, no studies were seen in the literature in which the changes in the blood parameters and gonadal developments were investigated in the long run in a parallel way in and out of the reproduction period of sturgeons. In this study, the purpose is to determine the gender and gonadal development by analyzing the blood parameters and using ultrasonic examinations in an 8-month period without causing any damage in Siberian (*Acipenser baerii*) and diamond (*A. gueldenstaedtii*) sturgeon species.

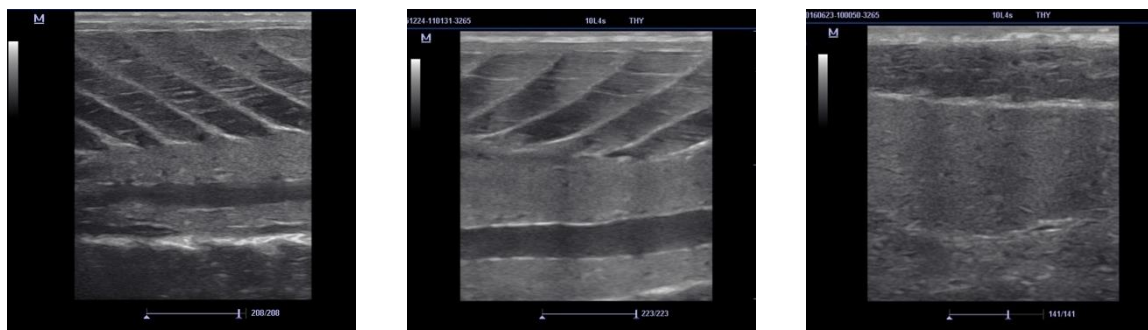

FIGURE 1
Typical ultrasonic images of testes in different maturity stages in the longitudinal views, M₁; left, M₂; mid, M₃; right

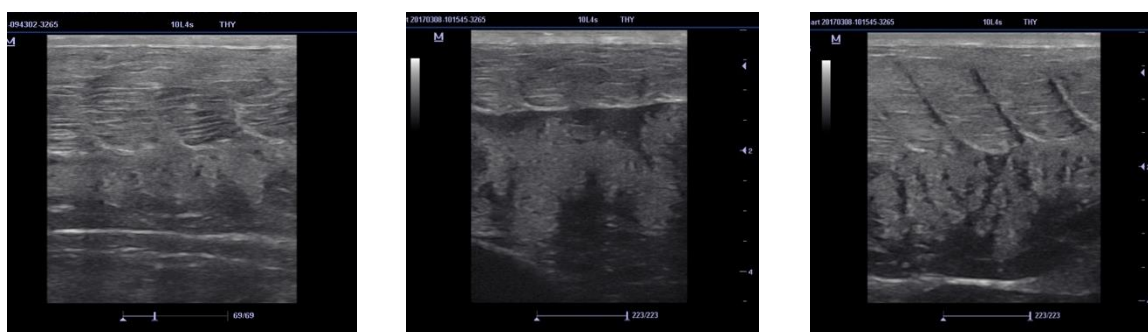

FIGURE 2
Typical ultrasonic images of ovaries in different maturity stages in the longitudinal views, F₁; left, F₂; mid, F₃; right

MATERIALS AND METHODS

The study was conducted in Recep Tayyip Erdogan University, Aquaculture Research and Application Center in November 2015-June 2016 period. The broodstock candidate fish were imported from Germany as fertilized eggs in December 2011. Fifteen of Siberian and 15 diamond sturgeon species, which had smooth body forms and which were at the age of 4⁺ were selected from among the broodstock candidate fish. The average weight of the fish was 4.2±1.2 kg. The fish were tagged individually, and stocked in fiberglass tanks at the size of 3m in diameter and 1m water depth in 10 m³/kg. The water provided from the streams was used in the caretaking of the fish.

Ultrasonographic Examinations. The fish were examined in monthly intervals. The *MINDRAY 5M* ultrasound imaging was made by using an electronic 10L4s linear probe with 8.0-12.0 MHz frequency. The examinations were made without applying any anesthetics on stretchers covered by soft towel. In ultrasound examinations, the frontal and transversal images between the 3-4th bone plates as of the ventral fin were evaluated. By using the ultrasound images, the genders and gonadal maturity lev-

els of the fish were decided according to the morphology and echogenicity of the ovarium and testis tissues (the brightness of the tissues).

Blood Analysis. The blood samples were taken with a 2.5-ml injector from caudal vena, and transferred to heparinized tubes. The erythrocyte, leucocyte, hematocrit and hemoglobin values of the samples were measured in the PROKAN brand blood measurement device simultaneously. The samples whose blood counts were completed were centrifuged at 5,000 rpm⁻¹ for 10 minutes to obtain the blood plasma. Then, samples were stocked in deep freezer (-80°C) up to analysing.

The analysis of the steroid hormones (Estradiol, testosterone and progesterone) from the blood plasma was made with Radioimmunoassay Method; and the measurement of calcium and sodium ions was made with the Spectrophotometric Method.

RESULTS

Ultrasound Imaging. In ultrasound examination of the Siberian sturgeon, it was determined that there were 7 females and 8 males; while it was determined that there were 7 females and 7 males in the diamond sturgeon, and there was 1 individual that

had not completed its gonadal maturity. The gonad stages are given in Table 1.

TABLE 1
Identification of the stages maturity of female and male Siberian and diamond sturgeon

Maturity Stages	Siberian sturgeon		Diamond sturgeon	
	Female	Male	Female	Male
1	1	3	1	-
2	6	4	5	3
3	-	1	1	4
4	-	-	-	-

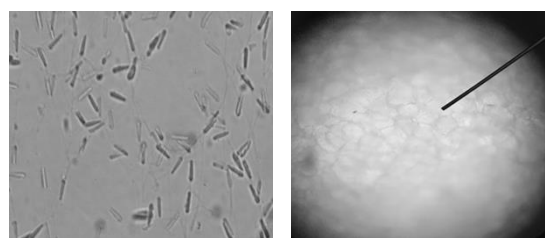


FIGURE 3
Microscopic spermatozoa and oocyte cell images

The testes in male individuals were observed to be extremely small and in the lateral part in the 1st stage. The fat tissue was observed to be in dark-grey (hypoechogenic) color. In the 2nd stage, the dark fat tissue decreased, and the testicular tissue was homogeneous and bigger. In the 3rd stage, the testicular covered the body cavity and in light-grey color (hyperechogenic). In this stage, it was determined that the spermatozoa were mature (Figure 1). In Siberian sturgeon, only one individual, which was defined as being at the end of 3rd stage, was examined in a histopathologic way. The spermatozoa in the milt that was sampled with the Stripping Method were imaged under microscope (Figure 3).

In ultrasonographic examinations in the female individuals, any mature individual in gonadal terms wasn't detected. It was observed that the ovarium tissue was surrounded by a fat tissue in the females in the 1st stage. The ovarium was in heterogenous structure and in bright color. In the ovarium tissue in the 2nd stage, the fat tissue decreased, and the ovarium tissue covered the body cavity in a bright color. In the 3rd stage, the ovarium was observed in granular structure and in dark color. Small oocytes were observed (Figure 2). In pathological sampling of a female individual, small oocytes (1.1 mm in diameter) were imaged under microscope (Figure 3).

Blood Parameters. Hemogram. In the study, the monthly changes in leucocyte, erythrocyte, hemoglobin and hematocrit values were determined in

male and female Siberian and diamond (*A. gueldenstaedtii*) sturgeon species, and are given in Figure 4, Figure 5, Figure 6 and Figure 7.

The highest leucocyte value in both species was determined in the sampling of November. While the highest leucocyte amount of the female individuals in Siberian sturgeon was $58.6 \pm 12.2 \mu\text{l}$; the highest leucocyte amount of the male individuals was $57.3 \pm 10.4 \mu\text{l}$.

The lowest leucocyte value was detected in April-May. The lowest average value of the female individuals was $47.2 \pm 8.2 \mu\text{l}$; and $48.0 \pm 6.1 \mu\text{l}$ in males. The lowest leucocyte amount in diamond sturgeon was detected in March. The highest leucocyte amount was $54.9 \pm 7.2 \mu\text{l}$ in average in females; and $54.8 \pm 7.6 \mu\text{l}$ in males; and the lowest value was $46.5 \pm 6.9 \mu\text{l}$ in male and female individuals.

The highest erythrocyte values in Siberian and diamond sturgeons were detected in November. The highest average erythrocyte amount of female Siberian sturgeon was $1.13 \pm 0.3 \mu\text{l}$ in November; and the lowest amount was detected in May as $0.53 \pm 0.1 \mu\text{l}$. The highest value in male individuals was $1.08 \pm 0.2 \mu\text{l}$ in November; and the lowest value was detected in April with $0.57 \pm 0.1 \mu\text{l}$. The lowest erythrocyte value in diamond sturgeon was detected in February. The highest average value in female individuals was $0.84 \pm 0.2 \mu\text{l}$; and the lowest average value was $0.62 \pm 0.1 \mu\text{l}$; and the highest average value in males was $0.85 \pm 0.2 \mu\text{l}$; and the lowest value was $0.62 \pm 0.1 \mu\text{l}$.

The highest hemoglobin values were measured in November for both species. The lowest average values in Siberian sturgeon female and male individuals were detected in May. The highest and lowest average values for the female individuals were 17.15 g dl^{-1} and 10.14 g dl^{-1} , respectively; and the highest and lowest average values in males were 17.19 g dl^{-1} and 10.03 g dl^{-1} , respectively. The lowest hemoglobin values in diamond sturgeon were detected in March. The highest and lowest values in female individuals were 15.18 g dl^{-1} and 10.6 g dl^{-1} , respectively; and the highest and lowest values in male individuals were 15.22 g dl^{-1} and 10.5 g dl^{-1} , respectively.

The highest hematocrit rates in Siberian sturgeon individuals were detected in November; and the lowest values were detected in April. The highest average hematocrit rate of the female individuals was 25.12%; and the lowest rate was 12.03%; and in male individuals, the highest average was 25.67; and the lowest average was 12.48%. The highest hematocrit values in diamond sturgeon were detected in December; and the lowest values were detected in March. The highest average hematocrit rate of the female individuals was 18.29%; and the lowest was 12.46%; in male individuals, the highest average was 18.45%, and the lowest rate was 12.41%.

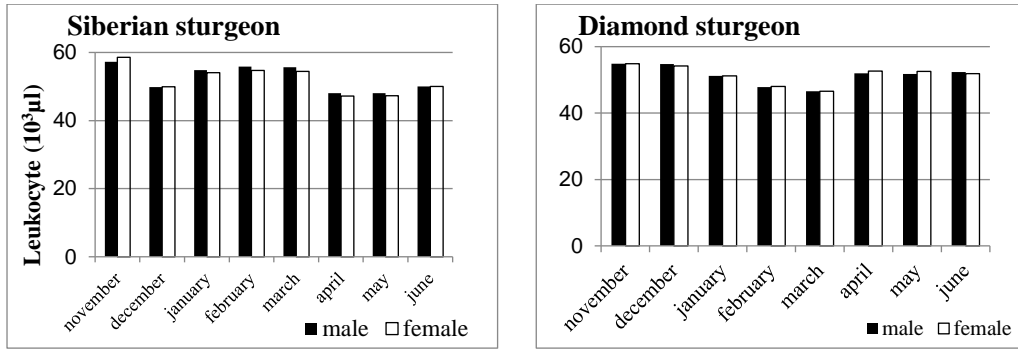


FIGURE 4
Change in the mean leukocyte concentrations in female and male sturgeon

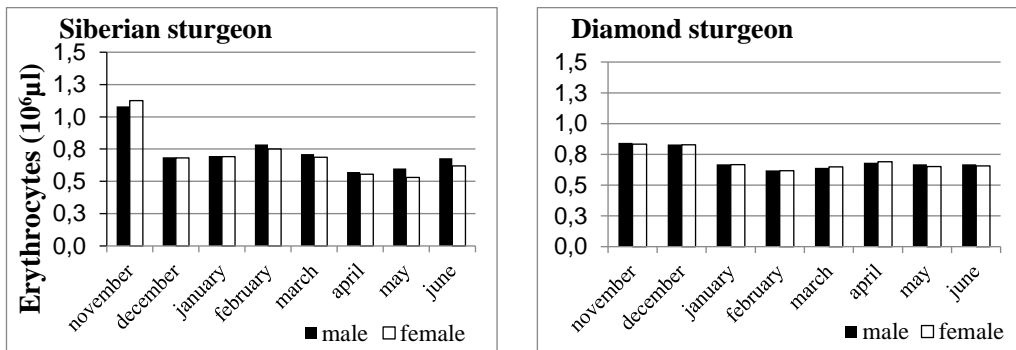


FIGURE 5
Change in the mean erythrocytes concentrations in female and male sturgeon

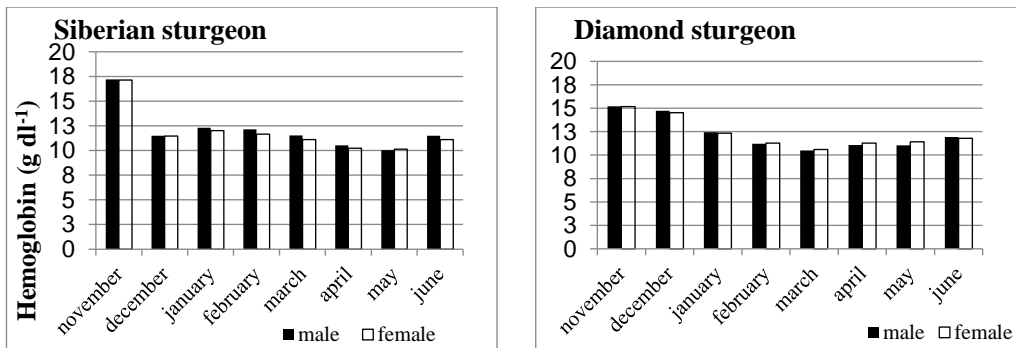


FIGURE 6
Change in the mean hemoglobin concentrations in female and male sturgeon

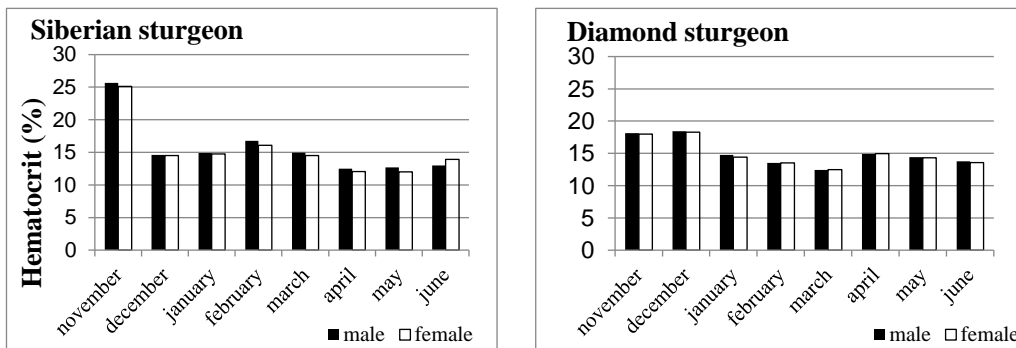


FIGURE 7
Change in the mean hematocrit concentrations in female and male sturgeon

The Analysis of the Steroid Hormones. The estradiol levels of female individuals in Siberian sturgeon were detected at the highest level in February with 199.1 pg ml⁻¹; and at the lowest level in October with 18.8 pg ml⁻¹. In male individuals, it was the highest in May with 49.0 pg ml⁻¹; and the lowest in November with 11.50 pg ml⁻¹ (Figure 8). The estradiol levels in female and male individuals of diamond sturgeon showed parallel changes (Figure 8). The highest estradiol level in female and male individuals was detected in March; and the lowest value was detected in October. While the highest average value in female individuals was 153.0 pg ml⁻¹; the lowest value was 29.7 pg ml⁻¹; in male individuals, it was 57.8 pg ml⁻¹ and 38.2 pg ml⁻¹, respectively.

The testosterone level in female and male individuals in Siberian sturgeon was at the highest level in June (Figure 9). While the testosterone level in male individuals was maximum with 670.0 ng dl⁻¹, the minimum value was detected in March with 398.8 ng dl⁻¹. The testosterone level in female individuals was maximum with 355.0 ng dl⁻¹ and minimum in April with 181.68 ng dl⁻¹.

In diamond sturgeon, the testosterone levels of the male individuals were maximum in October with 753.7 ng dl⁻¹; and minimum in April with 351.8 ng dl⁻¹. In female individuals, the testosterone level was maximum in January with 636.3 ng dl⁻¹, and minimum in June with 230.8 ng dl⁻¹ (Figure 9).

In Siberian sturgeon, the progesterone levels in female and male individuals did not differ along the study, and stayed stable at 0.1 ng ml⁻¹. No important changes were observed in the progesterone levels of the diamond (*A. gueldenstaedtii*) sturgeon, which was also the case in Siberian sturgeon. The highest progesterone level in female and male individuals was in October, and the lowest value was detected in April. The highest and lowest values in males and females were 0.21-0.11 ng ml⁻¹, and 0.22-0.11 ng ml⁻¹, respectively.

The Analysis of Sodium (Na⁺) and Calcium (Ca⁺⁺) Ions in Blood Plasma. The calcium ion amount in Siberian sturgeon was maximum in male individuals in November, and minimum in April; and in females, maximum in December, minimum in May. In male individuals, the maximum and minimum values were measured as 19.63-9.85 mg dl⁻¹; and in females, as 16.95-11.21 mg dl⁻¹ (Figure 11).

In diamond sturgeon, the maximum calcium ion levels of female and male individuals were detected in March, and minimum values were detected in October, the maximum and minimum values in female individuals were 8.45-6.76 mg dl⁻¹, respectively; and in male individuals, 8.45-6.60 mg dl⁻¹, respectively (Figure 11).

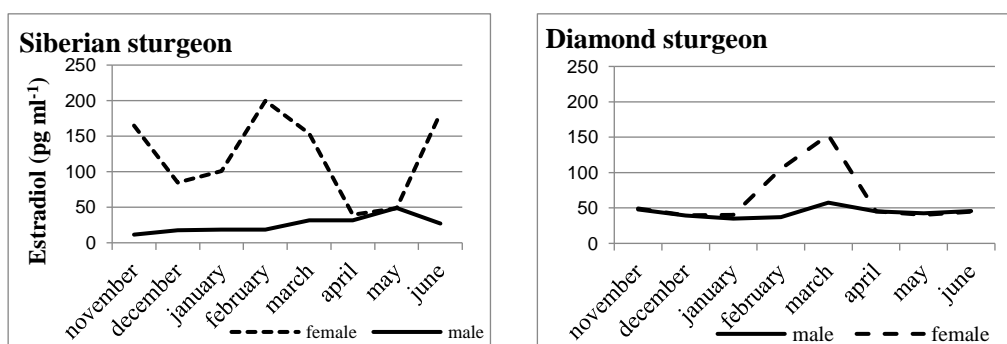


FIGURE 8
Change in the mean plasma E2 concentrations in female and male sturgeon

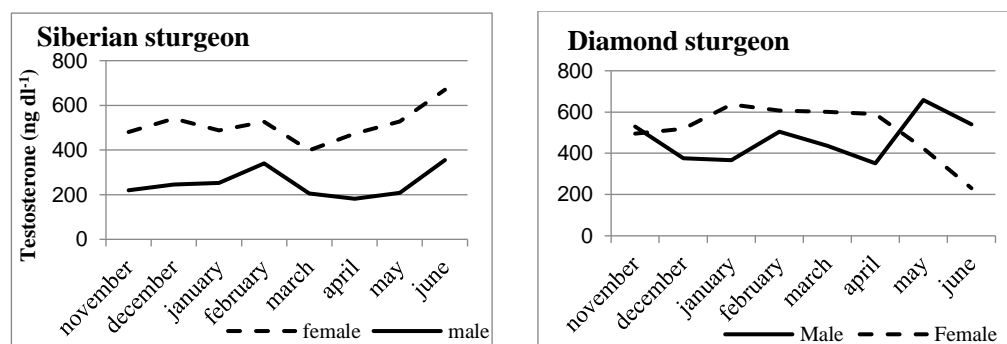


FIGURE 9
Change in the mean plasma T concentrations in female and male sturgeon

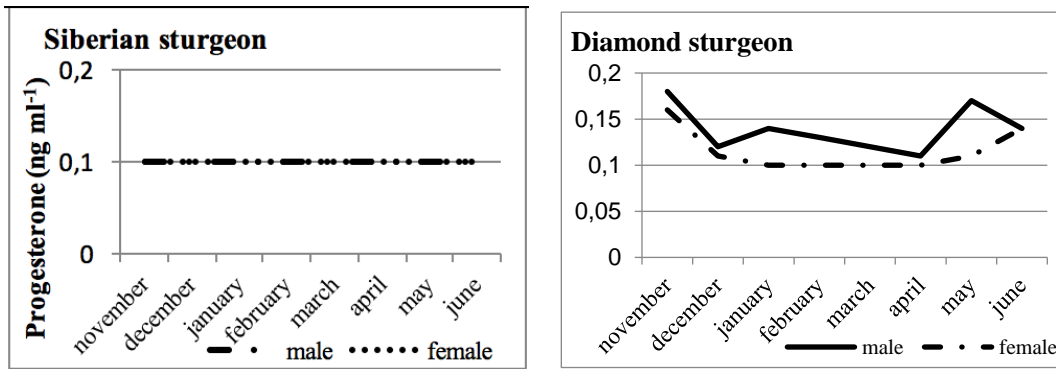


FIGURE 10
Change in the mean plasma P concentrations in female and male sturgeon

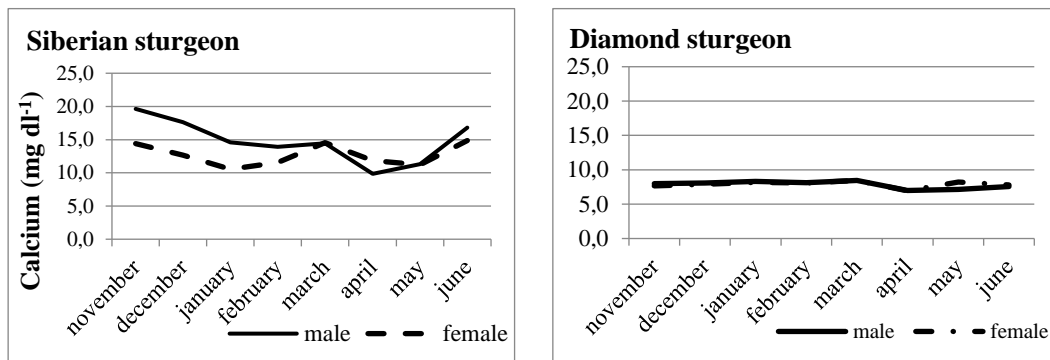


FIGURE 11
Change in the mean plasma calcium concentrations in female and male sturgeon

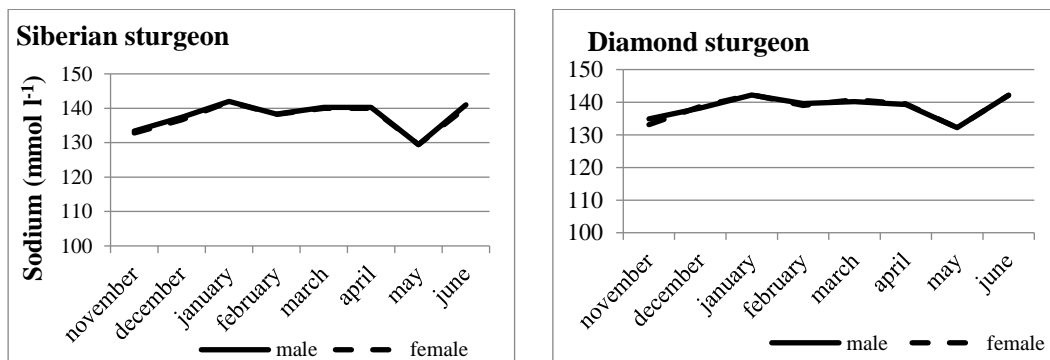


FIGURE 12
Change in the mean plasma sodium concentrations in female and male sturgeon

The sodium ion levels of female and male individuals in both species were detected to progress in similar rates. The highest sodium ion level was detected in January, and the lowest value was detected in October. In Siberian sturgeon individuals, while the maximum value for both genders was 141.86 mmol l⁻¹, the minimum value in male individuals was 118.5 mmol l⁻¹, and 120.0 mmol l⁻¹ in females. In diamond sturgeon, the maximum value in females and males was 142.3 mmol l⁻¹, and the minimum values in male individuals were 133.0 mmol l⁻¹, and 120.7 mmol l⁻¹ in females (Figure 12).

DISCUSSION AND CONCLUSIONS

In broodstock sturgeon species, the blood parameters and ultrasound examination may be used as a successful method in the following gamete development period by keeping the stress at minimum level and without causing any losses in fish. Several parameters like sizes of the ovarium and testis, the egg diameter and the gonadal development can be measured with ultrasound imaging method. At the same time some data related with reproductive performance like fecundity and gonadosomatic index

may be achieved with ultrasonographic imaging. [11, 12]. Many researchers recommend the determination of gender with ultrasonography since it causes less stress than the other methods and is a practical method [13, 14]. In this study, 30 broodstock candidate individuals were selected from among 1250 Siberian and diamond sturgeon species aged 4⁺; and the female and male individuals were determined by using the ultrasound technique. No statistically significant differences were observed during the study course in average steroid hormones, blood parameters and sodium and calcium ion values of the female and male individuals ($p > 0,05$). The gender of the species was determined by using the morphology and echogenicity (the brightness of the tissues) of the ovarium and testis tissues. The ultrasonographic imaging applications were carried out without anesthetizing. There were no deaths during the treatments.

Gender differentiation in sturgeon species is being completed up to age of 1-2 at the latest [15, 16]. However, it has been reported that the gender determination before 3 years of age is not reliable in these species. In fish raised under culture conditions, the vitellogenesis may last until the end of 3-4 years of age [15]. It must be considered that a great variation may be observed in the fish at the same age [17, 16].

The steroid hormones play important roles for hormonal control of the reproduction functions. It has been reported that the estradiol (E_2), 11-ketotestosterone (11-KT), VTG value, E_2 /VTG and E_2 /11KT rates may be used in determining the gender of the fish in a successful way [18, 19]. In this study, the levels of estradiol, testosterone and progesterone hormones, which are among the reproduction hormones, in and out of the reproduction season were examined in blood plasma. The estradiol level in female Siberian sturgeon individuals were measured higher than that of the male individuals. The highest estradiol level in female individuals was detected in February, and the lowest value was in October. The estradiol levels measured in April-May, which are the natural reproduction seasons of female individuals, progressed at lower levels when compared with the other months. The testosterone levels in male individuals were measured at higher levels than the female individuals during the study period. While the testosterone levels of the Siberian individuals were at high levels all during the study period, a measurable decreasing was observed in the testosterone levels in female and male individuals after March, which is reproduction season. The measured estradiol levels in male and female diamond sturgeon were similar along the study period. Although the estradiol levels of the male individuals were similar with female individuals, the estradiol levels of the female individuals were measured as relatively higher than the male individuals, just before the reproduction season in January-March. The female individuals' estradiol values rapidly decreased, and

reached to similar values as male individuals in April, which is the natural reproduction season. The testosterone levels of female individuals cruised at higher levels than the male individuals all along the study. However, in April, the beginning of the reproduction season, the testosterone levels decreased in female individuals and increased in male individuals. It was also determined that there were no significant differences in females and males in terms of progesterone levels.

The changes in blood plasma, sodium and calcium ion measurements are being used efficiently in determining the maturity status. During the maturation of gonad in female *Acipenser transmontanus*, the plasma VTG and calcium concentrations increase with the onset of yolk deposition. It was reported that the calcium ion amount in the blood plasma in females that are not mature was $96 \mu\text{g ml}^{-1}$, and as $175 \mu\text{g ml}^{-1}$ in mature individuals [20]. Marco et al. (2010), measured the reference value of the sodium ion in blood plasma of *A. naccari* x *A. baerii* hybrid sturgeon individuals as $140 \mu\text{g ml}^{-1}$ in average [21]. This value is similar with our obtained average values for both for *A. baerii* and for *A. guldensatedtii*. However, the late May values, which is the end of the reproduction season for Siberian sturgeon individuals, were lower when compared with these values.

Determining the changes in blood parameters, which are changing according to environmental and biological factors, is important to reveal the stress, comfort and the physiological status of the fish. However, the data on the reference values of many species are extremely limited in the literature [13]. The data obtained in this study have revealed the change in steroid hormone levels, the changes in some blood parameters, and the changes in the sodium and calcium amounts for of the individuals both species in and out of the reproduction season.

According to the hemogram data and observed individuals gonadal development findings, the fluctuations of the hematocrit, erythrocyte, leucocyte, hemoglobin values overlapped with the possible gamete production period of the broodstock candidates. In this context, the hemogram values of the Siberian sturgeon were determined at the peak level in January-February. On the other hand, diamond sturgeon's blood parameters referred May-June duration as potential reproduction season. In the light of these findings, sperm intake from male fishes was achieved in both Siberia and diamond back fishes at the age of 4⁺. It was observed that the spermatozoa were motile in the examinations made on the sperm samples. Owing to the fact that mature eggs couldn't be obtained from 4⁺ year old female individuals, advanced applications related to production hadn't been realized during the study. Potential gamete maturation period can be determined following the blood parameters of the newly grown sturgeon. Thus, production planning and economic planning

process can be managed correctly when considering that the reproduction process of sturgeon fish has taken many years.

ACKNOWLEDGEMENTS

We offer our gratitude to Recep Tayyip Erdogan University BAP Coordinatorship (project number: 2015.53007.103.02.05) and Fisheries Research & Application Center Directorate, because of study finance and live material supply.

REFERENCES

- [1] Dettlaff, T.A., Ginsburg, A.S. and Schmalhausen, O.I. (1993) Sturgeon fishes, Developmental Biology and Aquaculture. Springer Verlag, Berlin Heidelberg, 300.
- [2] Moghim, M.A., Vajhi, R., Veshkini, A. and Masoudifard, M. (2002) Determination of sex and maturity in *Acipenser stellatus* by using ultrasonography. *J. Appl. Ichthyol.*, 18:325-328.
- [3] Webb, M.A.H., Feist, G.W., Foster, E.P., Schreck, C.B. and Fitzpatrick, M.S. (2002) Potential classification of sex and stage of gonadal maturity of wild white sturgeon using blood plasma indicators. *Trans. Amer. Fish. Soc.* 131:132-142.
- [4] Colombo, R.E., Wills, P.S. and Garvey, J.E. (2004) Use of ultrasound imaging to determine sex of shovelnose sturgeon. *Journal of Fisheries Management*, 24:322-326.
- [5] Wildhaber, M.L., Papoulias D.M., DeLonay A.J., Tillitt, D.E., Bryan, J.L. and Annis, M.L. (2007) Physical and hormonal examination of missouri river shovelnose sturgeon reproductive stage: a reference guide. *J. Appl. Ichthyol.*, 23:382-401.
- [6] Chebanov, M. S. and Galich, E.V. (2009) Ultrasound diagnostics for sturgeons broodstock management, p. 115. Krasnodar, Russia: Education-South.
- [7] Craig, J.M., Papoulias, D.M., Thomas, M.V., Annis, M.L. and Boase, J.C. (2009) Sex assignment of Lake Sturgeon (*Acipenser fulvescens*) based on plasma sex hormone and vitellogenin levels. *Journal of Applied Ichthyology*, 25(Supplement 2):60–67.
- [8] Petochi, T., Di Marco, P., Donadelli, V., Longobardi, A., Corsalini, I., Bertotto, D., Finoia, M.G. and Marino, G. (2011) Sex and reproductive stage identification of sturgeon hybrids (*Acipenser naccarii* × *Acipenser baerii*) using different tools: ultrasounds, histology and sex steroids. *J. Appl. Ichthyol.*, 27:637-642.
- [9] Bruch, R.M., Dick, T.A. and Choudhury, A. (2001) A field guide for the identification of stages of gonad development in Lake Sturgeon, *Acipenser fulvescens* Rafinesque, with notes on Lake Sturgeon reproductive biology and management implications. Wisconsin Department of Natural Resources, Oshkosh, and Sturgeon for Tomorrow, Appleton, Wisconsin.
- [10] Chiotti, J.A., Boase, J.C., Hondorp, D.W. and Briggs A.S. (2016) Assigning sex and reproductive stage to adult Lake sturgeon using ultrasonography and common morphological measurements. *North American Journal of Fisheries Management* 36:21–29.
- [11] Albers, J.L., Wildhaber, M.L. and DeLonay, A.J. (2013) Gonadosomatic index and fecundity of Lower Missouri and Middle Mississippi River endangered pallid sturgeon estimated using minimally invasive techniques. *J. Appl. Ichthyol.*, 29:968-977.
- [12] Bryan, J.L., Wildhaber, M.L., Papoulias, D.M., DeLonay, A.J., Tillitt, D.E. and Annis, M.L. (2007) Estimation of gonad volume, fecundity, and reproductive stage of shovelnose sturgeon using sonography and endoscopy with application to the endangered pallid sturgeon. *J. Appl. Ichthyol.*, 23:411-419.
- [13] Du, H., Zhang, X., Leng, X., Zhang, S., Luo, J., Liu, Z., Qiao, X., Kynard, B. and Wei, Q. (2016) Gender and gonadal maturity stage identification of captive Chinese sturgeon, *Acipenser sinensis*, using ultrasound imagery and sex steroids. *General and Comparative Endocrinology*,
- [14] Memiş, D., Yamaner, G., Tosun, D.D., Eryalçın, K.M., Chebanov, M. and Galich, E. (2016) Determination of sex and gonad maturity in sturgeon (*Acipenser gueldenstaedtii*) using ultrasound technique. *Journal of Applied Aquaculture*, 28:252-259.
- [15] Doroshov, S.I., Moberg, G.P. and Van Eenennaam, J.P. (1997) Observations on the reproductive cycle of cultured white sturgeon, *Acipenser transmontanus*. *Environmental Biology of Fishes*, 48:265–278.
- [16] Hurvitz, A., Jackson, K., Degani, G., and Levavi-Sivan B. (2007) Use of Endoscopy for gender and ovarian stage determinations in Russian Sturgeon (*Acipenser gueldenstaedtii*) grown in aquaculture. *Aquaculture*, 270:158–166.
- [17] Amiri, B.M., Maebayashi, M. Hara, A. Adachi, S. and Yamauchi K. (1996) Ovarian development and serum sex steroid and vitellogenin profiles in the female cultured sturgeon hybrid, the bester. *Journal of Fish Biology*, 8:1164–1178.
- [18] Cuisset, B.D., Rouault, T. and Williot, P. (2011) Estradiol, testosterone, 11-ketotestosterone, 17, 20 beta-dihydroxy-4-pregnen-3-one and vitellogenin plasma levels in females of captive European sturgeon, *Acipenser sturio*. *J. Appl. Ichthyol.* 27:666-672.



- [19] Mola, A.E. and Hovannisyan, H.G. (2015) Measurements of serum steroid hormones (testosterone, 11-ketotestosterone, and 17 β -estradiol) in farmed great sturgeon. *Comparative Clinical Pathology*, 24:509-513.
- [20] Casenave J.L., Kroll, K.J., Van-Eennaam, J.P. and Doroshov, S.I. (2003) Effect of ovarian stage on plasma vitellogenin and calcium in cultured white sturgeon. *Aquaculture*, 221:645-656.
- [21] Marco, P.D., Priori, A., Finioia, M.G., Longobardis, A., Donadelli, A. and Marino G. (2010) Assessment of blood chemistry reference values for cultured sturgeon hybrids (*Acipenser naccarii* female \times *Acipenser baerii* male). *J. Appl. Ichthyol.*, 27:584-590.

Received: 31.05.2017

Accepted: 29.07.2017

CORRESPONDING AUTHOR

Kubra Ak

Recep Tayyip Erdogan University,
Faculty of Fisheries Sciences,
Department of Aquaculture,
53100, Rize – TURKEY

E-mail: kubra.ak@erdogan.edu.tr