

Split Rib Cranioplasty for Frontal Osteoma: A Case Report and Review of the Literature

Vaner Koksak,^{1,*} Selim Kayaci,¹ and Recep Bedir²

¹Department of Neurosurgery, Medical School, Recep Tayyip Erdogan University, Rize, Turkey

²Department of Pathology, Medical School, Recep Tayyip Erdogan University, Rize, Turkey

*Corresponding author: Vaner Koksak, Department of Neurosurgery, Medical School, Recep Tayyip Erdogan University, Rize, Turkey. Tel: +90-5055212361, Fax: +90-4642123015, E-mail: vanerkoksak@hotmail.com

Received 2015 April 29; Revised 2015 June 02; Accepted 2015 July 11.

Abstract

Introduction: Osteomas are benign bone tumors. They generally lead to a local thickness on the frontal bone in calvarium. When they occur on the forehead, they often cause a cosmetic disorder without any neurological symptoms. The significant problem is the repair method of the cranium defect.

Case Presentation: The rib of a 34-year-old female was split and used for a small cranium defect of 3 × 3.5 cm. The preferred method and the obtained results were presented under the guidance of the literature.

Conclusions: Along with the technological advancement, different materials are employed according to the size of the cranium defect and the age of the case. The application of split costa cranioplasty for the small cranium defects in the region of patient's face is the method with the least possibility of complications, and its cosmetic and functional results are quite promising.

Keywords: Autografts, Cranial Vault, Cranioplasty, Osteoma, Rib, Defect

1. Introduction

Osteomas are benign, slow-growing and generally asymptomatic bone tumors. They are observed at varying rates 0.0.1% 3% within the whole population and are mostly observed in the third-fourth decades (1, 2). It is reported that osteoma could develop from the outer tabula of the calvarium at a rate of 69% and from within the paranasal sinuses at 23% (2). Of the paranasal sinuses, they often form within the frontal ones (1, 2). A surgical resection is performed on the ones becoming symptomatic due to closure of the paranasal sinus lumen or the ones that cosmetically affect the appearance (2, 3). It is important to select the right material to repair the postoperative defects on young persons' foreheads. Although the case was a frequently-encountered pathology, it was presented under the guidance of the literature.

2. Case Presentation

A 34-year-old female patient referred to the Recep Tayyip Erdogan University Neurosurgery clinic with the complaint of a swelling that cosmetically distorted her facial appearance by growing on the right corner of her forehead in two years. A hard, motionless and tumorous lesion with a diameter of 3 × 3.5 cm and almost 1 cm depth was determined during her physical examination. There was no

neurological findings over the mass. Radiologically, the lesion was found to be adjacent to the right frontal sinus and had a hypodense appearance in its direct X-ray (Figure 1A, C).

In the computerized tomography (CT) scan images, it was determined that it did not harm the dura but eroded the inner tabula slightly (Figure 1B). Only due to the cosmetic discomfort and upon the patient's request, it was decided to perform a surgical operation. The defect that occurred after the complete resection of the mass along with the calvarium was repaired by the rib (costa) of the patient herself. (Figure 1D and Figure 2A - C). The pathology of the resected tissue was evaluated as a typical osteoma (Figure 3).

2.1. Surgical Technique

The lesion was 4 cm to the right side of the midline on the edge of the forehead and 3 cm below the scalp. A narrow pterional skin incision on the scalp was performed. When the skin flap was turned over, the tumor was approached. The lesion macroscopically appeared in the form of a porous bone and was well-demarcated. A burr hole was opened just by the side of the lesion via a high-speed touring device of Midas-Rex. Craniotomy was performed by incising its extremity from a 2 - 3 mm distance from the strong boundary of the bone. The dura was strong and the tumor did not proceed beyond the inner tabula.

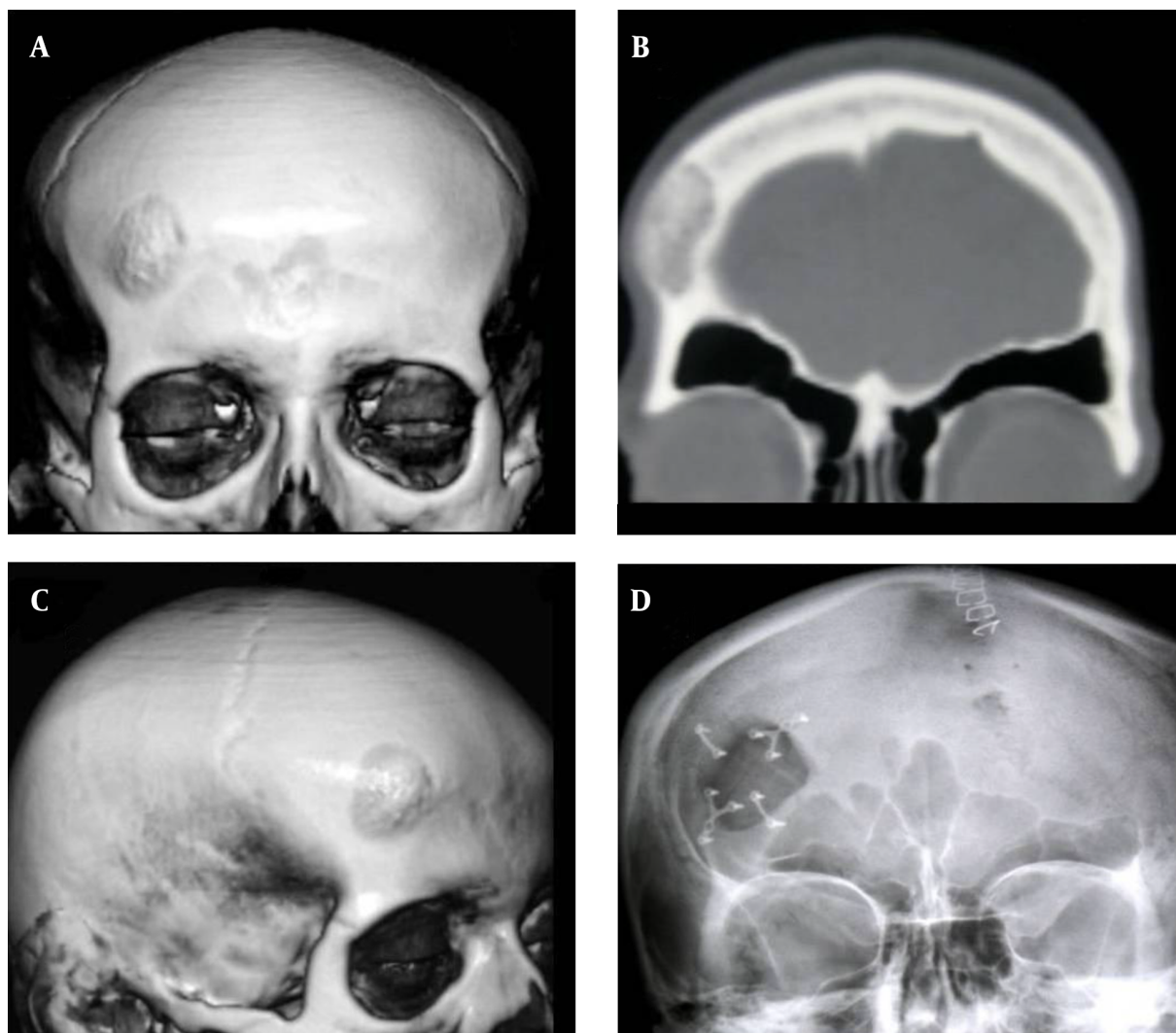


Figure 1. A, C, the Preoperative X-ray Image of the Case; B, in the CT of the coronal brain, an osteoma is observed on the edge of the right frontal sinus; D, the images of post-operative direct radio-image.

The tumor along with craniotomy was totally resected. At the end of the intervention, a defect of approximately $3.2 \times 3.7 \text{ cm} = 11.84 \text{ cm}^2$ occurred in the cranium. About 4 - 5 cm of the 8th costa from the thorax right side wall was resected with the help of the physician from the Department of Thoracic Surgery. The rib was transversally split into two equal pieces by preserving its length on the horizontal axis. The two pieces were attached via titanium miniplaques in a way that the trabecular bone surface would overlook the dura and the cortical surfaces would overlook outside. The final shape was given to the graft considering the defect in question. The sides of the graft were fixed by four pieces of mini plaques in a way that they would thoroughly con-

tact the sides of the defect. Following the operation, it was observed that the shape of the case's forehead formed its natural form. At the end of the one-year-follow-up, in the bone window images of the brain CT, it was observed that a complete fusion had occurred on the sides of the defect (Figure 2D). At the end of the patient's three-year-follow-up she had no more complaints about the disorder; the integrity of the cranium was maintained through the physical and radiological examinations performed and no cosmetic problem was encountered. No infection, disruption or resorption occurred over the costa graft used.

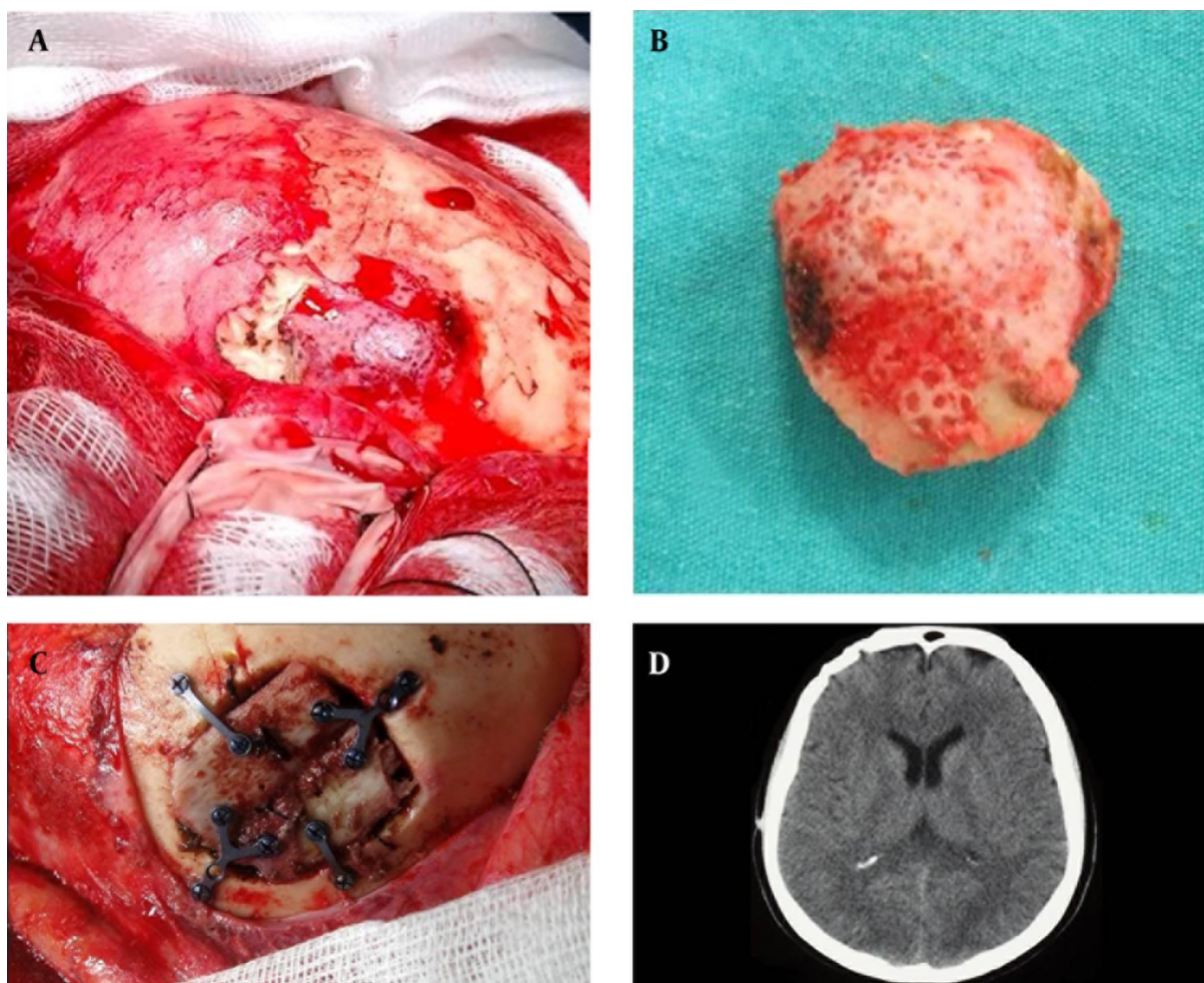


Figure 2. A, the image of the mass over the frontal bone; B, the image of the lesion after craniotomy, C, after the split costa had been applied on the defect to cover it by means of mini plaques, D, the CT image of the cerebrum showing that the defect in the cranium had fully fused with the costa at the end of the first year of the case.

3. Discussion

Cranioplasty is the repair procedure performed to maintain the function and the structural support of the lost cranium bone. In order to close the cranium defect, a number of different natural or synthetic materials are tried (4, 5). At the end of this process, descriptions of the ideal material showed up. The right cranium repair material should be resistant to infection, aesthetically suitable, durable and protective, easy-to-shape as desired, should not expand due to the effect of the heat, should not conduct the heat to the brain, should not biologically break down, and should be sterile and ready to use, with the least possibility to cause a tissue rejection and allergic reaction (4-6).

Besides the fact that the defects occurring in the cra-

nium frequently appear in the current of traumas, they may also occur after the resection of the bone-based tumors as observed in the current case. No matter how they occur, the size of the cranium defect is the main determinant in the selection of the appropriate material (7). However, in the literature, no classification could be found to select suitable repair tool considering the sizes of the cranium defects. Yet, according to the current case literature review, the defects, the areas larger than 25 cm² are classified as large defects; whereas the ones with the areas between 12-25 cm² are classified as medium-sized defects and areas smaller than 12 cm² (and according to some sources those with areas smaller than 9 cm²) can be classified as small cranium defects (7, 8). With the technological advancements, it is recommended to use metal grafts such as titanium and the materials of plastic origin comprised of

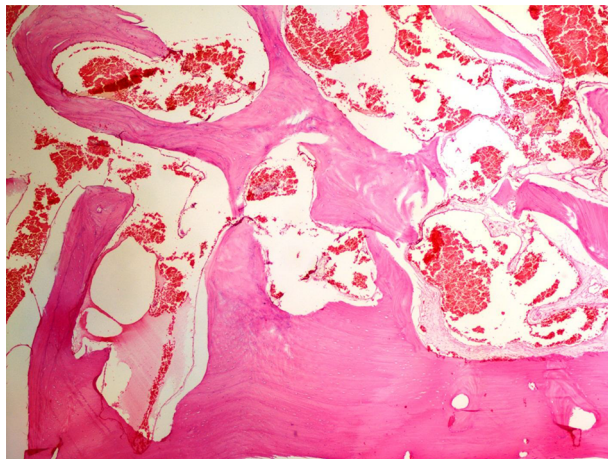


Figure 3. The monitored Tumoral Tissue Comprised of Mature Bone Trabeculae (H&E, $\times 40$)

the combination of polymethylmethacrylate and hydroxyapatite for cranioplasty in cases that the defect size is so large that it is almost impossible to close it through autograft (9).

In particular, the most frequently used substance, methyl methacrylate (acrylic) has superior qualities. The most important of all is that any shape could be given by hand before the defects get hardened. Although it seems to be the proper material with this characteristic, it is known that it can never get fused with the bones. Separately, due to the fact that it is a foreign object, they have to be disposed in case of contamination by the infectious agents. The use of titanium has increased in recent years (8).

However, since the cost of such materials specifically prepared for the defect is rather high, their application in the developing countries are restricted. There may be relaxation in the process of time as observed in other metal medical materials. It is emphasized that autografts could be insufficient to cover the large defects or that it could be difficult to give the appropriate shape in terms of aesthetics (7). For this reason, it is reported that it would be healthier to try autografts on small and medium-sized defects (6, 7). However, there are reports indicating successful results when split ribs were used in very large and even expanding cranium defects that occurred in the patients with aplasia cutis (10). Since a post-repair fusion is targeted in the case of a small cranium defect in young adults and adolescents, the application of autograft is still the most appropriate method (5). So far, tibia, outer tabula of the cranium, scapula, iliac crest, sternum and the bone pieces incised from the ribs are used in cranioplasty (5). According to the current study, the split costa cranioplasty se-

lected by the authors has a number of advantages. Since the costa belonged to the patient's own body, no reaction of a foreign matter was seen. Due to the low rates of infection, it is also preferred for revision in the cases that infection occurs through the synthetic grafts (11). It is reported that the donor costa was fully regenerated and easily adapted to the sides/edges of the defect, allowing the fusion to form well. In particular, allowing for the release of the osteoblasts that will maintain the bone fusion with the costa splitting in two increases the efficiency of the process more and more (11). It is known that covering the expandable defects through the use of costa in the cases such as adolescents is a more successful method (12). Besides, it can be obtained more easily than the outer tabula of calvarium which is one of the other autografts (12). In fact, the only potential disadvantage of the costa cranioplasty is the prolongation of the surgical process rather than the concern about its effects on the lungs (13, 14). On the other hand, the desired cosmetic slope may not be provided in rather large defects. Since the convexity of the cranium in a defect smaller than 12 cm^2 is not visible, it was observed to have covered the region smoothly. The case had no additional problem that affected the lungs.

The ribs were first used in cranioplasty by Dobrotowski in 1911 (5). Longacre and Destefano, for the first time, used the costa that is popular today by splitting it into two (5). Despite the fact that it dates back to a long time ago, there are few studies regarding the subject in the medical literature. In the research on the use of split costa to perform cranioplasty, only 17 publications were found in PubMed. Yet, the plastic surgeons preferred split costa more than any other method in the face construction procedures. In these studies, the magnitudes of the defects on which costas were applied and their localizations are given in Table 1. The data in Table 1 indicated that split costas were preferred more by plastic surgeons, since they were used on the frontal region; however, their application decreased in recent years and their complications gradually diminished throughout the chronological process.

In the presented case, osteomas with a diameter of more than 3 cm or weighing more than 110 g are considered "giant" or "large" osteomas (27). Thus, there is a big defect after the removal of large osteomas and it is not possible to close them properly by costa. In such cases, methyl-methacrylate or other synthetic materials may be preferred for good cosmetic appearance (27). Also, "Why the foreign materials were used for the fixation?" is an important question. The free edge of calvarial bones have to be kept motionless to contact for the fusion of bone tissue. Different materials are used to prevent movement on calvarium. For many years, non-absorbable sutures were used for this purpose. But, the actual-preferred is rigid fix-

Table 1. The Outcomes of Split Rib Cranioplasty in the Literature^a

| Study | Number of Patients | Site | Defect Size | Complication(s) | Result |
|----------------------------------|--------------------|------------------------|---------------------|-----------------------------|-------------------------------|
| Leivy and Tovi (15) 1970 | 7 | Frontal | | 1 infection, 1 pneumothorax | Not bad |
| Körlof et al. (16) 1973 | 23, 11, 12 | Frontal parietal other | | 3 hematoma, 1 hemothorax | %50 good, %25 slightly uneven |
| Shaw and Thering (17) 1975 | 7 | Cranium | | None | Good |
| Munro and Guyuron (18) 1981 | 12 | Frontal | | 1 pneumothorax | Not bad |
| Cabbabe et al. (19) 1984 | 8 | Frontal | | 1 infection | Good |
| Forte and de Souza (20) 1985 | 1 | Frontal | | None | Good |
| Edwards and Ousterhout (21) 1987 | 2 | Frontal | | None | Good |
| Guyuron et al. (12) 1988 | 29 | Cranium | Extensive and large | Minor complication | Good |
| Kawakami et al. (22) 1989 | 6 | Cranium | Medium, large | 1 hemothorax | Good |
| Stal et al. (23) 1992 | 2 | Frontal | | 1 resorption | Not bad |
| Viterbo et al. (24) 1995 | 2 | Frontal | Small, large | None | Good |
| Taggard and Menezes (25) 2001 | 8 | Frontal | | None | 1 revision |
| Yano et al. (11) 2006 | 1 | Frontal | Large | None | Good |
| Beekmans et al. (10) 2007 | 3 | Parietal | Large | None | Good |
| Soyka et al. (13) 2011 | 2 | frontal sinus | Middle, large | None | Good |
| Bharti et al. (26) 2011 | 1 | Parietal | Large | None | Good |
| The current case 2014 | 1 | Frontal | Small | None | Good |
| The total number of cases | | | 138 | | |

^aThe results were evaluated based on the articles both on split rib graft fusion and cosmetic appearance.

ation. In recent years, mini plates and screws are used for this purpose. Also, absorbable plates and screws are developed. But, authors did not use absorbable material, which is not provide by general health insurance in the country.

3.1. Conclusion

The application of split costa cranioplasty for the small cranium defects formed in the region of patient's face is the method with the least possibility of complications, and the cosmetic and functional results of it are quite promising.

Acknowledgments

Thank you for their contribution to consent of the Recep Tayyip Erdogan University Training and Research Hospital.

Footnote

Authors' Contribution: Vaner Koksal, conceptualised the study, designed the study protocol, collected and anal-

ysed the data, prepared the manuscript, and takes overall responsibility for the paper; Selim Kayaci, participated in the analysis and interpretation of data, drafting of the manuscript; Recep Bedir, prepared the pathology review and picture.

References

- Cheng KJ, Wang SQ, Lin L. Giant osteomas of the ethmoid and frontal sinuses: Clinical characteristics and review of the literature. *Oncol Lett.* 2013;5(5):1724-30. doi: [10.3892/ol.2013.1239](https://doi.org/10.3892/ol.2013.1239). [PubMed: 23759920].
- Janovic A, Antic S, Rakocevic Z, Djuric M. Paranasal sinus osteoma: is there any association with anatomical variations?. *Rhinology.* 2013;51(1):54-60. doi: [10.4193/Rhinol2.130](https://doi.org/10.4193/Rhinol2.130). [PubMed: 23441312].
- Rokade A, Sama A. Update on management of frontal sinus osteomas. *Curr Opin Otolaryngol Head Neck Surg.* 2012;20(1):40-4. doi: [10.1097/MOO.0b013e32834e9037](https://doi.org/10.1097/MOO.0b013e32834e9037). [PubMed: 22249167].
- Klinger DR, Madden C, Beshay J, White J, Gambrell K, Rickert K. Autologous and acrylic cranioplasty: a review of 10 years and 258 cases. *World Neurosurg.* 2014;82(3-4):e525-30. doi: [10.1016/j.wneu.2013.08.005](https://doi.org/10.1016/j.wneu.2013.08.005). [PubMed: 24036124].

5. Shah AM, Jung H, Skirboll S. Materials used in cranioplasty: a history and analysis. *Neurosurg Focus*. 2014;**36**(4):E19. doi: [10.3171/2014.2.FOCUS13561](https://doi.org/10.3171/2014.2.FOCUS13561). [PubMed: [24684331](https://pubmed.ncbi.nlm.nih.gov/24684331/)].
6. Vercler CJ, Sugg KB, Buchman SR. Split cranial bone grafting in children younger than 3 years old: debunking a surgical myth. *Plast Reconstr Surg*. 2014;**133**(6):822e-7e. doi: [10.1097/PRS.0000000000000222](https://doi.org/10.1097/PRS.0000000000000222). [PubMed: [24867741](https://pubmed.ncbi.nlm.nih.gov/24867741/)].
7. Goldstein JA, Paliga JT, Bartlett SP. Cranioplasty: indications and advances. *Curr Opin Otolaryngol Head Neck Surg*. 2013;**21**(4):400-9. doi: [10.1097/MOO.0b013e328363003e](https://doi.org/10.1097/MOO.0b013e328363003e). [PubMed: [23770828](https://pubmed.ncbi.nlm.nih.gov/23770828/)].
8. Zins JE, Langevin CJ, Nasir S. Controversies in skull reconstruction. *J Craniofac Surg*. 2010;**21**(6):1755-60. doi: [10.1097/SCS.0b013e3181c34675](https://doi.org/10.1097/SCS.0b013e3181c34675). [PubMed: [2119415](https://pubmed.ncbi.nlm.nih.gov/2119415/)].
9. Rotaru H, Baciut M, Stan H, Bran S, Chezan H, Iosif A, et al. Silicone rubber mould cast polyethylmethacrylate-hydroxyapatite plate used for repairing a large skull defect. *J Craniomaxillofac Surg*. 2006;**34**(4):242-6. doi: [10.1016/j.jcms.2006.01.005](https://doi.org/10.1016/j.jcms.2006.01.005). [PubMed: [16644233](https://pubmed.ncbi.nlm.nih.gov/16644233/)].
10. Beekmans SJ, Don Griot JP, Mulder JW. Split rib cranioplasty for aplasia cutis congenita and traumatic skull defects: more than 30 years of follow-up. *J Craniofac Surg*. 2007;**18**(3):594-7. doi: [10.1097/scs.0b013e3180576f44](https://doi.org/10.1097/scs.0b013e3180576f44). [PubMed: [17538324](https://pubmed.ncbi.nlm.nih.gov/17538324/)].
11. Yano H, Tanaka K, Matsuo T, Tsuda M, Akita S, Hirano A. Cranioplasty with auto-purified bone flap after infection. *J Craniofac Surg*. 2006;**17**(6):1076-9. doi: [10.1097/01.scs.0000244916.84511.b6](https://doi.org/10.1097/01.scs.0000244916.84511.b6). [PubMed: [17119408](https://pubmed.ncbi.nlm.nih.gov/17119408/)].
12. Guyuron B, Shafron M, Columbi B. Management of extensive and difficult cranial defects. *J Neurosurg*. 1988;**69**(2):210-2. doi: [10.3171/jns.1988.69.2.0210](https://doi.org/10.3171/jns.1988.69.2.0210). [PubMed: [3292718](https://pubmed.ncbi.nlm.nih.gov/3292718/)].
13. Soyka MB, Guggenheim M, Arnoux A, Holzmann D. Split-rib reconstruction of the frontal sinus: two cases and literature review. *J Laryngol Otol*. 2011;**125**(12):1301-8. doi: [10.1017/S0022215111002611](https://doi.org/10.1017/S0022215111002611). [PubMed: [22017793](https://pubmed.ncbi.nlm.nih.gov/22017793/)].
14. Longacre JJ, Destefano GA. Further observations of the behavior of autogenous split-rib grafts in reconstruction of extensive defects of the cranium and face. *Plast Reconstr Surg (1946)*. 1957;**20**(4):281-96. [PubMed: [13494206](https://pubmed.ncbi.nlm.nih.gov/13494206/)].
15. Leivy DM, Tovi D. Autogenous bone cranioplasty. *Neurochirurgia (Stuttg)*. 1970;**13**(3):82-6. doi: [10.1055/s-0028-1095261](https://doi.org/10.1055/s-0028-1095261). [PubMed: [5427054](https://pubmed.ncbi.nlm.nih.gov/5427054/)].
16. Korlof B, Nysten B, Rietz KA. Bone grafting of skull defects. A report on 55 cases. *Plast Reconstr Surg*. 1973;**52**(4):378-83. [PubMed: [4582525](https://pubmed.ncbi.nlm.nih.gov/4582525/)].
17. Shaw RC, Thering HR. Reconstruction of cranial defects. *Clin Plast Surg*. 1975;**2**(4):539-49. [PubMed: [1098835](https://pubmed.ncbi.nlm.nih.gov/1098835/)].
18. Munro IR, Guyuron B. Split-rib cranioplasty. *Ann Plast Surg*. 1981;**7**(5):341-6. [PubMed: [7332200](https://pubmed.ncbi.nlm.nih.gov/7332200/)].
19. Cabbabe EB, Shively RE, Malik P. Cranioplasty for traumatic deformities of the frontoorbital area. *Ann Plast Surg*. 1984;**13**(3):175-84. [PubMed: [6497265](https://pubmed.ncbi.nlm.nih.gov/6497265/)].
20. Forte V, de Souza FM. Autogenous rib grafts in facial surgery. *J Otolaryngol*. 1985;**14**(3):201-2. [PubMed: [4068120](https://pubmed.ncbi.nlm.nih.gov/4068120/)].
21. Edwards MS, Ousterhout DK. Autogenic skull bone grafts to reconstruct large or complex skull defects in children and adolescents. *Neurosurgery*. 1987;**20**(2):273-80. [PubMed: [3561736](https://pubmed.ncbi.nlm.nih.gov/3561736/)].
22. Kawakami K, Takahara N, Yamanouchi Y, Suwa J, Matsumura K, Ikeda Y, et al. [Split rib cranioplasty]. *No Shinkei Geka*. 1989;**17**(11):1023-7. [PubMed: [2594152](https://pubmed.ncbi.nlm.nih.gov/2594152/)].
23. Stal S, Netscher DT, Shenaq S, Spira M. Reconstruction of calvarial defects. *South Med J*. 1992;**85**(8):812-9. [PubMed: [1502623](https://pubmed.ncbi.nlm.nih.gov/1502623/)].
24. Viterbo F, Palhares A, Modenese E. Cranioplasty: the autograft option. *J Craniofac Surg*. 1995;**6**(1):80-3. [PubMed: [8601012](https://pubmed.ncbi.nlm.nih.gov/8601012/)].
25. Taggard DA, Menezes AH. Successful use of rib grafts for cranioplasty in children. *Pediatr Neurosurg*. 2001;**34**(3):149-55. [PubMed: [11359103](https://pubmed.ncbi.nlm.nih.gov/11359103/)].
26. Bharti G, Groves L, David LR, Sanger C, Argenta LC. Aplasia cutis congenita: clinical management of a rare congenital anomaly. *J Craniofac Surg*. 2011;**22**(1):159-65. doi: [10.1097/SCS.0b013e3181f73937](https://doi.org/10.1097/SCS.0b013e3181f73937). [PubMed: [21187755](https://pubmed.ncbi.nlm.nih.gov/21187755/)].
27. Izci Y. Management of the large cranial osteoma: experience with 13 adult patients. *Acta Neurochir (Wien)*. 2005;**147**(11):1151-5. doi: [10.1007/s00701-005-0605-4](https://doi.org/10.1007/s00701-005-0605-4). [PubMed: [16133777](https://pubmed.ncbi.nlm.nih.gov/16133777/)].