

# Syringaldehyde exerts neuroprotective effect on cerebral ischemia injury in rats through anti-oxidative and anti-apoptotic properties

Aras Adem Bozkurt<sup>1</sup>, Guven Mustafa<sup>1</sup>, Akman Tarik<sup>1</sup>, Ozkan Adile<sup>2</sup>, Sen Halil Murat<sup>2</sup>, Kilicoglu Mesut<sup>3</sup>, Kalkan Yildiray<sup>4</sup>, Silan Coskun<sup>5</sup>, Cosar Murat<sup>1</sup>

1 Department of Neurosurgery, Çanakkale Onsekiz Mart University, Canakkale, Turkey

2 Department of Neurology, Çanakkale Onsekiz Mart University, Canakkale, Turkey

3 Department of Medical Biochemistry, Ondokuz Mayıs University, Samsun, Turkey

4 Department of Histology and Embryology, Faculty of Medicine, Recep Tayyip Erdoğan University, Rize, Turkey

5 Department of Pharmacology, Çanakkale Onsekiz Mart University, Canakkale, Turkey

## Corresponding author:

Aras Adem Bozkurt, Department of Neurosurgery, Faculty of Medicine, Canakkale Onsekiz Mart University, Canakkale, Turkey, guven2340@hotmail.com.

doi:10.4103/1673-5374.145353

http://www.nrronline.org/

Accepted: 2014-09-06

## Abstract

There are few studies on the neuroprotective effects of syringaldehyde in a rat model of cerebral ischemia. The study aimed to elucidate the mechanisms underlying the neuroprotective effects of syringaldehyde on ischemic brain cells. Rat models of cerebral ischemia were intraperitoneally administered syringaldehyde. At 6 and 24 hours after syringaldehyde administration, cell damage in the brain of cerebral ischemia rats was obviously reduced, superoxide dismutase activity and nuclear respiratory factor 1 expression in the brain tissue were markedly increased, malondialdehyde level was obviously decreased, apoptosis-related cysteine peptidase caspase-3 and -9 immunoreactivity was obviously decreased, and neurological function was markedly improved. These findings suggest that syringaldehyde exerts neuroprotective effects on cerebral ischemia injury through anti-oxidation and anti-apoptosis.

**Key Words:** nerve regeneration; syringaldehyde; brain ischemia; neuroprotective effects; inflammatory; oxidative stress; apoptosis; neural regeneration

Bozkurt AA, Mustafa G, Tarik A, Adile O, Murat SH, Mesut K, Yildiray K, Coskun S, Murat C. Syringaldehyde exerts neuroprotective effect on cerebral ischemia injury in rats through anti-oxidative and anti-apoptotic properties. *Neural Regen Res.* 2014;9(21):1884-1890.

## Introduction

Brain tissue is especially susceptible to ischemic damage due to its high speed metabolism and glutamate cycle. As a result of dysfunction of the blood-brain barrier, greater amounts of free oxygen radicals appear (Zivin, 1998; Chan, 2001; Lo et al., 2003). In addition, inflammatory response post-ischemia causes release of cytokines and then further damages the blood-brain barrier (Wang et al., 2007). As a result of disruption of protein synthesis, cytotoxic edema, mitochondrial damage, excitotoxicity, oxidative stress, increased free radicals, necrosis, apoptosis, and inflammatory events, irreversible damage to brain tissue occurs (Freeman et al., 1982).

Syringaldehyde (SA) is a polyphenolic compound in the flavonoid group with low molecular weight found mostly in plants. Huang et al. (2012) showed that SA has antihyperglycemic effect in streptozotocin-induced diabetic rats. The antioxidant, antithrombotic, antihypertensive, anti-inflammatory and anticancer effects of flavonoids have been shown by many studies (Simonyi et al., 2005; Lee et al., 2009).

To date, there are few studies on the neuroprotective effects of SA in a rat model of cerebral ischemia. In this study, we hypothesized that SA prevents against cell damage in the brain caused by cerebral ischemia through its anti-oxidative

and anti-apoptotic effects.

## Materials and Methods

### Animals

Sprague-Dawley male rats, weighing 250–280 g, were used. All rats were fed with standard pellet rat food (Bil-Yem Ltd, Ankara, Turkey) and water *ad libitum*. An automatic photoperiod was used with white fluorescent light to provide 12-hour dark/light. The temperature was kept at  $23 \pm 2^\circ\text{C}$  and humidity was 55–60%. This study was conducted in Çanakkale Onsekiz Mart University Experimental Research Center, Turkey. Experiments were carried out with the permission of Çanakkale Onsekiz Mart University Animal Ethics Committee in accordance with the *Guide for the Care and Use of Laboratory Animals* (8<sup>th</sup> edition, 2011).

### Drug

SA ( $\geq 98\%$ ; high performance liquid chromatography) was obtained from Sigma-Aldrich (St. Louis, MO, USA). The drug was dispersed in ethanol and the final concentration of ethanol was 10%.

### Experimental design

Animals were equally and randomly divided into four

groups: Control group ( $n = 8$ ): only anesthesia and incision were performed. Ischemia group ( $n = 8$ ): brain ischemia was induced and a single intraperitoneal dose of 1 mL saline with 10% ethanol was administered. Ischemia + SA6 group ( $n = 8$ ): brain ischemia was induced, 10 mg/kg SA was intraperitoneally administered, and rats were sacrificed at 6 hours. Ischemia + SA24 group ( $n = 8$ ): brain ischemia was induced, 10 mg/kg SA was intraperitoneally administered, and rats were sacrificed at 24 hours.

### Surgical procedure and drug administration

In all groups, anesthesia induced by intramuscular injection of 5 mg/kg xylazine (Xsilokain, Bayer, Turkey) and 50 mg/kg ketamine HCl (Ketalar, Eczacibasi, Turkey). None of the animals required respiratory or hemodynamic support. Rats were placed in the prone position on the operation table under sterile conditions and sub-dermal incision was made on the dorsal midline. Using the intraluminal filament method previously described in the literature, occlusion of the middle cerebral artery (MCAO) and focal cerebral ischemia in the right hemisphere was induced (Hata et al., 1998). To induce MCAO, 4/0 nylon monofilament suture material (Ethilon Inc., Somerville, NJ, USA) was inserted in the distal common carotid artery through a small incision and advanced intraluminally 16–18 mm distal of the carotid bifurcation. 10 mg/kg SA was intraperitoneally given to rats 5 minutes after MCAO application in the ischemia + SA6 and ischemia + SA24 groups. 50 mg/kg ketamine was intramuscularly injected in the ischemia SA6 group at 6 hours after SA administration and in the ischemia + SA24, control and ischemia groups at 24 hours after SA administration. After this procedure, the skull was opened and the brain removed. The right hemisphere was divided into two equal pieces with half taken for biochemical estimation and the other half for histopathological investigation. For biochemical analysis, tissues were wrapped in aluminum foil and placed in a freezer at  $-80^{\circ}\text{C}$ .

### Measurement of biochemical estimations

Tissue specimens were pulverized with liquid nitrogen. Then they were homogenized with 1 mL of cold PBS on ice for 30 seconds at 20,000 r/min. The resultant homogenates were centrifuged for 10 minutes at  $4^{\circ}\text{C}$  and 10,000 r/min. Supernatants were taken to another tube. All samples were stored at  $-80^{\circ}\text{C}$  until examination. The samples were brought to  $2-8^{\circ}\text{C}$  on the day of study.

The protein content of the brain tissue was measured by a modification of the method of Lowry et al. (1951) using the Lowry Protein Assay Kit (Catalogue No. 23240; Thermo Scientific Inc., Waltham, MA, USA).

Tissue superoxide dismutase (SOD) activity was determined by nitroblue tetrazolium method which was described by Sun et al. (1988) and modified by Durak et al. (1993). A SOD assay kit (Catalogue No. 706002; Cayman Chemical Company, Ann Arbor, MI, USA) and a spectrophotometer (Shimadzu Corp; Kyoto, Japan) were used for SOD assay. In this method, nitroblue tetrazolium is reduced to blue for-

manzan with superoxide. SOD activity was given as U/mg protein.

Malondialdehyde (MDA) levels were analyzed for lipid peroxidation products using a rat MDA ELISA kit (Cat. No. CK-E30266; Hangzhou Eastbiopharm Co. Ltd., Hangzhou, China). MDA levels were estimated by ELISA technique (Buege et al., 1978). MDA results are given as nmol/mL per mg protein.

Nuclear respiratory factor 1 (NRF-1) target genes control cell adhesion, cell spreading, migration, proliferation and apoptosis. NRF1 levels were estimated by ELISA technique using a rat NRF1 ELISA kit (Cat. No. CK-E90555; Hangzhou Eastbiopharm Co., Ltd., Hangzhou, China). NRF1 results are given as nmol/mL per mg protein.

### Histopathological investigation

The brains were left in 10% neutral formaldehyde solution as fixative. After 24 hours, they were washed for 6–8 hours in running water and passed through ethanol-xylene series for automatic tissue monitoring (Citadel 2000, Thermo Fisher Scientific Shandon Loughborough, England) and submerged in liquid paraffin. Sections at 4–6  $\mu\text{m}$  thick were made for routine hematoxylin-eosin and luxol fast blue staining and sections at 3–4  $\mu\text{m}$  thick were made for immunohistochemical staining. For hematoxylin staining, 15 different areas of interest in each slide were examined. Under a light microscope (Eclipse E-600 Nikon, Japan), appropriate areas of interest were examined at various magnifications and photographs were taken. In the evaluation of hematoxylin-eosin and luxol fast blue staining, a graded scale (+ to +++) was used for measurement of edema, red neurons, vacuolization and neuronal degeneration. Blind grading was used for measurement of edema by a pathologist.

### Immunohistochemistry for caspase-3 and -9

Sections for immunohistochemical staining were left for 20 minutes in xylene, dehydrated with alcohol series (70–99%) and then treated for 10 minutes in a 3%  $\text{H}_2\text{O}_2$  solution. After PBS washes, sections were heated in citrate buffer solution four times each for 5–10 minutes. Then the sections were kept in a secondary blocking agent for 20 minutes. Each preparation was left for 65–70 minutes in different dilutions (1:200–1:250) of primary antibodies [anti-caspase-3 antibody (ab4051) and anti-caspase-9 antibodies (ab32539); Abcam, Cambridge, UK]. Biotinylated goat anti-polyvalent antibody (UltraVision Large Volume Detection System, HRP (Ready-To-Use), TP-125-HL, Thermo Scientific Inc. Waltham, MA, USA) was used without dilution as secondary antibodies. Sections was incubated for 20 minutes at room temperature ( $20-22^{\circ}\text{C}$ ). 3,3'-Diaminobenzidine (DAB) solution was used for inverse staining while staining was completed with Mayer's hematoxylin (Thermo Scientific Inc. Waltham, MA, USA). For negative controls, PBS was used. Samples were covered with suitable covering material and photos of samples were taken. At least 1,000 cells were analyzed in each case. The percentage of cells stained in each case was evaluated semiquantitatively on a 5% incremental

scale ranging from 0 to 95%. A numeric intensity score between 1 and 4 was assigned to each case on a scale from 1 to 4. The results of immunohistochemical staining were divided into four categories according to immunoreactive area percentile values: (+) slight, (++) moderate, (+++) intense and (++++) very intense.

### Functional assessment

The degree of functional deficit was scored using the Bederson's scale (Bederson et al., 1986): 0, normal motor function; 1, failure to extend left forepaw; 2, circling to the contralateral side; 3, lack of coordination; 4, unable to work or in a coma. Neurological status was scored at 0, 6 and 24 hours after ischemia. The individual functional deficits were evaluated by physicians who were blinded to whether vehicles or drugs were administered.

### Statistical analysis

A computer program (SPSS 19.0 software; SPSS Inc., Chicago, IL, USA) was used for statistical analysis. All data are expressed as the mean  $\pm$  SD. The comparisons among four groups were made by one-way analysis of variance followed by the Bonferroni posttest. Histopathological data were evaluated with the Kruskal Wallis tests as they were non-parametric. Statistical significance was accepted as  $P < 0.05$ .

## Results

### Anti-oxidative effect of SA on cerebral ischemic injury

The MDA level in the ischemia + SA6 and ischemia + SA24 groups was significantly reduced compared to the ischemia group and significantly increased compared to the control group ( $P < 0.05$ ). In the ischemia + SA6 and ischemia + SA24 groups, SOD activity and NRF1 level were significantly increased compared to the ischemia group and significantly reduced compared to the control group ( $P < 0.05$ ). There were no significant differences in SOD activity, MDA and NRF-1 levels between ischemia + SA6 and ischemia + SA24 groups ( $P > 0.05$ ) (Figure 1).

### Neuroprotective effect of SA on neurons after cerebral ischemic injury

Hematoxylin-eosin staining showed that in the control group, cells and tissues with normal histological morphology were observed (Figure 2). The outer granular layer cells in the control group were small and triangular, with some having a pyramidal cell body structure. Although neuronal cells occasionally appeared in the slightly eosinophilic stained lamina granulosa, an increasing number of neuronal cells was found in the external pyramidal layer. In the ischemia group, some outer granular layer cells were shrunken, vacuolar and swollen areas were observed surrounding and within the neuroglial area. Intensely stained microglial cells were observed in red neurons and around the vacuolar areas (Figure 2). Hematoxylin-eosin stained chromatin was not observed due to neuronal deaths after ischemia. Red neurons with acidophilic neuronal cyto-

plasm, pyknotic and histomorphometric appearance and neurons damaged by karyorrhexis were observed. Cells with reddish neuronal indicators were less in the ischemia group than in the control group, while in the ischemia group, the majority of cells were observed in the outer granular layer (Figure 2).

Luxol fast blue staining results showed that in the ischemia group, some pyramidal neurons were a little more clearly basophilic than in the control group, and many were found to be stained light blue (Figure 3).

Hematoxylin-eosin staining results showed that in the ischemia + SA6 and ischemia + SA24 groups, increased amounts of neuronal damage occurred after ischemia and there was stronger chromatin signal intensity in the nuclei. Red neurons with severe acidophilic neuronal cytoplasm, pyknotic appearance and karyorrhexis-caused neuronal damage were observed. In the ischemia + SA6 group, the number of red neurons was slightly increased compared to the control group. Red neurons were significantly reduced in number in the ischemia + SA6 group than in the ischemia group. In the ischemia + SA24 group, red neuron count was broadly similar to the amount in the control group. In the ischemia + SA6 and ischemia + SA24 groups, vacuolar areas surrounding the cells, cellular degeneration and swollen areas were significantly reduced compared to the ischemia group (Figures 2, 4).

### Anti-apoptotic effect of SA on neurons after cerebral ischemic injury

In the ischemia group, increased caspase-3 immunoreactivity was found in the cortex and subcortex regions. Caspase-3 immunoreactivity was widely observed along the ischemic zone. Within the ischemic area, some cells exhibited necrotic cell morphology and vacuolization. In the ischemia group, there was an increase in immunopositive cells around the damaged brain tissue. Caspase-3 immunoreactivity in the ischemia + SA6 and ischemia + SA24 groups was significantly less than that in the ischemia group and was similar to that in the control group (Figures 5, 6). Caspase-3 immunoreactivity in the ischemia + SA6 and ischemia + SA24 groups was significantly less than in the ischemia group ( $P < 0.05$ ). In the ischemia + SA6 group, caspase-9 immunoreactivity was similar to that in the ischemia + SA24 group. Around the large cortical neurons, caspase-9 immunoreactive cells were ring-shaped while they were granular within the nucleus. Immunoreactivity for caspase-9 was intense in the pyramidal cells in the ischemia group, and caspase-9 immunopositivity was also present in the endothelial cells of the veins (Figures 5, 6).

### Functional assessment

Following ischemia, animals subsequently exhibit a variety of neurological deficits. No score was found in the control rats or in the hemisphere contralateral to the ischemic side. The neurological scores were significantly decreased at 6 and 24 hours after SA treatment compared to the ischemia group ( $P < 0.05$ ). Moreover, the neurological score of the ischemia

+ SA24 group was lower than that of ischemia + SA6 group ( $P < 0.05$ ) (Figure 7).

## Discussion

During ischemia, deterioration of the brain's energy metabolism, loss of aerobic glycolysis, accumulation of intracellular sodium and calcium, increase in lactate level, production of free radicals, cell swelling, and over-activation of lipase and protease occur, and as a result of all these, cell death is seen (Choi, 1996; Fisher et al., 2003). Developing treatment strategies before ischemia cause permanent neuronal damage. During ischemic damage, reactive oxygen components are inactivated by antioxidants such as SOD, catalase, glutathion peroxidase, vitamin C and E (Chan, 2001). However, neurons are very susceptible to oxidative damage and have limited antioxidant capacity. Recently, some scholars found some molecules with antioxidant and anti-inflammatory effects to reduce permanent damage in ischemia models.

SA is a polyphenolic compound in the flavonoid group (Lee et al., 2009). Huang et al. (2012) showed the reducing effect of SA on plasma glucose levels in diabetic rats. In a study by Farah and Samuelsson (1992) showed that edema was induced in the ears of rats using ethyl phenylpropionate and syringaldehyde was effective as aspirin to prevent edema. Accordingly, they reported that SA had an inhibitory effect on prostaglandin synthesis. Stanikunaite et al. (2009) reported that SA obtained from *Elaphomyces* granulates inhibited the activity of COX-2 in mouse macrophages. Lee et al. (2009) compared SA, quercetin and trolox and found that SA had twice greater antioxidant effect than quercetin and 10 times more than trolox. To the best of our knowledge, there has been no study on the effect of SA on ischemic damage in the brain.

SOD is a metalloenzyme that protects cells from the toxic effects of endogenously formed superoxide radicals. SOD catalyses the transformation of superoxide to hydrogen peroxide and is the primary protector against oxygen radicals (Karaođlan et al., 2002). SOD, a free radical scavenger, is an endogenous antioxidant enzyme naturally found in mitochondria. Islekel et al. (1999) showed that SOD activity reduced after experimental cerebral ischemia in rats. Deng et al. (2000) reported that SOD activity decreased in experimental focal cerebral ischemia tissue, and that after treatments with 3,6-dimethamidobenzopyridonium gluconate, tissue SOD activity increased again. In our study, SA treatment increased SOD activity in the ischemic brain.

Tissue MDA levels reflect tissue damage linked to lipid peroxidation where free radicals play a role in energy metabolism (Lazzarino et al., 1992). Many studies have shown that after ischemia, MDA levels increase in cerebral tissue (Barut et al., 1993; Yavuz et al., 1997; Calapai et al., 2000; Cuzzocrea et al., 2000; Stvolinsky et al., 2000). Lipid peroxidation caused by free radicals along with reasons such as falling ATP levels due to reduced tissue perfusion, hypoxia, dysfunction of cell membrane permeability and mitochondrial damage

are linked to an increase in calcium concentration within cells (Tymianski et al., 1996). Yavuz et al. (1997) reported that tissue MDA levels increased after cerebral ischemia and they decreased markedly after 2-chloroadenosine treatment. In our study, SA treatment after ischemia caused a decrease in MDA levels from the 6<sup>th</sup> hour on.

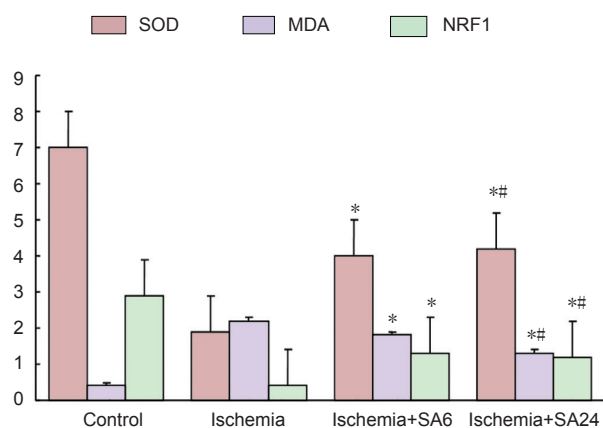
NRF1 has an antioxidant structure and plays an important role in regulating the enzymes that appear during oxidative stress (Yin et al., 2008). Recently, a study of neonatal hypoxic ischemic brains in rat models have shown increased NRF1 levels (Yin et al., 2008). Another study similarly showed increased levels of NRF1 in regulating mitochondrial biogenesis after ischemia in rats with induced experimental ischemia (Choi, 1996; Chan, 2001; Gutsaeva et al., 2008; Yin et al., 2008). In our study, similar to the literature, NRF1 level, a marker of mitochondrial biogenesis, was reduced in the ischemia group but significantly increased in the ischemia + SA6 and ischemia + SA24 groups (Gutsaeva et al., 2008; Yin et al., 2008; Kumari et al., 2012; Mehta et al., 2012).

During brain ischemia, apoptosis starts in 2 ways, intrinsic and extrinsic. Stimulation of cytochrome c and caspase-3 forms the intrinsic pathway (Broughton et al., 2009). Caspase-3 and -9 are known to be important in ischemic apoptosis in neuronal cells. Caspase-3 plays a key role in apoptosis following ischemic stroke (Porter et al., 1999). Active caspase-3 causes DNA disintegration (Li et al., 1995). Some studies have shown a relationship between DNA disintegration and development of ischemic infarcts (Li et al., 1997). Abas et al. (2010) applied a temporary focal cerebral ischemic model in rats and found that the caspase-3 and -9 activities were increased compared to the control group, but this was not statistically significant (Abas et al., 2010). In our study, in the ischemia + SA6 and ischemia + SA24 groups, caspase-3 and -9 immunoreactivities were significantly less than in the ischemia group. These findings indirectly indicate that SA treatment reduces apoptosis.

To prevent ischemic damage to the brain, SA is a very effective antioxidant. If our findings are supported by ultrastructural studies, we believe that SA will have a place in preventive treatment of brain ischemia.

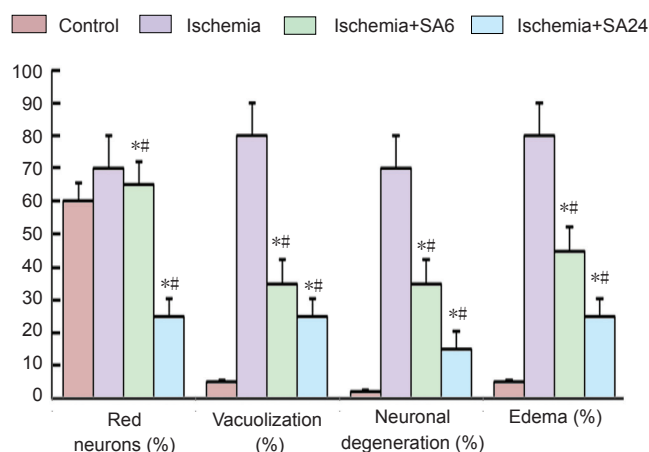
**Author contributions:** Bozkurt AA, Mustafa G, Tarık A and Murat SH were responsible for literature retrieval. Bozkurt AA, Mustafa G, Tarık A, Murat SH and Mesut K were in charge of data acquisition. Bozkurt AA, Mustafa G, Murat SH, Mesut K, Yıldırım K and Murat C were responsible for data analysis. Bozkurt AA, Mustafa G and Murat C participated in statistical analysis and drafted the manuscript. Bozkurt AA, Mustafa G, Tarık A, Murat SH, Mesut K and Murat C edited the manuscript. Bozkurt AA, Mustafa G, Mesut K and Murat C were the guarantors of the study. All authors participated in the concept and design of the study, experimental performance, definition of the intellectual content, and approved the final version of the article.

**Conflicts of interest:** None declared.



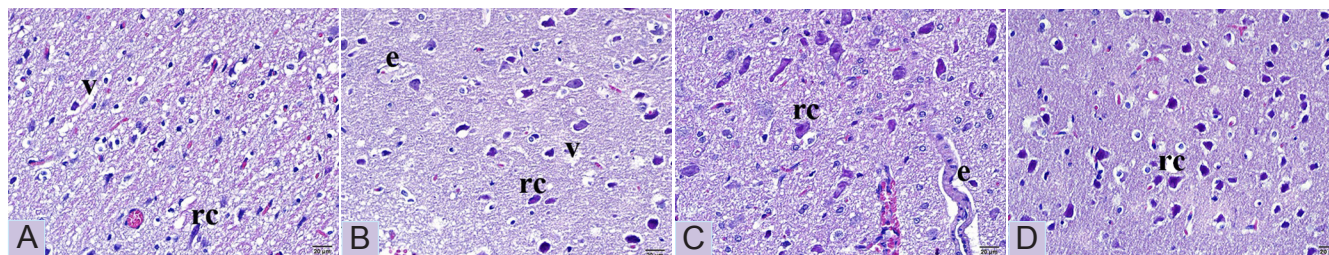
**Figure 1** Superoxide dismutase (SOD, U/mg protein) activity, malonaldehyde (MDA, nmol/mL per mg protein) and nuclear respiratory factor-1 (NRF1, nmol/mL per mg protein) levels in brain tissue of rats.

The comparisons among four groups were made by one-way analysis of variance followed by the Bonferroni post test. Data were expressed as the mean  $\pm$  SD. \* $P < 0.05$ , vs. ischemia and control groups. # $P > 0.05$ , vs. ischemia + SA6 group. SA6: 6 hours after syringaldehyde administration; SA24: 24 hours after syringaldehyde administration.



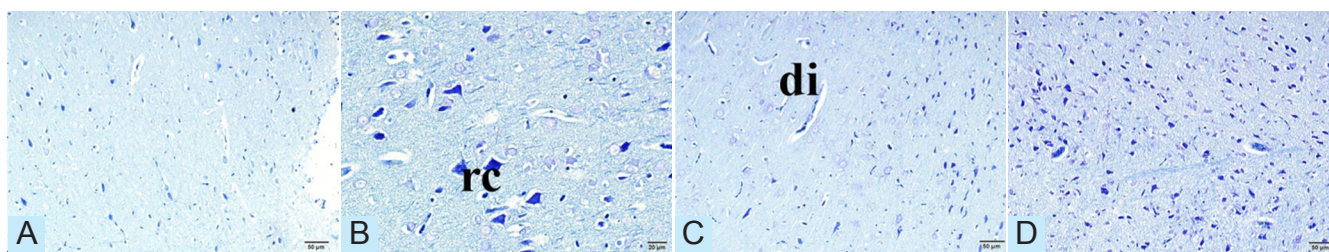
**Figure 4** Effect of SA on edema, red neurons, vacuolization and neuronal degeneration in ischemic brain at 6 and 24 hours after middle cerebral artery occlusion.

Neuronal cells in the area were counted to determine cell density. Data were expressed as percentiles and compared between groups using the Kruskal Wallis test. Data were expressed as the mean  $\pm$  SD. \* $P < 0.05$ , vs. ischemia group. # $P < 0.05$ , vs. control group. SA6: 6 hours after syringaldehyde administration; SA24: 24 hours after syringaldehyde administration.



**Figure 2** Representative pathomorphological photomicrographs of ischemic rat brain tissue stained with hematoxylin-eosin.

(A) Ischemia group; (B) ischemia + SA6 group; (C) ischemia + SA24 group; (D) control group. Compared to the ischemia group, red neurons were reduced in the ischemia + SA6 and ischemia + SA24 groups. Red neurons (rc), edema (e) and vacuolization (v) are shown. Scale bars: 20  $\mu$ m. SA6: 6 hours after syringaldehyde administration; SA24: 24 hours after syringaldehyde administration.



**Figure 3** Representative photomicrographs showing neurons stained with Luxol Fast Blue in the ischemic brain area of rats at 6 and 24 hours after syringaldehyde treatment.

(A) Ischemia group; (B) ischemia + SA6 group; (C) ischemia + SA24 group; (D) control group. Vascular dilatation (di) and red neurons (rc) are shown. Scale bars: 20  $\mu$ m. SA6: 6 hours after syringaldehyde administration; SA24: 24 hours after syringaldehyde administration.

## References

Abas F, Alkan T, Goren B, Taskapilioglu O, Sarandol E, Tolunay S (2010) Neuroprotective effects of postconditioning on lipid peroxidation and apoptosis after focal cerebral ischemia/reperfusion injury in rats. *Turk Neurosurg* 20:1-8.

Barut S, Canbolat A, Bilge T, Aydin Y, Cokneseli B, Kaya U (1993) Lipid peroxidation in experimental spinal cord injury: time-level relationship. *Neurosurg Rev* 16:53-59.

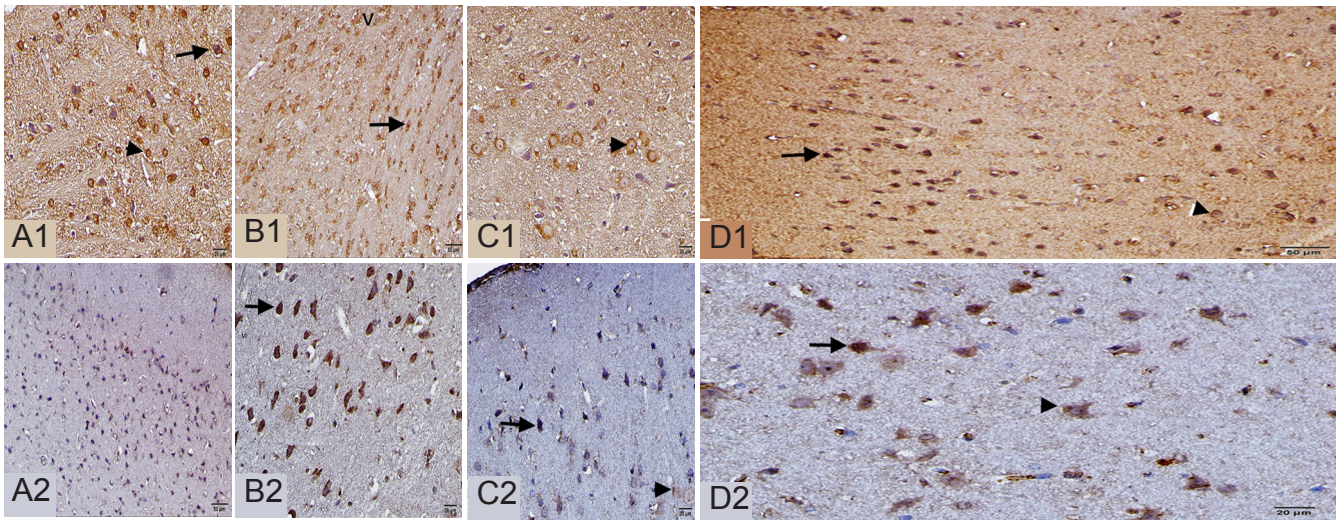
Bederson JB, Pitts LH, Tsuji M, Nishimura MC, Davis RL, Bartkowski H (1986) Rat middle cerebral artery occlusion: evaluation of the model and development of a neurologic examination. *Stroke* 17:472-476.

Broughton BR, Reutens DC, Sobey CG (2009) Apoptotic mechanisms after cerebral ischemia. *Stroke* 40:e331-339.

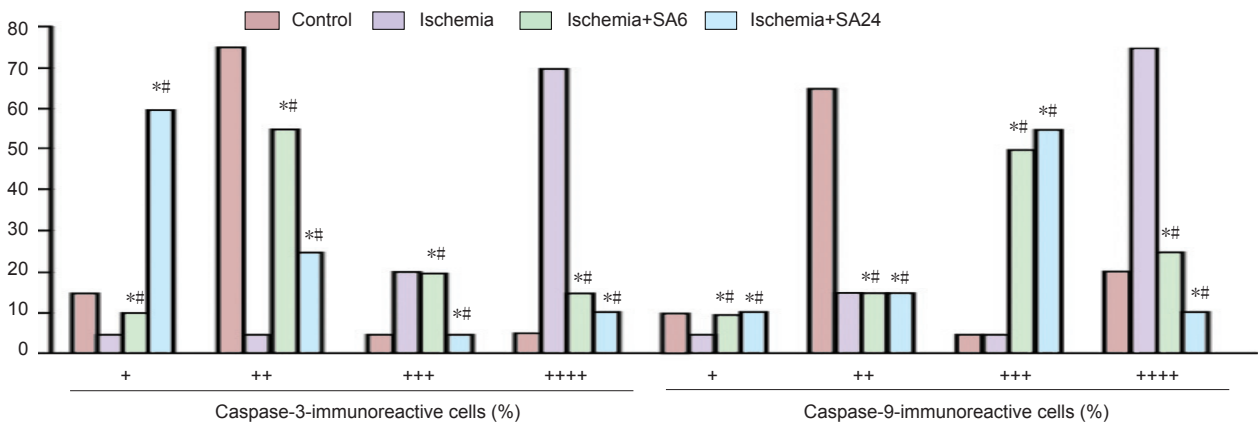
Buege JA, Aust SD (1978) Microsomal lipid peroxidation. *Methods Enzymol* 52:302-310.

Calapai G, Crupi A, Firenzuoli F, Marciano MC, Squadrito F, Inferrera G, Parisi A, Rizzo A, Crisafulli C, Fiore A, Caputi AP (2000) Neuroprotective effects of Ginkgo biloba extract in brain ischemia are mediated by inhibition of nitric oxide synthesis. *Life Sci* 67:2673-2683.

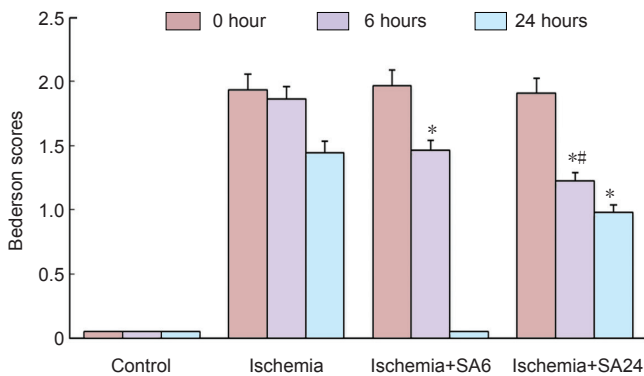
Chan PH (2001) Reactive oxygen radicals in signaling and damage in the ischemic brain. *J Cereb Blood Flow Metab* 21:2-14.



**Figure 5** Caspase-3 (A1–D1) and caspase-9 (A2–D2) immunoreactivities in the ischemic brain tissue at 6 and 24 hours after syringaldehyde treatment. The representative example of immunohistochemical images in ischemia group (A1–A2), ischemia + SA6 group (B1, B2), ischemia + SA24 group (C1, C2) and control group (D1, D2). Immunoreactivity for caspase-3 and -9 in neurons (arrows) and perinuclear areas (arrowheads) are shown. Vacuolization (v) is shown. Caspase-3 and -9 immunoreactivities decreased in the ischemia + SA6 and ischemia + SA24 groups compared to the ischemia group. Scale bars: 20 μm. SA6: 6 hours after syringaldehyde administration; SA24: 24 hours after syringaldehyde administration.



**Figure 6** Effect of syringaldehyde on caspase-3 and -9 immunoreactivities in ischemic brain tissue of rats. Data expressed as percentiles. \* $P < 0.05$ , vs. ischemia group; # $P > 0.05$ , vs. control group. Data comparison between groups was performed using Kruskal Wallis tests. SA6: 6 hours after syringaldehyde administration; SA24: 24 hours after syringaldehyde administration.



**Figure 7** Effect of syringaldehyde on Bederson scores in rats with cerebral ischemia injury. Data expressed as the mean  $\pm$  SD. \* $P < 0.05$ , vs. ischemia group; # $P < 0.05$ , vs. ischemia + SA6 group. The comparisons among four groups were made by one-way analysis of variance followed by the Bonferroni post test. SA6: 6 hours after syringaldehyde administration; SA24: 24 hours after syringaldehyde administration.

Choi DW (1996) Ischemia-induced neuronal apoptosis. *Curr Opin Neurobiol* 6:667-672.

Cuzzocrea S, Costantino G, Gitto E, Mazzon E, Fulia F, Serrano I, Cordaro S, Barberi I, De Sarro A, Caputi AP (2000) Protective effects of melatonin in ischemic brain injury. *J Pineal Res* 29:217-227.

Deng XL, Qian ZY, Liu NF, Ma XY, Wang HF, Hou ZJ (2000) Antagonistic effect of 3,6-dimethamidodibenzopyridonium gluconate on lipid peroxidation in cerebral cortical neuronal cultures and rat brains during focal cerebral ischemia reperfusion. *Acta Pharmacol Sin* 21:460-462.

Durak I, Yurtarslan Z, Canbolat O, Akyol O (1993) A methodological approach to superoxide dismutase (SOD) activity assay based on inhibition of nitroblue tetrazolium (NBT) reduction. *Clin Chim Acta* 214:103-104.

Farah MH, Samuelsson G (1992) Pharmacologically active phenylpropanoids from *Senecio jacobina*. *Planta Med* 58:14-18.

Fisher AB, Al-Mehdi AB, Wei Z, Song C, Manevich Y (2003) Lung ischemia: endothelial cell signaling by reactive oxygen species. A progress report. *Adv Exp Med Biol* 510:343-347.

Freeman BA, Crapo JD (1982) Biology of disease: free radicals and tissue injury. *Lab Invest* 47:412-426.

- Gutsaeva DR, Carraway MS, Suliman HB, Demchenko IT, Shitara H, Yonekawa H, Piantadosi CA (2008) Transient hypoxia stimulates mitochondrial biogenesis in brain subcortex by a neuronal nitric oxide synthase-dependent mechanism. *J Neurosci* 28:2015-2024.
- Hata R, Mies G, Wiessner C, Fritze K, Hesselbarth D, Brinker G, Hossmann KA (1998) A reproducible model of middle cerebral artery occlusion in mice: hemodynamic, biochemical, and magnetic resonance imaging. *J Cereb Blood Flow Metab* 18:367-375.
- Huang CH, Chen ME, Chung HH, Cheng JT (2012) Antihyperglycemic effect of syringaldehyde in streptozotocin-induced diabetic rats. *J Nat Prod* 75:1465-1468.
- Islekel S, Islekel H, Guner G, Ozdamar N (1999) Alterations in superoxide dismutase, glutathione peroxidase and catalase activities in experimental cerebral ischemia-reperfusion. *Res Exp Med (Berl)* 199:167-176.
- Karaođlan A, Uçankale MH, Barut S, Uzun H, Belce A, Çolak A (2002) Neuroprotective effect of tirofiban on temporary brain ischemia in rats: a preliminary report. *Turk Neurosurg* 12:40-47.
- Kumari S, Anderson L, Farmer S, Mehta SL, Li PA (2012) Hyperglycemia alters mitochondrial fission and fusion proteins in mice subjected to cerebral ischemia and reperfusion. *Transl Stroke Res* 3:296-304.
- Lazzarino G, Vagnozzi R, Tavazzi B, Pastore FS, Di Pierro D, Siragusa P, Belli A, Giuffrè R, Giardina B (1992) MDA, oxypurines, and nucleosides relate to reperfusion in short-term incomplete cerebral ischemia in the rat. *Free Radic Biol Med* 13:489-498.
- Lee CY, Sharma A, Cheong JE, Nelson JL (2009) Synthesis and antioxidant properties of dendritic polyphenols. *Bioorg Med Chem Lett* 19:6326-6330.
- Li P, Nijhawan D, Budihardjo I, Srinivasula SM, Ahmad M, Alnemri ES, Wang X (1997) Cytochrome c and dATP-dependent formation of Apaf-1/caspase-9 complex initiates an apoptotic protease cascade. *Cell* 91:479-489.
- Li Y, Chopp M, Jiang N, Yao F, Zaloga C (1995) Temporal profile of in situ DNA fragmentation after transient middle cerebral artery occlusion in the rat. *J Cereb Blood Flow Metab* 15:389-397.
- Lo LW, Wilson DF (2003) A micro-light guide system for measuring oxygen by phosphorescence quenching. *Adv Exp Med Biol* 540:117-123.
- Lowry OH, Rosebrough NJ, Farr AL, Randall RJ (1951) Protein measurement with the Folin phenol reagent. *J Biol Chem* 193:265-275.
- Mehta SL, Kumari S, Mendelev N, Li PA (2012) Selenium preserves mitochondrial function, stimulates mitochondrial biogenesis, and reduces infarct volume after focal cerebral ischemia. *BMC Neurosci* 13:79.
- Porter AG, Janicke RU (1999) Emerging roles of caspase-3 in apoptosis. *Cell Death Differ* 6:99-104.
- Simonyi A, Wang Q, Miller RL, Yusof M, Shelat PB, Sun AY, Sun GY (2005) Polyphenols in cerebral ischemia: novel targets for neuroprotection. *Mol Neurobiol* 31:135-147.
- Stanikunaite R, Khan SI, Trappe JM, Ross SA (2009) Cyclooxygenase-2 inhibitory and antioxidant compounds from the truffle *Elaphomyces granulatus*. *Phytother Res* 23:575-578.
- Stvolinsky SL, Dobrota D (2000) Anti-ischemic activity of carnosine. *Biochemistry (Mosc)* 65:849-855.
- Sun Y, Oberley LW, Li Y (1988) A simple method for clinical assay of superoxide dismutase. *Clin Chem* 34:497-500.
- Tymianski M, Tator CH (1996) Normal and abnormal calcium homeostasis in neurons: a basis for the pathophysiology of traumatic and ischemic central nervous system injury. *Neurosurgery* 38:1176-1195.
- Wang Y, Zhang ZG, Rhodes K, Renzi M, Zhang RL, Kapke A, Lu M, Pool C, Heavner G, Chopp M (2007) Post-ischemic treatment with erythropoietin or carbamylated erythropoietin reduces infarction and improves neurological outcome in a rat model of focal cerebral ischemia. *Br J Pharmacol* 151:1377-1384.
- Yavuz O, Turkozkan N, Bilgihan A, Dogulu F, Aykol S (1997) The effect of 2-chloroadenosine on lipid peroxide level during experimental cerebral ischemia-reperfusion in gerbils. *Free Radic Biol Med* 22:337-341.
- Yin W, Signore AP, Iwai M, Cao G, Gao Y, Chen J (2008) Rapidly increased neuronal mitochondrial biogenesis after hypoxic-ischemic brain injury. *Stroke* 39:3057-3063.
- Zivin JA (1998) Recent advances in stroke therapy. *West J Med* 168:261-262.

*Copypedited by Ahmed MA, Nakamura T, Li CH, Song LP, Zhao M*