

Influence of infliximab pretreatment on ischemia/reperfusion injury in rat intestine

Remzi Adnan Akdogan¹, Yıldırım Kalkan², Levent Tumkaya²,
Hasan Alacam³, Başar Erdivanlı⁴, İbrahim Aydın⁵

¹Division of Gastroenterology, Department of Internal Medicine, Recep Tayyip Erdoğan University, Rize, Turkey

²Department of Histology and Embryology, School of Medicine, Recep Tayyip Erdoğan University, Rize, Turkey

³Department of Biochemistry, Ondokuz Mayıs University, Samsun, Turkey

⁴Department of Anesthesiology and Intensive Care, Recep Tayyip Erdoğan University, Rize, Turkey

⁵Department of General Surgery, School of Medicine, Recep Tayyip Erdoğan University, Rize, Turkey

Abstract. The Pringle maneuver is used in hepatic surgery to prevent blood loss but is associated with ischemia-reperfusion injury. To investigate the effect of infliximab on inflammation and apoptosis in rat intestinal mucosa during ischemia-reperfusion (IR) injury. A total of 30 male Wistar albino rats were equally divided into three groups to be subjected to (i) sham operation (sham), (ii) IR injury *via* Pringle maneuver (pringle) or (iii) infliximab (IFX) group (IFX was given at a dose 3 mg/kg for 3 days before IR injury). Following reperfusion period of 60 min., intestinal tissue and blood samples were taken and processed by standard histological methods. The Pringle maneuver and following reperfusion caused significant histopathological changes, increased serum transaminases' activity and the levels of oxidative stress markers and decreased glutathione peroxidase activity. IFX pretreatment partially prevented these changes. Infliximab pretreatment may protect intestinal mucosa against ischemia-reperfusion injury. Further studies are needed to investigate mechanism and evaluate safety and optimal dosing of IFX in humans exposed to the possible tissue damage by ischemia-reperfusion. (*Folia Histochemica et Cytophiologica* 2014, Vol. 52, No. 1, 36–41)

Key words: Pringle maneuver; ischemia-reperfusion injury; TNF; infliximab; calcineurin; caspase 3; transaminases; oxidative stress

Introduction

Surgery and general anesthesia during hepatic surgery may cause tissue hypoxia due to decreased tissue perfusion. Ischemic period is particularly long in tumor, trauma or transplantation cases, where Pringle maneuver is commonly used. Ischemia-reperfusion injury (IRI) results in immunological [1], metabolic

[2] and microvascular changes [3], cellular damage and dysfunction [4]. IRI may also occur in extrahepatic tissues [5], such as lung [6], kidney [7] and small intestine, depending on systemic response.

Extent of injury increases during reperfusion when oxygen reaches ischemic tissues. Oxygen radicals, inflammatory cytokines and neutrophils' activation play a key role in the development of IRI [8]. Interleukin-2 (IL-2) and tumor necrosis factor- α (TNF- α) are the most potent triggers of this cascade. Both IL-2 and TNF- α are produced in T-cells in a processes which involve action of calcineurin (Cn) and caspase enzymes, respectively [9]. Infliximab (IFX), used in the treatment of inflammatory bowel disease and rheumatic disease [10], inhibits TNF- α activity

Corresponding author: B. Erdivanlı M.D., Recep Tayyip Erdoğan Üniversitesi Eğitim ve Araştırma Hastanesi, İslampaşa Mahallesi, Şehitler caddesi, No: 74, 53100, Rize
tel.: +90 464 213 04 91; fax: +90 464 217 03 64;
e-mail: berdivanli@gmail.com

as chimeric monoclonal IgG antibody [11, 12] and decreases free oxygen radical formation [13]. We hypothesized that infliximab may prevent IRI in intestine wall. Following IRI, the number of apoptotic cells in small intestine's wall increases with mucosal erosion, edema, and villous denudation [14]. Calcineurin is a serine phosphatase, which dephosphorylates nuclear factor of activated T-cells (upon contact with increased intracellular calcium) and mediates further T-cell activation and IL-2 production [14]. Cn expression was demonstrated in several tissues in rat [15–17]. The caspase 3 (Casp3) protein is a member of the cysteine-aspartic acid protease (caspase) family. Casp3 is a zymogen, which can be activated via binding of TNF- α to TNFR1, and causes apoptosis in cells targeted by cytotoxic T-cells. Therefore, we investigated Casp3 and Cn expression by immunohistochemistry under the conditions of IFX's effect on the outcome of ischemia-reperfusion resulting from Pringle maneuver.

Material and methods

A total of 30 adult male Wistar albino rats weighing 275–300 g were housed in a sterile environment at a room temperature of $22 \pm 3^\circ\text{C}$ and 55–60% humidity with 12 hour lighting. Animals were fed with pelleted rat food and water ad libitum. Methods used for animal experiments were regulated according to the protocol of National Institute of Health Guide for the Care and Use of Laboratory Animals. Necessary permissions were received from Recep Tayyip Erdogan University Faculty of Medicine Animal Experiments Local Ethics Committee (Date: 31.01.2012, Decision no: 02).

The primary outcome was to document changes in rat intestinal cell morphology using histopathological, light microscopic and immunohistochemical methods. Secondary endpoint was to document changes in serum TNF- α , malondialdehyde (MDA), glutathione-peroxidase (GSH-Px), alanine aminotransferase (ALT) and aspartate aminotransferase (AST) levels. Rats were randomized into three groups ($n = 10$ each) as (i) sham operation, *i.e.* control group (sham), (ii) ischemia-reperfusion injury caused by Pringle maneuver (Pringle group), and (iii) infliximab+pringle group (rats received 3 mg/kg intraperitoneally IFX for 3 days before ischemia-reperfusion).

Pelleted food intake was restricted 12 hours and water intake 2 hours before anesthesia. Anesthesia was achieved *via i.p.* injection of 50 mg/kg *i.p.* ketamine (Ketalar®, Parke-Davis, Istanbul, Turkey) and 5 mg/kg xylazine (Rompun®, Bayer, Istanbul, Turkey). Following midline incision in the abdomen,

the hepatic hilus was explored and the hepatic pedicle was clamped. After 90 min, the clamp was opened to reperfuse the liver for 60 min. Thereafter, ileum and 6 ml blood from right ventricle were taken. The animals were killed by exsanguination through cardiac puncture and blood collection.

Histopathology. The small intestine specimens were fixed in 10% neutral formaldehyde for 24 hours, washed under running water for 8 hours and embedded into liquid paraffin by rinsing out with ethanol-xylene series, using automated tissue follow-up system (Citadel 2000, Thermo Fisher Scientific, Shandon, England). Tissues were cut in 5 μm thickness using rotary microtome (RM2255, Leica, Wetzlar, Germany) for hematoxylin and eosin (H&E) staining and in 3 μm thickness for immunohistochemical staining. Tissue sections stained with H&E were examined with a digital camera (DP72, Olympus, Tokyo, Japan) attached to light microscope (BX51, Olympus, Tokyo, Japan).

Immunohistochemistry. Calcineurin and Caspase 3 expression was analyzed by immunohistochemistry using a streptavidin-biotin peroxidase method. EnVision™ FLEX DAB chromogen (DM827, DAKO, Glostrup, Denmark) and EnVision™ FLEX Substrate Buffer (DM823, DAKO) to detect peroxidase activity. Small intestinal tissue specimens were deparaffinized with xylene for streptavidin-biotin peroxidase method and rehydrated in graded ethanol series. Slices were incubated in 3% H_2O_2 to block endogen peroxidase activity and in normal bovine serum to block nonspecific binding sites of antibodies. Sections were incubated with primary antibody to calcineurin (Purified Mouse Anti-Calcineurin, clone 29-Calcineurin, 1:200 dilution, BD Biosciences, San Diego, California, USA) and CASP3 (Anti-active Caspase-3 antibody, ab13847, 1:50, Abcam, Cambridge, MA, USA) for 60 min at room temperature (23°C), and then incubated in a biotinylated secondary antibody (Streptavidin-Horseradish Peroxidase Universal LSAB Kit-K0690, DAKO) for 30 min. Antibody binding sites were stained with 3,3-diaminobenzidine (DAB), and washed with phosphate-buffered saline (PBS). Nuclei were stained with EnVision™ FLEX Hematoxylin (Code K8018, DAKO), dehydrated in ethanol series and cleared with xylene. The treated sections were then mounted with Entellan medium (Code 107960, Merck, Darmstadt, Germany) and examined under light microscope. Tissue injury in the intestinal mucosa was evaluated using light microscope according to criteria described by Chiu et al. and scored between 0 and 5 [18].

Biochemical assays. TNF- α concentration in serum specimens was measured using an enzyme amplified sensitivity immunoassay method according to manufacturer's protocol (DIAsource ImmunoAssays, Louvain-la-Neuve, Belgium) and measured on microplate reader (Sunrise-Basic, Tecan,

Grödig, Austria). Results were expressed as pg/mL. MDA level in serum specimens was measured with the method of Draper et al [19]. After trichloroacetic acid was pipetted into serum specimens, they were incubated at 90°C for 15 min and centrifuged at 4°C at 3000 g for 20 min. Thiobarbituric acid was added into supernatant obtained, and absorbance of specimens was determined at 532 nm. MDA amount was calculated on the basis of molar extinction coefficient ($1,56 \times 10^5 \text{M}^{-1} \times \text{cm}^{-1}$) of TBA-MDA complex. Results of lipid peroxidation were expressed as $\mu\text{mol/dL}$. GSH-Px activity was measured according to the method of Paglia et al [20]. GSH-Px catalyzes oxidation of reduced glutathione to oxidized glutathione. At the next stage, formed glutathione is reduced to reduced glutathione in the presence of glutathione reductase and NADPH. For that purpose, serum was pipetted into the medium containing reduced glutathione, NADPH, glutathione reductase and incubated at room temperature for 30 min. At the next stage, hydrogen peroxide was added, and decrease in absorbance was recorded. GSH-Px level was calculated and expressed as U/dL [21]. Serum ALT and AST activities were measured *via* spectrophotometric method using an autoanalyzer (P800 Modular Analytics P, Roche Diagnostic Ltd., West Sussex, UK).

Statistical analysis. Data were analyzed using the SPSS program (SPSS for Windows, v. 12.0, IBM, Chicago, IL, USA). AST, ALT, MDA, TNF, and GSH-Px values were expressed as mean \pm SD, analyzed using one-way ANOVA analysis of variance with least significant difference ($p < 0.05$). Multiple comparison tests (Post-Hoc Tukey HSD parametric tests) were used to identify significant differences between groups. For comparisons between groups, p value was divided into the number of comparisons, which gives a p value of $0.05/3 = 0.017$. Histopathological grades, degree of inflammatory cell infiltration, intensity grades of Casp3 and Cn stainings were expressed as median (min-max). Kruskal-Wallis test was used for inter-group analysis ($p < 0.05$) and Mann-Whitney-U test for pairwise comparison of groups).

Results

Histopathologic evaluation

Small intestine specimens of sham group showed normal intestinal mucosa and villi with tall columnar epithelium and numerous goblet cells within normal histomorphological structure (Figure 1A). The morphology of the intestinal mucosa in the ischemia-reperfusion (Pringle) group is shown in Figure 1B. We observed significant epithelial cell loss (cellular debris inside the lumen) compared with sham group. Moreover, we found decreased capillary density and presence of erythrocytes in broad and shortened villi with necrotic tips, vacuolization in muscular layer, dilation in majority of capillary vessels both in the mu-

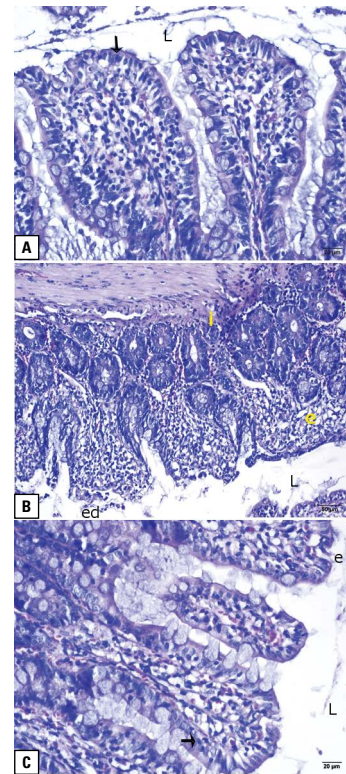


Figure 1. Histopathological changes observed in rat small intestine specimens (H&E staining). **A.** Sham group, $\times 40$, bar $20 \mu\text{m}$. **B.** Pringle group, $\times 20$, bar $50 \mu\text{m}$. **C.** Infliximab + pringle group, $\times 40$, bar $20 \mu\text{m}$. Abbreviations and symbols: e: edema; ed: epithelial degeneration; i: lymphocyte infiltration; L: lumen; arrowhead: normal epithelium

cosal and muscular layers, significant mucosal edema, many leukocytes and swollen endothelial cells in the postcapillary venules of the small intestine (Figure 1B). Infliximab+pringle group (Figure 1C) showed slight edema, epithelial cell degeneration and necrosis in mucosal villi. We observed slight vacuolization in lamina propria and villi with few goblet cells and columnar epithelium. Moreover, there was a slight increase in the number of erythrocytes, leukocytes and endothelial cells in the postcapillary venules of the bowel (Figure 1C).

Lymphocytic infiltration was absent in sham group, however, it was severe in Pringle group (especially in mucosal epithelial layer) and moderate in infliximab+pringle group (in mucosal epithelial layer, inside the lamina propria and around the vessels) (Figure 1).

Immunohistochemical demonstration of calcineurin and caspase 3

Sham group showed high Cn immunopositivity in intestinal villi, near crypts and in regions close to tunica

Table 1. Inflammatory and immunoreactivity scoring (on a scale of 0 to 5) of small intestine mucosa.

| | Sham (n = 10) | Pringle (n = 10) | Pringle + infliximab (n = 10) |
|--------------------------------|---------------|------------------|-------------------------------|
| Inflammatory cell infiltration | 0 (0–4)* | 3 (1–3) | 2 (1–2)† |
| Calcineurin expression | 3 (2–3)* | 1 (1–2) | 2 (1–3)† |
| Caspase-3 expression | 1.5 (1–2) | 2 (2–3)* | 1.5 (1–2) |

Calcineurin and caspase-3 expression was visualized by immunohistochemistry. Data are presented as median and range (min-max); *p < 0.015 vs. other groups; †p < 0.015 vs. pringle group

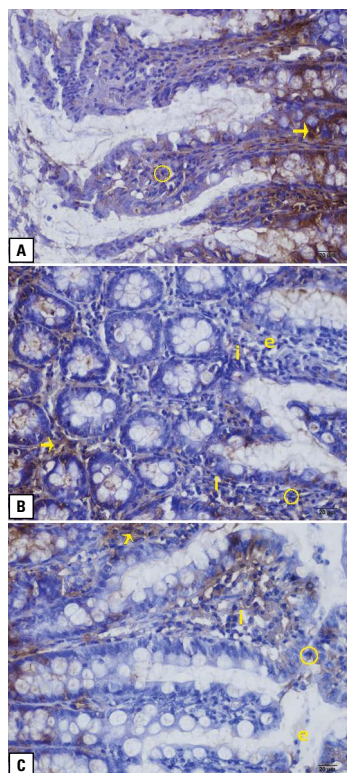


Figure 2. Calcineurin expression in the mucosa of rat small intestine. **A.** Sham group, × 40, bar 20 μm. **B.** Pringle group, e: edema, i: lymphocyte infiltration; × 40, bar, 20 μm. **C.** Infliximab+pringle group,; × 40, bar: 20 μm. Calcineurine expression was visualized by immunohistochemistry as described in Methods. Abbreviations as for Figure 1. Symbols: arrowhead, high immunopositive reaction (+++); circle: moderate positivity (++)

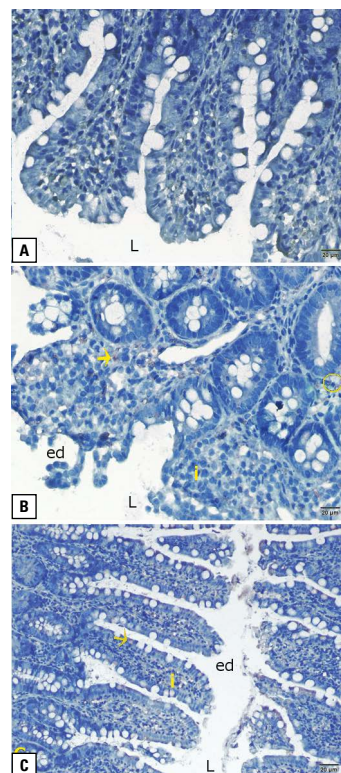


Figure 3. Caspase-3 expression in epithelial cells of the small intestine. **A.** Sham group, × 20, bar 50 μm. **B.** Pringle group, × 40, bar 20 μm. **C.** Infliximab+pringle group, × 40, bar: 20 μm. Abbreviations as for Figure 1. Symbols: arrowhead: moderate immunoreactivity (++) ; circle, weak immunoreactivity (+)

muscularis layer (Table 1, Figure 2A). Pringle group showed weak Cn immunopositivity near intestinal crypts and in unexfoliated regions of epithelium. Exfoliated and edematous regions showed no or weak Cn immunopositivity (Figure 2B). Infliximab + pringle group (Figure 2C) showed moderate Cn immunopositivity in the apical region of epithelial cells and close to intestinal crypts. The staining was weak in the region between crypts and tunica muscularis and was absent in edematous regions (Table 1, Figure 2C).

All groups showed weak caspase 3 immunoreactivity in the epithelium of intestinal villi and to a lesser extent in tunica muscularis and crypts. (Table 1, Figure 3). The staining was slightly more pronounced in Pringle group in epithelial cells and was especially strong in exfoliated cells (Table 1, Figure 3B). The difference in the staining intensity between sham and infliximab+pringle groups was non-significant, while statistically significant differences were found between Pringle and other groups (p = 0.006).

Table 2. Serum activities of transaminases and glutathione peroxidase and concentrations of TNF- α and malondialdehyde

| | Sham | Pringle | Infliximab + pringle |
|-----------------------|------------------|--------------------|----------------------|
| ALT (U/L) | 38.5 \pm 6.5* | 2270.6 \pm 313.9 | 278.9 \pm 88.5† |
| AST (U/L) | 72.7 \pm 14.8* | 498.1 \pm 73.0 | 152.2 \pm 18.5† |
| MDA (μ mol/dL) | 1.3 \pm 0.1 | 1.7 \pm 0.1* | 1.3 \pm 0.1 |
| TNF- α (pg/mL) | 32.2 \pm 5.9 | 120.4 \pm 36.7* | 46.8 \pm 9.8 |
| GSH-Px (nmol/min/mL) | 97.2 \pm 39.7 | 37.7 \pm 13.5* | 74.5 \pm 14.5 |

*p < 0.015 vs. other groups; † p < 0.015 vs. Pringle group. Data are presented as mean \pm SD. ALT — alanine aminotransferase, AST — aspartate aminotransferase, MDA — malondialdehyde, TNF- α — tumor necrosis factor alpha, GSH-Px — glutathione peroxidase

Biochemical assays

Serum ALT and AST activities significantly increased in Pringle and infliximab+pringle groups compared with sham group (Table 2). Serum TNF- α and MDA levels were significantly higher in Pringle group compared with sham group. Serum GSH-Px activity was significantly reduced in Pringle group compared with sham group (p < 0.05), and did not differ between the infliximab+pringle group and with sham group (Table 2).

Discussion

This study showed that infliximab pretreatment may inhibit Pringle maneuver-induced injury in epithelial cells of small intestine. We evaluated IR-induced epithelial injury by using scoring system described by Chiu et al. [18], which is commonly used for histopathological grading of intestinal ischemia, and our findings are comparable to current literature [22].

The main histopathological findings in Pringle group were severe degeneration and Casp3 reactivity in the intestinal epithelial cells. These findings are similar to previous reports on ischemic injury following blockade of superior mesenteric artery [20, 23, 24]. As expected, Pringle group showed substantially higher serum TNF- α level. This is consistent with high Casp3 activity and therefore apoptosis was pronounced in this group. Interestingly, TNF- α serum concentration did not differ between infliximab+pringle group compared with sham group which may explain why intensity of Casp3 staining was similar in sham and infliximab + pringle groups. We still observed mild epithelial injury in infliximab + pringle group, however, we also observed cellular regeneration in this group. This suggests that although ischemic period causes cellular degeneration and apoptosis, TNF- α blockage with infliximab prevents further inflammation and degeneration. GSH-Px plays an important role in oxidant/antioxidant balance in the

intestines [25, 26]. As GSH-Px levels were similar in sham and infliximab + pringle groups, in case of TNF- α blockage with infliximab, remaining epithelial cells may regenerate.

It is interesting that intensity of Cn staining was highest in sham group and lowest in Pringle group. It has been demonstrated that Cn induced production of IL-2 which inhibited CD4+CD25 regulatory T cell function [27]. On the other hand, IL-2 is known to induce TNF- α gene expression [28]. As we did not measure the serum or cytosolic calcium levels, and also did not subtype Cn (as CnA and CnB), which are major limitations of our study, we cannot determine whether Cn was associated with proinflammatory or mitotic activity. We hypothesize that since T-cell nuclear factor dephosphorylation and re-phosphorylation occurs as quickly as 15 minutes [29], our reperfusion period of 60 minutes may have been too long to detect a possible change in Cn expression.

MDA is a marker of lipid peroxidation in ischemic tissues [30]. Intensity of MDA staining was the same in sham and infliximab + pringle groups and high in Pringle group. This suggests that administration of infliximab before ischemic period prevented lipid degradation by reactive oxygen species. Serum AST level increased 7-fold in Pringle group but only doubled in infliximab+pringle group. Since AST is a marker of small intestine epithelial cell damage, this data may reflect the inhibitory effect of infliximab on inflammatory epithelial cell injury. Serum ALT level increased 60-fold in Pringle group but only 7-fold in infliximab + pringle group. Since ALT is a marker of liver cell injury, this suggests that infliximab pretreatment alleviated ischemia-reperfusion injury in the liver.

We conclude that infliximab pretreatment significantly attenuates ischemia-reperfusion injury *via* inhibiting TNF- α release. Further studies should investigate the underlying mechanism and evaluate the long-term safety, efficacy and the optimal dosage of infliximab as a protective agent in ischemia-reperfusion injury.

References

- Grace P. Ischaemia-reperfusion injury. *Br J of Surg.* 1994; 81:637–647.
- Jaeschke H. Molecular mechanisms of hepatic ischemia-reperfusion injury and preconditioning. *Am J Physiol Gastrointest Liver Physiol.* 2003;284:G15–G26.
- Glanemann M, Vollmar B, Nussler AK et al. Ischemic preconditioning protects from hepatic ischemia/reperfusion-injury by preservation of microcirculation and mitochondrial redox-state. *J Hepatol.* 2003;38:59–66.
- Vollmar B, Glasz J, Leiderer R et al. Hepatic microcirculatory perfusion failure is a determinant of liver dysfunction in warm ischemia-reperfusion. *Am J Pathol.* 1994;145:1421–1431.
- Kim YI, Ishii T, Aramaki M et al. The Pringle maneuver induces only partial ischemia of the liver. *Hepatogastroenterology.* 1995;42:169–171.
- Kapan M, Gumus M, Onder A et al. The effects of ellagic acid on the liver and remote organs' oxidative stress and structure after hepatic ischemia reperfusion injury caused by pringle maneuver in rats. *Bratisl Lek Listy.* 2012;113:274–281.
- Hirano ES, Mantovani M, Morandin RC et al. Total hepatic ischemia and reperfusion after state controlled hemorrhagic shock, with used of different solutions: effects of neutrophils sequestration in kidney of rats. *Acta Cir Bras.* 2006;21:31–37.
- Jaeschke H. Mechanisms of Liver Injury. II. Mechanisms of neutrophil-induced liver cell injury during hepatic ischemia-reperfusion and other acute inflammatory conditions. *Am J Physiol Gastrointest Liver Physiol.* 2006;290:G1083–1088.
- Porter AG, Janicke RU. Emerging roles of caspase-3 in apoptosis. *Cell Death Differ.* 1999;6:99–104.
- Meier J, Sturm A. Current treatment of ulcerative colitis. *World J Gastroenterol.* 2011;17:3204–3212.
- Di Sabatino A, Ciccocioppo R, Cinque B et al. Defective mucosal T cell death is sustainably reverted by infliximab in a caspase dependent pathway in Crohn's disease. *Gut.* 2004;53:70–77.
- Trent JT, Kerdel FA. Tumor necrosis factor alpha inhibitors for the treatment of dermatologic diseases. *Dermatol Nurs.* 2005;17:97–107.
- Cury DH, Costa JE, Irika K et al. Protective effect of octreotide and infliximab in an experimental model of indomethacin-induced inflammatory bowel disease. *Dig Dis Sci.* 2008;53:2516–2520.
- Dello SA, Reisinger KW, van Dam RM et al. Total intermittent Pringle maneuver during liver resection can induce intestinal epithelial cell damage and endotoxemia. *PLoS One.* 2012;7:e30539.
- Rusnak F, Mertz P. Calcineurin: form and function. *Physiol Rev.* 2000;80:1483–1521.
- Kalkan Y, Tumkaya L, Bostan H et al. Effects of sugammadex on immunoreactivity of calcineurin in rat testes cells after neuromuscular block: a pilot study. *J Mol Histol.* 2012;43:235–241.
- Kalkan Y, Bostan H, Tumkaya L et al. The effect of rocuronium, sugammadex, and their combination on cardiac muscle and diaphragmatic skeletal muscle cells. *J Anesth.* 2012;26:870–877.
- Chiu CJ, McArdle AH, Brown R et al. Intestinal mucosal lesion in low-flow states. I. A morphological, hemodynamic, and metabolic reappraisal. *Arch Surg.* 1970;101:478–483.
- Draper HH, Squires EJ, Mahmoodi H et al. A comparative evaluation of thiobarbituric acid methods for the determination of malondialdehyde in biological materials. *Free Radic Biol Med.* 1993;15:353–363.
- Paglia DE, Valentine WN. Studies on the quantitative and qualitative characterization of erythrocyte glutathione peroxidase. *J Lab Clin Med.* 1967;70:158–169.
- Beutler E. *Red Cell Metabolism: A Manual of Biochemical Methods.* New York: Grune and Stratton; 1975.
- Pergel A, Kanter M, Yucel AF et al. Anti-inflammatory and antioxidant effects of infliximab in a rat model of intestinal ischemia/reperfusion injury. *Toxicol Ind Health.* 2012;28:923–932.
- Takeshita M, Tani T, Harada S et al. Role of transcription factors in small intestinal ischemia-reperfusion injury and tolerance induced by ischemic preconditioning. *Transplant Proc.* 2010;42:3406–3413.
- Vollmar B, Menger MD. Intestinal ischemia/reperfusion: microcirculatory pathology and functional consequences. *Langenbecks Arch Surg.* 2011;396:13–29.
- Aw TY. Determinants of intestinal detoxication of lipid hydroperoxides. *Free Radic Res.* 1998;28:637–646.
- Yao J, Wang JY, Liu L et al. Anti-oxidant effects of resveratrol on mice with DSS-induced ulcerative colitis. *Arch Med Res.* 2010;41:288–294.
- Zeiser R, Nguyen VH, Beilhack A et al. Inhibition of CD4+CD25+ regulatory T-cell function by calcineurin-dependent interleukin-2 production. *Blood.* 2006;108:390–399.
- Strieter RM, Remick DG, Lynch JP, 3rd et al. Interleukin-2-induced tumor necrosis factor-alpha (TNF-alpha) gene expression in human alveolar macrophages and blood monocytes. *Am Rev Respir Dis.* 1989;139:335–342.
- Loh C, Shaw KT, Carew J et al. Calcineurin binds the transcription factor NFAT1 and reversibly regulates its activity. *J Biol Chem.* 1996;271:10884–10891.
- Karabulut AB, Kafkasli A, Burak F et al. Maternal and fetal plasma adenosine deaminase, xanthine oxidase and malondialdehyde levels in pre-eclampsia. *Cell Biochem Funct.* 2005;23:279–283.

Submitted: 12 March, 2013

Accepted after reviews: 28 March, 2014