

## CASE REPORT

### TAENIA INFESTATION IN THE APPENDIX: A CASE REPORT

Aysegul Copur Cicek<sup>1</sup>, Ibrahim Sehitoglu<sup>2</sup> and Saliha Eksi<sup>1</sup>

<sup>1</sup>Department of Medical Microbiology, <sup>2</sup>Department of Medical Pathology, Faculty of Medicine, Recep Tayyip Erdogan University, Rize, Turkey

**Abstract.** *Taenia saginata* is a zoonotic cestode causing taeniasis. Taeniasis refers to the intestinal infection with the adult stage of this tapeworm. An association between taeniasis and acute appendicitis is uncommon. We present the case of a 37 year old male who presented with abdominal pain for one day. He was diagnosed with having appendicitis and an appendectomy was performed. Pathology of the appendix showed *Taenia saginata* with eggs in the lumen. Histological analysis showed acute inflammation consistent with acute appendicitis caused by *T. saginata*.

**Keywords:** *Taenia saginata*, appendicitis, taeniasis

#### INTRODUCTION

*Taenia saginata*, more commonly known as beef tapeworm, is a zoonotic cestode that causes taeniasis. *Taenia saginata* requires a cow as an intermediate host but humans are the only definitive hosts for the adult stage of the parasite. Adult tapeworms infest the human small intestine where they attach to the mucosa to absorb food from the host. Adult worms can reach a length of 4 to 6 meters and survive for as long as 25 years in the definitive host (Beaver and Jung, 1985; Ozcel, 2007). Taeniasis occurs worldwide and is relatively more common in developing

countries where raw or undercooked meat with cysticercus bovis (larval stage) is consumed as part of traditional food cultures (Beaver and Jung, 1985; Ozcel, 2007). Once the cysticercus bovis, the larval stage, is ingested, the larval worm excysts in the small intestine and develops into an adult within two months, then the scolex attaches itself to the intestinal mucosa to initiate infection. Most people with a light infection are asymptomatic or have minor complications lasting years. With fairly heavy infections, people may have allergic reactions, constipation, diarrhea, dizziness, nausea, weight loss, irritation of the intestine and stomach ache (Beaver and Jung, 1985; Ozcel, 2007). The most common symptom is the presence of proglottids being passed in the feces (Beaver and Jung, 1985; Ozcel, 2007). Rarely, the worm can cause intestinal obstruction (Bordon, 1992; Karanikas *et al*, 2007), colonic anastomotic leakage (Sozutek *et al*, 2011) and

---

Correspondence: Dr Aysegul Copur Cicek, Department of Medical Microbiology, Faculty of Medicine, Recep Tayyip Erdogan University, 53100 Rize, Turkey.

Tel: +90 4642123009 ext 3207; Fax: +90 464 2123015

E-mail: draysegulcicek@yahoo.com

individual proglottids may migrate into the appendix causes acute appendicitis by blocking the appendiceal lumen (Sartorelli *et al*, 2005; Silva *et al*, 2007; Karatepe *et al*, 2009). Few cases of *T. saginata* infestation of the appendix have been reported (Lejbkowitz *et al*, 2002).

### CASE REPORT

A 37 year old male presented to our emergency department with a one day history of abdominal pain. On examination he had right lower quadrant tenderness without any other symptoms or fever. The patient was diagnosed with having appendicitis and he underwent an explorative appendectomy. Pathology of the appendix showed inflammation. Histopathology of the appendix showed a gravid *T. saginata* worm, free *T. saginata* eggs and fecal matter in the appendix (Figs 1, 2). There was diffuse inflammation covering the appendix and eosinophils (consistent with parasite infection) and neutrophils in the appendiceal wall (Fig 3). These findings are consistent with acute suppurative appendicitis and parasite infestation. Albendazole (400mg daily for 3 day) was administered to the patient at discharge.

### DISCUSSION

Acute appendicitis, characterized by inflammation

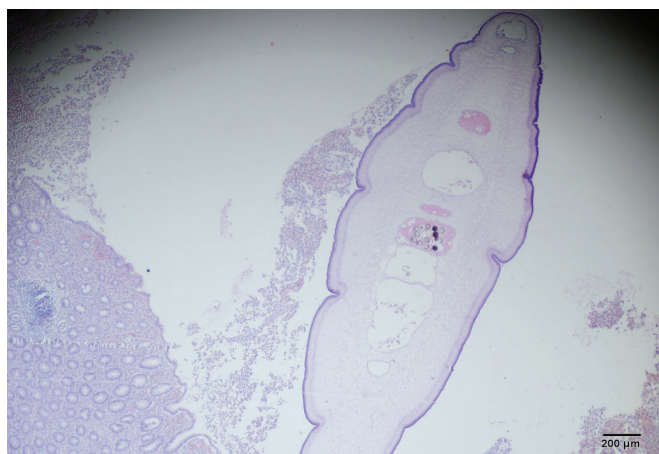


Fig 1–*T. saginata* uterus in the appendix lumen containing eggs (hematoxylin and eosin stain, X40).

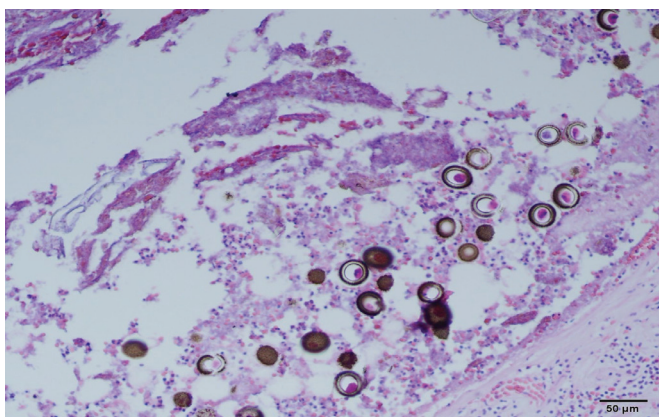


Fig 2–Tapeworm eggs in the appendix lumen (hematoxylin and eosin stain, X200).

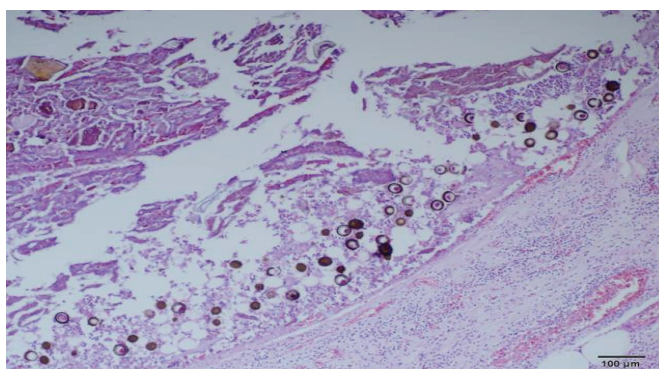


Fig 3–Tapeworm eggs in the appendix lumen, showing acute inflammation in the appendix wall with eosinophils and neutrophils (hematoxylin and eosin stain, X100).

of the appendix, is a common cause of abdominal emergency and one of the most common surgical diseases in people ages 10 to 20 years. Information about the causes of and pathogens found in this disease is limited (Aydin, 2000). The causes of acute appendicitis are probably multifactorial and may include: genetic factors, foreign bodies, fecal material, abdominal trauma, bacterial infection, lymphadenitis and obstruction of the appendix lumen (Carr and Path, 2000); a small percentage of cases may be due to intestinal worms (Waseem and Simha, 2011). The role of parasites in acute appendicitis is poorly understood (Waseem and Simha, 2011). One study found 1.5% of acute appendicitis cases were caused by parasites (Silva *et al*, 2007). Some parasites, especially worms, can accidentally enter the appendix. It is unclear why *Enterobius vermicularis* and *Schistosoma haematobium* enter the appendix (Okolie *et al*, 2008). *Enterobius vermicularis* is the most common nematode located predominantly in the cecum, appendix and colon and is the most common parasite associated with acute appendicitis (Aydin, 2007; Kazemzadeh *et al*, 2008; Okolie *et al*, 2008). Taeniasis is an uncommon cause of appendicitis and few cases have been described in the literature (Lejbkowitz *et al*, 2002; Sartorelli *et al*, 2005; Silva *et al*, 2007). *T. saginata* is one of the most common helminthes located predominantly in the human intestinal tract causing important medical and social problems, especially in developing countries (Sartorelli *et al*, 2005). Adult worms live in the proximal part of the small intestine without causing any serious symptoms (Beaver and Jung, 1985; Ozcel, 2007). However, in heavy worm infections, proglottids of the parasite may migrate to the pancreas, liver and less commonly into the appendix

(Beaver and Jung, 1985; Ozcel, 2007). The most common symptoms with taeniasis are abdominal discomfort, epigastric pain, vomiting and diarrhea (Beaver and Jung, 1985; Ozcel, 2007). *T. saginata* associated acute appendicitis may occur as a result of the worm proglottids (ova) entering the appendix (Lejbkowitz *et al*, 2005; Dorfman *et al*, 1995, 2003). However, some cases are reported in the literature where the parasite may be present in the lumen of the appendix (Dorfman *et al*, 1995; Lejbkowitz *et al*, 2002; Dorfman *et al*, 2003).

We report here a case of acute appendicitis caused by *T. saginata*. Further studies are necessary to determine the role of parasites in the pathogenesis of acute appendicitis.

#### REFERENCES

- Aydin O. Incidental parasitic infestations in surgically removed appendices: a retrospective analysis. *Diag Pathol* 2007; 2: 16.
- Beaver PC, Jung RC. Animal agents and vectors of human disease. 5<sup>th</sup> ed. Philadelphia: Lea&Febiger, 1985: 110-26.
- Bordon LM. Intestinal obstruction due to *Taenia saginata* infection: a case report. *J Trop Med Hyg* 1992; 95: 352-3.
- Carr NJ, Path MRC. The pathology of acute appendicitis. *Ann Diag Pathol* 2000; 4: 46-56.
- Dorfman S, Cardozo J, Dorfman D, Villar DA. The role of parasites in acute appendicitis of pediatric patients. *Invest Clin* 2003; 44: 337-40.
- Dorfman S, Talbot IC, Torres R, Cardozo J, Sanchez M. Parasitic infestation in acute appendicitis. *Ann Trop Med Parasitol* 1995; 89: 99-101.
- Karatepe O, Adas G, Tukenmez M, Battal M, Altioek M, Karahan S. Parasitic infestation as cause of acute appendicitis. *G Chir* 2009; 30: 426-8.
- Karanikas ID, Sakellaridis TE, Alexiou CP,

- Siaperas PA, Fotopoulos AC, Antsaklis GI. *Taenia saginata*: a rare cause of bowel obstruction. *Trans R Soc Trop Med Hyg* 2007; 101: 527-8.
- Kazemzadeh H, Afshar-Moghadam N, Meamar AR, Rahimi HR, Kia EB. *Enterobius vermicularis* and the appendix: report of five cases. *Iranian J Parasitol* 2008; 3: 54-5.
- Lejbkowicz F, Abel AB, Tsilman B, Cohen HI. *Taenia* infestation in the appendix: a report of two cases. *J Med Microbiol* 2002; 51: 90-1.
- Okolie BI, Okonko IO, Ogun AA, *et al.* Incidence and detection of parasite ova in appendix from patients with appendicitis in south-eastern, Nigeria. *World J Agric Sci* 2008; 4: 795-802.
- Ozcel MA. Medical parasitic diseases. Izmir, Turkey: Meta Press, 2007: 692-708 (in Turkish).
- Sartorelli AC, Silva MG, Rodrigues MAM, Silva RJ. Appendiceal taeniasis presenting like acute appendicitis. *Parasitol Res* 2005; 97: 171-2.
- Sozutek A, Colak T, Dag A, Turkmenoglu O. Colonic anastomosis leakage related to *Taenia saginata* infestation. *Clinics* 2011; 66: 363-4.
- Silva DF, Silva RJ, Silva MG, Sartorelli AC, Rodrigues MAM. Parasitic infection of the appendix as a cause of acute appendicitis. *Parasitol Res* 2007; 102: 99-102.
- Waseem M, Simha S. Appendicitis: a rare cause. *J Emergency Med* 2011; 41: 9-11.