

Investigation and Histopathological Evaluation of the Effects of Omeprazole on the Ischemia-Reperfusion Induced Oxidative Damage and DNA Mutation in Rat Ovarian Tissue

ISMAIL DEMIRYILMAZ¹, NIHAL CETIN², OMER ERKAN YAPCA³, DURDU ALTUNER⁴,
UNAL ISAOGLU⁵, FATMA BETUL OZGERIS⁶, MUHAMMET CALIK⁷ and HALIS SULEYMAN^{2,*}

¹Department of General Surgery, Ibbi Sina Hospital, Kayseri, Turkey

²Department of Pharmacology, Faculty of Medicine, Ataturk University, Erzurum, Turkey

³Obstetrics and Gynecology Department, Sorgun State Hospital, Yozgat, Turkey

⁴Department of Pharmacology, Faculty of Medicine, Rize University, Rize, Turkey

⁵Department of Obstetrics and Gynecology, Nene Hatun Obstetrics and Gynecology Hospital, Erzurum, Turkey

⁶Department of Biochemistry, Faculty of Medicine, Ataturk University, Erzurum, Turkey

⁷Department of Pathology, Faculty of Medicine, Ataturk University, Erzurum, Turkey

*Corresponding author: Tel: +90 44 22316558; E-mail: halis.suleyman@gmail.com

(Received: 5 June 2012;

Accepted: 11 March 2013)

AJC-13109

In this study, the biochemical and histopathological effects of omeprazole on ischemia-reperfusion (I/R) induced oxidative damage in rat ovarian tissue were investigated. The moment that the animals remained motionless in supine position was considered the appropriate time to perform surgery. The ovaries of the rats were reached through a 2.0-2.5 cm long vertical incision in the lower abdomen. Subsequently, in the omeprazole (OIR) and the control groups (I/RC), a vascular clip was placed in the lower part of the right ovary (the part where the ovary is attached to the uterus) and ischemia was maintained for 3 h. (No ischemia was applied in the healthy group.) After this period, the vascular clip was removed in order to provide reperfusion for 2 h. Afterwards, all the animals were terminated by high dose-anesthesia, the ovaries were removed and histopathological and biochemical studies were performed. Omeprazole has an antioxidant effect and it can have a protective function in the oxidative damage induced by ischemia-reperfusion. We have found that omeprazole prevents oxidative damage due to ischemia-reperfusion injury in rat ovarian tissue.

Key Words: Omeprazole, Oxidative damage, Ischemia-reperfusion, Rat.

INTRODUCTION

Ovarian ischemia is usually caused by ovarian torsion, which leads to the obstruction of the ovarian artery and the ovarian vein. Ovarian ischemia is an emergency with an indication for acute intervention^{1,2}. Though it can be encountered at all ages in women, it is more frequently seen in the premenarche and in the reproductive period³. In the case of late diagnosis and clinical necrosis, ovariectomy is the treatment of choice⁴. However, in children, in order to preserve the ovaries, even in cases with severe impairment of the circulation, it is advised to reperfuse the ovaries by means of detorsion⁵⁻⁷.

However, contrary to the expectations of tissue perfusion, the reperfusion aggravates the effects of the ischemic damage⁸. This phenomenon, known as reperfusion damage, is initiated by the formation of free oxygen radicals⁹. For this reason, free oxygen radicals are known as the mediators of the reperfusion damage¹⁰. The mediators of the reperfusion damage (the free oxygen radicals) oxidate the cell membrane lipids and cause

formation of toxic products such as aldehydes and malondialdehyde (MDA)¹¹. The free oxygen radicals react not only with the lipids, but also with DNA resulting in the formation of 8-hydroxyguanine (8-OHGua) which is mutagenic¹². In addition, MDA, which is the last product of the lipid peroxidation, is also thought to cause DNA mutation^{13,14}. Glutathione (GSH) and other enzymatic and non-enzymatic antioxidants are of vital importance in the protection of tissues from oxidative stress, but when the antioxidant defense mechanisms fail, serious tissue injury occurs¹⁵. These data indicate that antioxidant therapy may be useful in the treatment of I/R damage.

The drug we used in this experiment was omeprazole, which is a proton pump inhibitor and an antiulcer agent. It has been shown *in vivo* experiments in rats that omeprazole inhibits the production of MDA, which is a lipid peroxidation product and elevates the GSH levels. This results in its gastro protective effect¹⁶. These findings suggest that omeprazole has an antioxidant effect and it can have a protective function in the

oxidative damage induced by ischemia-reperfusion (I/R). In the literature search, we found no data about the protective function of omeprazole in oxidative damage induced by I/R.

The aim of this study was to investigate the biochemical and histopathological effects of omeprazole on the ischemia-reperfusion induced oxidative stress and DNA mutation in rat ovarian tissue.

EXPERIMENTAL

In this study, 18 Wistar albino female rats of 210-225 g were used which were supplied from Atatürk University Medical Application and Research Center. The animals were kept in groups at room temperature (22 °C) and were fed.

The chemical substances used for the experiments, thiopental sodium was provided by IE Ulagay-Turkey. Omeprazole was obtained from Ilsan-Iltas-Turkey.

Procedure: The surgical interventions on rats were performed in laboratories, under sterile conditions, using thiopental (25 mg/kg intra-peritoneal) sodium anesthesia. Before 1 h, the thiopental sodium anesthesia, one group of rats (N = 6) was given omeprazole 20 mg/kg orally. In the control group (N = 6) and the group of healthy rats (N = 6), distilled water was injected *via* the same way. After thiopental sodium injection, the rats were kept until the appropriate moment for surgical intervention. The moment that the animals remained motionless in supine position was considered the appropriate time to perform surgery. The ovaries of the rats were reached through a 2.0-2.5 cm-long vertical incision in the lower abdomen. Subsequently, in the omeprazole (OIR) and the control groups (I/RC), a vascular clip was placed in the lower part of the right ovary (the part where the ovary is attached to the uterus) and ischemia was maintained for 3 h. (No ischemia was applied in the healthy group.) After this period, the vascular clip was removed in order to provide reperfusion for 2 h. Afterwards, all the animals were terminated by high dose-anesthesia, the ovaries were removed and histopathological and biochemical studies were performed. The results of the omeprazole group were compared with the results of the I/RC and SSG groups¹⁷.

Biochemical analysis of ovarian tissue: To perform this experiment, 0.2 g of whole ovarian tissue was weighed for each ovary. The samples were homogenized in ice with 2 mL buffers consisting of 1.15 % potassium chloride solution for malondialdehyde analysis and pH = 7.5 phosphate buffer for the other analyses. Then, they were centrifuged at 4 °C, 10,000 rpm for 15 min. The supernatant part was used as the analysis sample. For all the measurements the tissue-protein estimation was performed according to Bradford's method¹⁸.

Malondialdehyde (MDA) analysis: The concentrations of ovarian lipid peroxidation were determined by estimating MDA using the thiobarbituric acid test¹⁹. The rat ovaries were rinsed with cold saline. The corpus mucosa was scraped, weighed and homogenized in 10 mL of 100 g/L KCl. The homogenate (0.5 mL) was added to a solution containing 0.2 mL of 80 g/L sodium lauryl sulphate, 1.5 mL of 200 g/L acetic acid, 1.5 mL of 8 g/L 2-thiobarbiturate and 0.3 mL distilled water. The mixture was incubated at 98 °C for 1 h. Upon cooling, 5 mL of *n*-butanol:pyridine (15:1) was added.

The mixture was vortexed for 1 min and centrifuged for 0.5 h at 4000 rpm. The absorbance of the supernatant was measured at 532 nm. The standard curve was obtained by using 1,1,3,3-tetramethoxypropane.

Total glutathione (tGSH) analysis: The amount of GSH in the total homogenate was measured according to the method of Sedlak and Lindsay with some modifications²⁰. The sample was weighed and homogenized in 2 mL of 50 mM Tris-HCl buffer containing 20 mM EDTA and 0.2 mM sucrose at pH 7.5. The homogenate was immediately precipitated with 0.1 mL of 25 % trichloroacetic acid and the precipitate was removed after centrifugation at 4200 rpm for 40 min at 4 °C and the supernatant was used to determine GSH level. 1500 µL of measurement buffer (200 mM Tris-HCl buffer containing 0.2 mM EDTA at pH 7.5), 500 µL supernatant, 100 µL DTNB (10 mM) and 7900 µL methanol were added to a tube and vortexed and incubated for 0.5 h in 37 °C. 5,5-Dithiobis(2-nitrobenzoic acid) (DTNB) was used as a chromogen and it formed a yellow-coloured complex with SH groups. The absorbance was measured at 412 nm using a spectrophotometer. The standard curve was obtained by using reduced glutathione.

Isolation of DNA from ovarian tissue: Ovarian tissue was drawn and DNA isolated using Shigenaga *et al.*'s modified method²¹. Samples (for ovarian tissue 50 mg) were homogenized at 4 °C in 1 mL of homogenization buffer (0.1 M NaCl, 30 mM Tris, pH 8.0, 10 mM EDTA, 10 mM 2-mercaptoethanol, 0.5 % (v/v) Triton X-100) with 6 passes of a Teflon-glass homogenizer at 200 rpm. The samples were centrifuged at 4 °C for 10 min at 1000 g to pellet nuclei. The supernatant was discarded and the crude nuclear pellet re-suspended and re-homogenized in 1 mL of extraction buffer (0.1 M Tris, pH 8.0, 0.1 M NaCl, 20 mM EDTA) and re-centrifuged as above for 2 min. The washed pellet was re-suspended in 300 µL of extraction buffer with a wide orifice 200 µL Pipetman tip. The re-suspended pellet was subsequently incubated at 65 °C for 1 h with the presence of 0.1 mL of 10 % SDS, 40 µL proteinase K and 1.9 mL leukocyte lysis buffer. Then, ammonium acetate was added to the crude DNA sample to give a final concentration of 2.5 mol/L and centrifuged in a micro centrifuge for 5 min. The supernatant was removed and mixed with two volumes of ethanol to precipitate the DNA fraction. After centrifugation, the pellet was dried under reduced pressure and dissolved in sterile water. The absorbance of this fraction was measured at 260 and 280 nm. Purification of DNA was determined as A 260/280 ratio 1.8.

DNA hydrolysis with formic acid: About 50 mg of DNA was hydrolyzed with 0.5 mL of formic acid (60 %, v/v) for 45 min at 150 °C²². The tubes were allowed to cool. The contents were then transferred to Pierce micro-vials, covered with Kleenex tissues cut to size (secured in place using a rubber band) and cooled in liquid nitrogen. Formic acid was then removed by freeze-drying. Before analysis by HPLC, they were re-dissolved in the eluent (final volume 200 µL).

Measurement of 8-OH Gua with high performance liquid chromatography (HPLC) system: The amount of 8-OH Gua and guanine (Gua) was measured by using a HPLC system equipped with an electrochemical detector (HP Agilent 1100 module series, ECD HP 1049 A), as described previously^{22,23}.

The amount of 8-OHGua and Gua was analyzed on a 250 4.6 mm Supelco LC-18-S reverse-phase column. The mobile phase was 50 mM potassium phosphate, pH 5.5, with acetonitrile (97 volume acetonitrile and 3 volume potassium phosphate) and the flow rate was 1.0 mL/min. The detector potential was set at 0.80 V for measuring the oxidized base. Gua and 8-OHGua (25 pmol) were used as standards. The 8-OHGua levels were expressed as the number of 8-OHGua molecules/105 Gua molecules²⁴.

Histological examination: At the end of each experiment the ovaries were removed and fixed in 10 % neutral buffered formalin solution and then embedded in paraffin as usual. Serial sections were cut using the microtome at a thickness of 4 μ m and stained with hematoxylin and eosin. The histologic sections were examined for the presence of interstitial edema, vascular dilatation, hemorrhage and polymorphonuclear neutrophilic (PMN) infiltrations, using a microscope Olympus BX-50 with a microscope and photograph.

RESULTS AND DISCUSSION

Biochemical results: As seen in Table-1, the MDA level in the I/RC group was 5.9 ± 0.14 μ mol/g protein and the GSH level was 1.1 ± 0.09 nmol/g protein; whereas the MDA and GSH levels in the OIR group were, respectively 2.5 ± 0.1 ($p < 0.0001$) μ mol/g protein and 3.3 ± 0.12 ($p < 0.0001$) nmol/g protein. In the SSG group, these values were, respectively 2.7 ± 0.11 ($p < 0.0001$) μ mol/g protein and 3.1 ± 0.13 ($p < 0.0001$) nmol/g protein and 8-OHGua levels in the rat ovarian tissue in the I/RC, OIR and SSG groups were, respectively 1.3 ± 0.1 , 0.44 ± 0.07 ($p < 0.0001$) and 0.49 ± 0.09 ($p < 0.0001$) pmol/L.

TABLE-1

EFFECT OF OMEPRAZOLE ON THE AMOUNT OF 8-OH Gua, MDA AND GSH LEVELS IN OVAR TISSUE AFTER IR. I/RC: ISCHEMIA/REPERFUSION CONTROL GROUP, OIR: OMEPRAZOLE RECEIVED ISCHEMIA/REPERFUSION GROUP AND SSG: SHAM SURGERY GROUP. RESULTS ARE THE MEANS \pm STANDARD ERROR OF THE MEAN (N = 6)

Groups	MDA (μ mol/g protein)	GSH (μ mol/g protein)	8-OHGua (pmol/L)
I/RC	5.9 ± 0.14	1.1 ± 0.09	1.3 ± 0.1
P	–	–	–
OIR	2.5 ± 0.1	3.3 ± 0.12	0.44 ± 0.07
P	< 0.0001	< 0.0001	< 0.0001
SSG	2.7 ± 0.11	3.1 ± 0.13	0.49 ± 0.09
P	< 0.0001	< 0.0001	< 0.0001

Histopathological results

Healthy rat ovarian tissue: As seen in Fig. 1, the histopathological examination of the healthy animal group with the SHAM operation revealed a mild edema and mild vascular congestion.

Rat ovarian tissue of the OIR group: In the OIR group with omeprazole + ischemia/reperfusion, a mild edema and mild vascular congestion were observed (Fig. 2).

Rat ovarian tissue of the IRC group: In the IRC group with omeprazole + ischemia/reperfusion, severe edema and vascular congestion, hemorrhage and leucocyte infiltration were observed (Fig. 3).

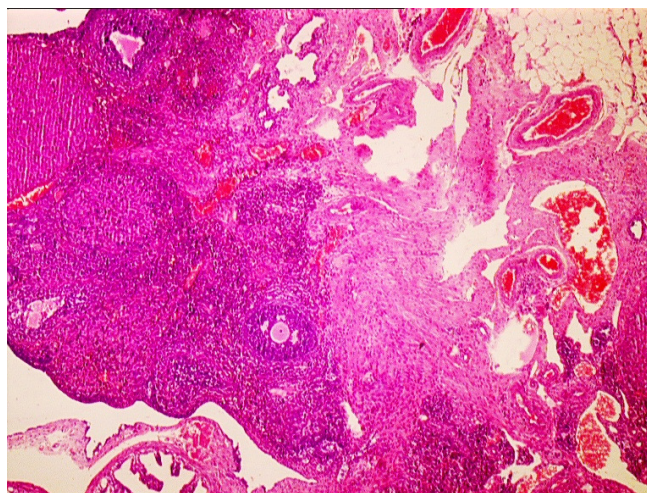


Fig. 1. Histopathological examination of the healthy animal group with the Sham operation revealed a mild edema and mild vascular congestion

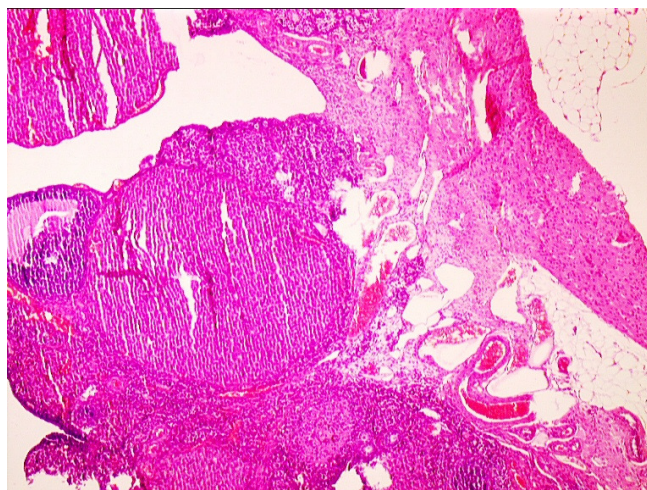


Fig. 2. OIR group with omeprazole + ischemia/reperfusion, a mild edema and mild vascular congestion were observed

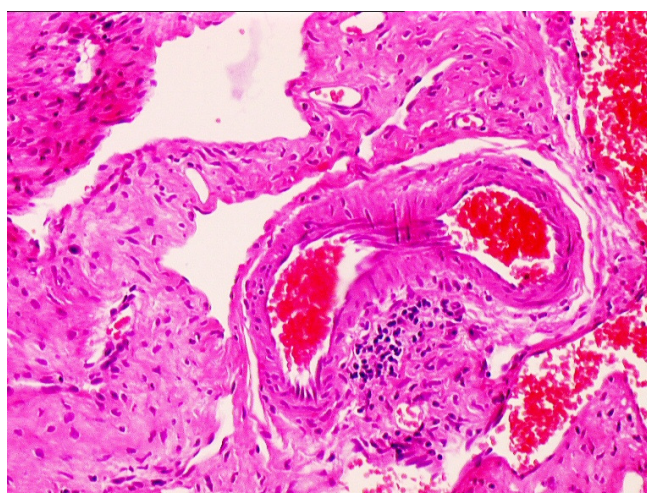


Fig. 3. I/RC group with ischemia/reperfusion, severe edema and vascular congestion, hemorrhage and leucocyte infiltration were observed

In this study, the biochemical and histopathological effects of omeprazole on the ischemia-reperfusion (I/R) induced oxidative damage in rat ovarian tissue were investigated and

the histopathological effects were evaluated. Oxidative stress is a serious disproportion of the formation of free oxygen radicals and antioxidant defense mechanisms²⁵. The increased lipid peroxidation during reperfusion (LPO) is a result of the attack of OH radicals on the cell membrane fatty acid side chains¹¹. The membrane injury formed by LPO is irreversible²⁶. Lipid peroxidation during reperfusion is initiated by the formation of the carbon-based -CH- lipid radical. This lipid radical interacts with molecular oxygen and forms the lipid peroxy radical. The lipid peroxy radicals unite with H and transform to lipid hydroperoxides and this causes the initiation of a spontaneous chain reaction²⁷. The most commonly known aldehydes formed because of LPO are MDA and 4-hydroxynonenal. Lipid peroxidation during reperfusion can be evaluated by determining the MDA. The peroxy radicals and the MDA can cause cross-linking and the polymerization of the membranes and membrane components and lead to serious injury in these structures^{28,29}. The LPO reaction is either terminated by the collecting antioxidant reactions, or continues with the autocatalytic diffusion reactions³⁰. In our study, the MDA levels in the rat ovarian tissue of the OIR group were lower than in the IRC group. This difference was statistically significant. This result indicates that omeprazole inhibits the autocatalytic diffusion reactions that are induced by I/R damage. It has been reported that the MDA levels increase parallel to the extent of the tissue damage in various tissues³¹. These findings are in concordance with our results.

Furthermore, we have found lower levels of GSH levels in the I/R group, compared to OIR and SSG. This suggests that in the I/R group the oxidant-anti-oxidant balance has changed in favour of the oxidants. Furthermore, this indicates that the endogenous anti-oxidant mechanisms are insufficient for the elimination of the I/R damage. In order to eliminate the I/R damage, there is a need for accessory exogenous mechanisms to change the oxidant-antioxidant balance in favour of the antioxidants. The administration of omeprazole seems to change the balance in favour of the antioxidants. As known, there are enzymatic and non-enzymatic defense mechanisms in the body. The de-oxidation operations carried out with endogenous GSH are defined as the non-enzymatic defense mechanisms³². Antioxidant defense is described as scavenging free radicals, prevention of their production, stopping chain reactions, repair of cell damage and an increase in the endogenous anti-oxidant capacity³⁰. The higher GSH amount in the OIR group compared to the I/R group indicates that omeprazole increases the endogenous anti-oxidant capacity.

Glutathione is an important endogenous antioxidant, which has a role in DNA and protein synthesis, in the regulation of the enzyme activities and against oxidative stress^{33,34}. There are experimental studies which show that in the damaged tissue, the GSH levels and other antioxidant parameters are decreased and MDA levels increase³⁵. It has been experimentally demonstrated that reperfusion.

Following ischemia lead to severe injury not only in ovaries but also in the different tissues^{36,37}. It was demonstrated that antioxidant activity is important for repair of tissue damage³⁸. The excessive production of free oxygen radicals causes serious damage, not only in the lipids but also in the DNA. It has been

advocated that the reaction of the nucleic acids with ROS result in DNA mutation and in cell death^{13,14}. Another cause of DNA damage is the formation of the OH^{*} radicals because of the reaction of H₂O₂ with Fe-Cu ions in the nucleus. Furthermore, because the DNA consists of a large number of negatively loaded phosphate groups, it is bonded to the positively loaded metal ions such as Fe^{2+/3+} and Cu^{1+/2+}³⁹. These metal ions that are bonded to DNA react with the H₂O₂ in the nucleus causing the formation of toxic radicals, such as OH^{*}, on the DNA and oxidative damage⁴⁰. Because of the damage of the OH^{*} and O₂ radicals on DNA, mutagenic DNA, such as 8-OHGua and FAPyGuanin (FAPyG), is formed⁴¹. Due to its strong oxidizing effects, the superoxide anion reacts easier with molecules with areas containing a high density of electrons, such as Gua⁴².

We found high levels in the IRC control group rat ovarian tissue, in which the MDA levels were also high. The results of biochemical analyses in ovarian tissue are supported by the histopathological findings. In the IRC group, severe edema and vascular congestion, hemorrhage and leucocyte infiltration were observed. Histopathologically, the ovarian tissue in the OIR group had almost the same characteristics as the SSG group (mild edema and vascular congestion). The increased vascular permeability and neutrophils are considered to be responsible for the edema in the I/R injury⁴³. Furthermore, PMNL have the capacity to produce SOR in large amounts⁴⁴. There are studies reporting that the degree of neutrophil activation and tissue infiltration has a correlation with the severity of the reperfusion injury⁴⁵. These data are also in concordance with our findings.

Conclusion

It is found that omeprazole prevents oxidative damage due to ischemia-reperfusion injury in rat ovarian tissue.

REFERENCES

1. A.I. Bayer and A.K. Wiskind, *Am. J. Obstet Gynecol.*, **171**, 1506 (1994).
2. M. Beaunoyer, J. Chapdelaine, S. Bouchard and A. Ouimet, *J. Pediatr. Surg.*, **39**, 746 (2004).
3. L.T. Hibbard, *Am. J. Obstet. Gynecol.*, **152**, 456 (1985).
4. A.J. Davis and N.R. Feins, *J. Pediatr. Surg.*, **25**, 687 (1990).
5. J.E. Pena, D. Ufberg, N. Cooney and A.L. Denis, *Fertil. Steril.*, **73**, 1047 (2000).
6. A. Rody, C. Jackisch, W. Klockenbusch, J. Heinig, V. Coenen-Worch and H.P. Schneider, *Eur. J. Obstet. Gynecol. Reprod. Biol.*, **101**, 83 (2002).
7. V. Rousseau, R. Massicot, A.A. Darwish, F. Sauvat, S. Emond, E. Thibaud and C. Nihoul-Fekete, *J. Pediatr. Adolesc. Gynecol.*, **21**, 201 (2008).
8. P.A. Grace, *Br. J. Surg.*, **81**, 637 (1994).
9. G.L. Semenza, *Circ. Res.*, **86**, 117 (2000).
10. E. Lin, S.F. Lowry and S.E. Calvano, in eds.: S.I. Schwartz, G.T. Shires and F.C. Spencer, *The Systematic Response to Injury*, In Principles of Surgery, McGraw Hill, New York, edn 7 (1999).
11. R.F. Del Maestro, *Acta Physiol. Scand. Suppl.*, **492**, 153 (1980).
12. L.J. Marnett, *Carcinogenesis*, **21**, 361 (2000).
13. B. Epe, D. Ballmaier, W. Adam, G.N. Grimm and C.R. Saha-Moller, *Nucl. Acids Res.*, **24**, 1625 (1996).
14. L.J. Marnett, *Toxicology*, **27**, 181 (2002).
15. I.S. Young and J.V. Woodside, *J. Clin. Pathol.*, **54**, 176 (2001).
16. A. Kisaoglu, B. Ozogul, N. Cetyn, B. Suleyman, S. Atamanalp, F. Akcay and H. Suleyman, *Int. J. Pharmacol.*, **7**, 682 (2011).
17. A. Kurt, U. Isaoglu, M. Yilmaz, M. Calik, B. Polat, H. Hakan, M. Ingeç and H. Suleyman, *J. Pediatr. Surg.*, **46**, 1817 (2011).
18. M.M. Bradford, *Anal. Biochem.*, **72**, 248 (1976).
19. H. Ohkawa, N. Ohishi and K. Yagi, *Anal. Biochem.*, **95**, 351 (1979).

20. J. Sedlak and R.H. Lindsay, *Anal. Biochem.*, **25**, 192 (1968).
21. M.K. Shigenaga, E.N. Aboujaoude, Q. Chen and B.N. Ames, *Methods Enzymol.*, **234**, 16 (1994).
22. H. Kaur and B. Halliwell, *Biochem. J.*, **318**, 21 (1996).
23. R.A. Floyd, J.J. Watson, P.K. Wong, D.H. Altmiller and R.C. Rickard, *Free Radic. Res. Commun.*, **1**, 163 (1986).
24. S. Asami, T. Hirano, R. Yamaguchi, Y. Tomioka, H. Itoh and H. Kasai, *Cancer Res.*, **56**, 2546 (1996).
25. M. Serafini and D. Del Rio, *Redox Rep.*, **9**, 145 (2004).
26. K.J. Davies and A.L. Goldberg, *J. Biol. Chem.*, **262**, 8220 (1987).
27. N.V. Georgieva, *Bul. J. Veterinary Med.*, **8**, 1 (2005).
28. M. Goulart, M.C. Batoreu, A.S. Rodrigues, A. Laires and J. Rueff, *Mutagenesis*, **20**, 311 (2005).
29. B. Halliwell and S. Chirico, *Am. J. Clin. Nutr.*, **57**, 715 (1993).
30. J.M. Gutteridge, *Clin. Chem.*, **41**, 1819 (1995).
31. B. Suleyman, Z. Halici, F. Odabasoglu and F. Gocer, *Int. J. Pharmacol.*, **115** (2012).
32. B.P. Yu, *Physiol. Rev.*, **74**, 139 (1994).
33. B. Polat, H. Suleyman and H.H. Alp, *Chem. Biol. Interact.*, **186**, 82 (2010).
34. A. Meister and M.E. Anderson, *Annu. Rev. Biochem.*, **52**, 711 (1983).
35. H. Suleyman, *Eurasian J. Med.*, **44**, 00 (2012).
36. B. Borekci, C. Gundogdu, B.Z. Altunkaynak, M. Calik, M.E. Altunkaynak, D. Unal and B. Unal, *Eurasian J. Med.*, **41**, 22 (2009).
37. A.K. Coskun, A. Gunal, Z. Halici, A. Oral, M. Seyrek, Y. Bayir, C. Kilic, T. Yigit, T. Ozer and A.I. Uzar, *Eurasian J. Med.*, **43**, 33 (2011).
38. F. Celebi, A. Akbas, M.B. Saglam, A. Kisaoglu and H.H. Alp, *Asian J. Chem.*, **24**, 1966 (2012).
39. B. Halliwell and J.M.C. Gutteridge, *Free Radicals in Biology and Medicine*, Oxford University Press (1999).
40. M.S. Cooke, M.D. Evans, M. Dizdaroglu and J. Lunec, *FASEB J.*, **17**, 1195 (2003).
41. J. Cadet, T. Douki, D. Gasparutto and J.L. Ravanat, *Mutat Res.*, **531**, 5 (2003).
42. L. Jornot, H. Petersen and A.F. Junod, *Biochem. J.*, **335**, 85 (1998).
43. F. Lopez-Neblina, A.J. Paez-Rollys and L.H. Toledo-Pereyra, *J. Surg. Res.*, **61**, 469 (1996).
44. H.K. Eltzschig and C.D. Collard, *Br. Med. Bull.*, **70**, 71 (2004).
45. B.J. Zimmerman and D.N. Granger, *Surg. Clin. North Am.*, **72**, 65 (1992).