



Laparoscopic treatment of a phytobezoar in the duodenal diverticulum – Report of a case

Ahmet Pergel*, Ahmet Fikret Yucel, Ibrahim Aydin, Dursun Ali Sahin

Department of Surgery, School of Medicine, Rize University, 53100 Rize, Turkey

ARTICLE INFO

Article history:

Received 4 February 2012

Received in revised form 16 March 2012

Accepted 21 March 2012

Available online 16 April 2012

Keywords:

Duodenal diverticulum

Phytobezoar

Persimmon

Laparoscopic treatment

ABSTRACT

INTRODUCTION: Primer small intestine bezoar is seen rarely. It frequently arises from underlying small intestine pathologies (diverticle, tumor, stricture etc.). We report a very rare case of disopyrobezoar in the duodenal diverticulum, a kind of phytobezoar caused by persimmons, which was treated laparoscopically. **PRESENTATION OF CASE:** The 47-year-old patient applied to polyclinic with complaints of epigastric tenderness, occasional distension, and acid regurgitation. In endoscopic examination, impacted bezoar was determined in the diverticulum in the duodenum. Because it is too hard, it was unable to remove endoscopically. On the abdominal tomography, a smooth-bounded non-homogeneous mass including gas and soft tissue areas in the 2nd portion of the duodenum was detected. A barium meal confirmed the presence of a 5 cm diameter diverticulum on the lateral wall of the second portion of the duodenum. It also showed an intraluminal filling defect as well as the mottled appearance of the bezoar. Learned from history of the patient, that the patient consumed over persimmon in childhood.

DISCUSSION: Generally, duodenal diverticles are asymptomatic. Surgical treatment is rarely necessary because of complications such as bleeding, perforation, abdominal pain, bezoar formation. As well as using methods such as gastric lavage, enzymatic dissolution, endoscopic fragmentation in the treatment of phytobezoar, their chances of success are low because its structure is rigid. Usually, surgical intervention is required.

CONCLUSION: For the treatments of bezoar cases located in the small intestine, laparoscopic surgical method is a safe and feasible method in selected cases.

© 2012 Surgical Associates Ltd. Published by Elsevier Ltd. Open access under [CC BY-NC-ND license](https://creativecommons.org/licenses/by-nc-nd/4.0/).

1. Introduction

Phytobezoars are common bezoars in the gastrointestinal tract.¹ These generally take the form of orange pith or pulp in patients with a history of surgery, or persimmon in patients with no history of previous surgery. Clinical presentations vary with the location of diospyrobezoar from no symptom to signs of obstruction like abdominal distention and pain, acid regurgitation, and vomiting. There are many treatments for intestinal obstruction due to phytobezoar (medical, endoscopic, and surgical).²

2. Presentation of case

A 47-year-old female presented with epigastric tenderness, intermittent epigastric distension, and acid regurgitation. There were no obvious symptoms of gastrointestinal obstruction, e.g. nausea or vomiting. The patient had a long history of overindulgence with persimmons from early childhood and no previous gastric surgery. Her vital signs upon admission were stable with blood pressure of 130/80 mmHg and a heart rate of 80 beats/min.

Blood test results were normal. An endoscopic examination revealed a duodenal diverticulum filled with bezoar. A mouse-teeth clamp and snare was used to fragment the bezoar, but this was unsuccessful because it was too hard and deep seated in the diverticulum. An abdominal computerized tomography (CT) revealed a mass-like lesion within the diverticulum on the lateral wall of the second portion of the duodenum with air bubbles retained in its interstices and a mottled appearance; this evidence was compatible with the features of bezoars (Fig. 1). A barium meal confirmed the presence of a 5 cm diameter diverticulum on the lateral wall of the second portion of the duodenum. It also showed an intraluminal filling defect as well as the mottled appearance of the bezoar (Fig. 2). We decided on a surgical intervention and chose the laparoscopic approach instead of open surgery. A pneumoperitoneum was created by using a Veress needle inserted into the umbilicus. The pneumoperitoneum was established to a maximum pressure of 13 mmHg. A 10-mm trocar was placed in the umbilicus. Two more trocars, 5 mm in diameter, were inserted on the right mid-clavicular line and on the anterior axillary line. One trocar, 15 mm in diameter, was inserted below via the xiphoid process (Fig. 3). The abdominal exploration was performed with a 30° laparoscope and revealed a 5 cm diameter duodenal diverticulum on the lateral side of the second portion of the duodenum. There was also a hard mass palpable with crasper in the diverticulum. The diverticulum

* Corresponding author. Tel.: +90 4642123009; fax: +90 4642123015.

E-mail address: pergelahmet@hotmail.com (A. Pergel).

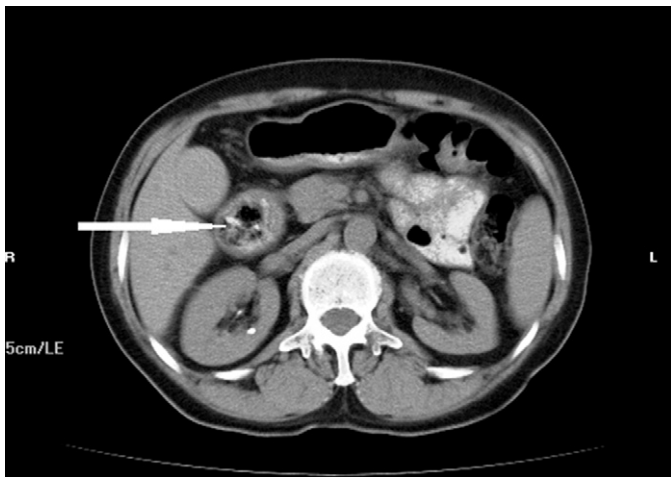


Fig. 1. Contrast-enhanced abdominal CT scan shows a well-defined mass with mottled appearance within diverticulum on the lateral wall of the second portion of the duodenum (arrow).

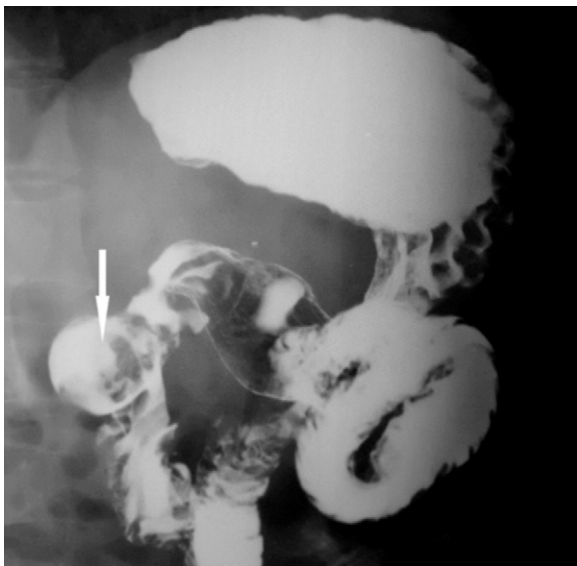


Fig. 2. Barium study shows an intraluminal filling defect of a bezoar in the diverticulum on the lateral wall of the second portion of the duodenum (arrow).

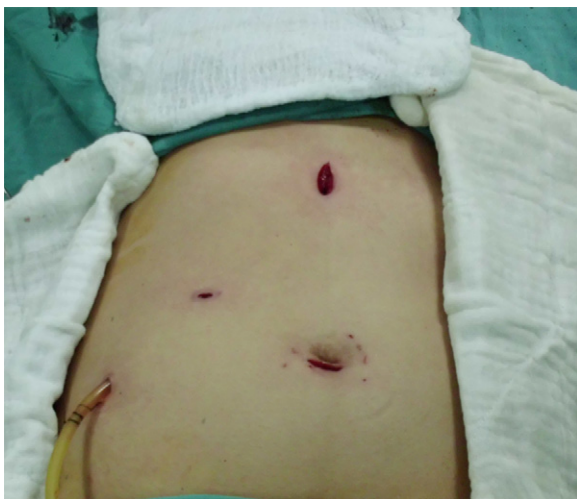


Fig. 3. Trocar positions.

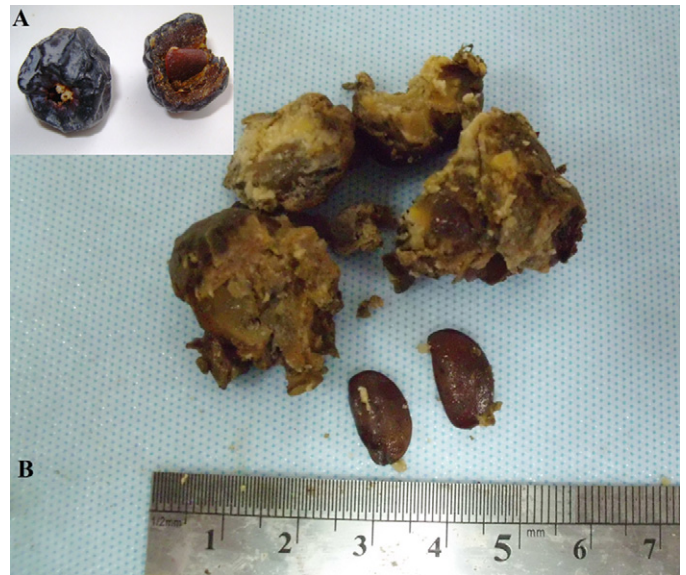

Fig. 4. (A) Image of the persimmon. (B) Image of the persimmon seed in the fragmented bezoar.

was grasped carefully and dissected circumferentially. The dissection was performed toward its neck near the duodenal wall and then a diverticulotomy was done using electrocautery. The phyto-bezoar was extracted in a latex bag (Fig. 4). A 45-mm Endopath EZ (ETHICON) suture stapler was inserted through a 15-mm trocar and used to resect the diverticulum (Fig. 5). A drain was placed in the subhepatic region. The patient was discharged on the seventh postoperative day. At the six-month follow-up, the patient did not complain of any discomfort.

3. Discussion

The duodenum is the second site after the colon in terms of the frequency of diverticula. Duodenal diverticula are found in 15–22% of cases at autopsy and in 1–6% of cases during upper gastrointestinal radiography.³

Duodenal diverticula are generally asymptomatic. Abdominal pain is the most common symptom of the duodenal diverticula. Hemorrhage is also a common symptom. When symptomatic (less than 10%), duodenal diverticula cause upper abdominal pain, bleeding, duodenal obstruction (bezoars, especially in the presence of diverticula) of the main biliary or pancreatic duct, ascending cholangitis, or pancreatitis.⁴ Surgical treatment is rarely indicated for duodenal diverticula and only when a complication emerges

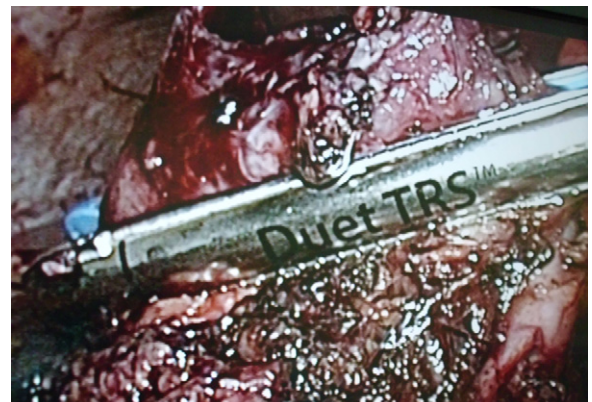

Fig. 5. Resection of diverticulum with an endo stapler.

such as bleeding, a bezoar, and perforations or persistent abdominal pain after the elimination of other causes of pain. Clinical signs vary, depending on the location of the bezoar, from no symptoms to acute abdominal syndrome. In our case, there were complaints of epigastric bloating, pain, and vomiting, especially after meals.⁵

Bezoars are classified according to their content into phytobezoars (vegetables), trichobezoars (hairs), lactobezoars (concentrated milk formulas), mixed-medication bezoars, and food bolus bezoars.^{1,6} Most phytobezoars are composed of indigestible cellulose, tannin, and lignin derived from ingested vegetables and fruits, especially persimmons and pineapples. A diospyrobezoar is a type of phytobezoar caused by persimmons. Although it is a rare occurrence in clinics, it is especially prevalent in Mediterranean countries where persimmons, oranges, and vegetables are commonly ingested.⁶ Previous gastric surgery (disturbance of pyloric function, gastric emptying, and hypoacidity), poor mastication, or overindulgence with foods with a high-fiber content are common factors predisposing bezoar formation. Delayed gastric emptying due to diabetes mellitus, mixed connective tissue disease and hypothyroidism were also reported as factors predisposing bezoar formation. Small intestine bezoars often originate in the stomach.⁷ A gastric bezoar may pass down to the small intestine and cause a small-bowel obstruction. However, small bowel bezoars may occur in small bowel diverticula in a segment of the bowel associated with stricture formation or proximal to a small bowel tumor.^{8,9} In our patient risk factors were diverticulum on the second portion of the duodenum and overindulgence of persimmons.

CT scanning and barium studies are commonly used in the differential diagnosis.¹⁰ Endoscopic investigations can show and confirm almost all gastric bezoars and sometimes duodenal bezoars.¹¹ In our case, CT scanning showed a well-defined, oval, non-homogeneous mass consisting of gas and soft tissue in the second portion of the duodenum. The barium study showed an intraluminal filling defect and contrast material collected around the lesion.

Phytobezoars can be treated in several ways including gastric lavage, enzymatic dissolution, endoscopic disruption, endoscopic procedures, lavage, and conventional and videolaparoscopic surgery. There are a few reports about the successful treatment of phytobezoars by endoscopy or cellulase. Because of phytobezoars' hard consistency, an endoscopic treatment with fragmentation or enzymatic dissolution is difficult and sometimes mechanical fragmentation cannot be successful; hence, phytobezoars are generally removed surgically.⁶ Initially, we tried to endoscopically remove the bezoar located in the diverticulum, but this was not possible because the bezoar was deeply seated in the diverticulum and removal could cause bowel perforation. Two liters of cola a day for three days was prescribed to the patient, but there was no fragmentation in the control endoscopy. At the end of unsuccessful treatment modalities, we decided on surgery.

With the improvement in laparoscopic techniques and experiences, many authors have considered the laparoscopic approach as an alternative to conventional procedures in selected cases of intestinal bezoars. However depending on the localization of the diverticulum, it may be easy or difficult to treat. Juxtapapillary diverticula are more difficult to resect compared to those growing laterally. Juxtapapillary diverticula are more frequently associated with biliary and pancreatic pathologies.² Because the diverticulum

was located on the lateral side of duodenum in our patient, we preferred a laparoscopic approach instead of open surgery.

4. Conclusion

Diospyrobezoar is a rare kind of phytobezoar. It is common, however, in some countries, especially due to overindulgence of persimmons. Barium studies, ultrasonography, CT scan, and endoscopy are helpful in the differential diagnosis. Diospyrobezoars can be treated conservatively, but commonly require surgical intervention. The laparoscopic approach is a feasible method in selected patients for the management of intestinal bezoars when performed by a well-trained and experienced laparoscopic surgeon. A laparoscopic treatment is more feasible for the diverticula on the lateral side of the duodenum.

Conflict of interest

We certify that there is no conflict of interest with any financial organization regarding the material discussed in the manuscript.

Funding

No external funding, apart from the support of the authors' institution, was available for this study.

Ethical approval

Written informed consent was obtained from the patient.

Authors' contributions

Ahmet Pergel: Study design, data collection, and writing; Ahmet Fikret Yucel: Data collection, writing, and correction; Ibrahim Aydin: Correction, writing; and Dursun Ali Sahin: Correction and writing

References

- Erzurumlu K, Malazgirt Z, Bektas A, Dervisoglu A, Polat C, Senyurek G, et al. Gastrointestinal bezoars: a retrospective analysis of 34 cases. *World Journal of Gastroenterology* 2005;**11**:1813–7.
- Yau KK, Siu WT, Law BK, Cheung HY, Ha JP, Li MK. Laparoscopic approach compared conventional open approach for bezoar induced small bowel obstruction. *Archives of Surgery* 2005;**140**:972–5.
- Mathis KL, Farley DR. Operative management of symptomatic duodenal diverticula. *American Journal of Surgery* 2007;**193**:305–9.
- Jang LC, Kim SW, Park YH, Kim JP. Symptomatic duodenal diverticulum. *World Journal of Surgery* 1995;**19**:729–33.
- Scudamore CH, Harrison RC, White TT. Management of duodenal diverticula. *Canadian Journal of Surgery* 1982;**25**:311–4.
- Gáya J, Barranco L, Llompert A, Reyes J, Obrador A. Persimmon bezoars: a successful combined therapy. *Gastrointestinal Endoscopy* 2002;**55**:581–3.
- Krausz MM, Moriel EZ, Ayalon A, Pode D, Durst AL. Surgical aspects of gastrointestinal persimmon phytobezoar treatment. *American Journal of Surgery* 1986;**152**:526–30.
- Lorimer JW, Allen MW, Tao H, Burns B. Small-bowel carcinoid presenting in association with a phytobezoar. *Canadian Journal of Surgery* 1991;**34**:331–3.
- Shocket E, Simon SA. Small bowel obstruction due to enterolith (bezoar) formed in a duodenal diverticulum: a case report and review of the literature. *American Journal of Gastroenterology* 1982;**77**:621–4.
- Yildirim T, Yildirim S, Barutcu O, Oguzkurt L, Noyan T. Small bowel obstruction due to phytobezoar: CT diagnosis. *European Radiology* 2002;**12**:2659–61.
- Blam ME, Lichtenstein GR. A new endoscopic technique for the removal of gastric phytobezoars. *Gastrointestinal Endoscopy* 2000;**52**:404–8.

Open Access

This article is published Open Access at sciedirect.com. It is distributed under the [IJSCR Supplemental terms and conditions](#), which permits unrestricted non commercial use, distribution, and reproduction in any medium, provided the original authors and source are credited.