

Round Ligament Leiomyoma Developing During Pregnancy: A Case Report and Literature Review

Recep BEDİR, Rukiye Yılmaz, İbrahim ŞEHİTOĞLU, Cüneyt YURDAKUL

Dept. of Pathology, Recep Tayyip Erdogan University School of Medicine, Rize, Turkey

KEY WORDS

Leiomyoma
Pregnant
Inguinal mass

ABSTRACT

Round ligament leiomyoma of uterus is rare. It can be presented as inguinal swelling mimicking the inguinal hernia or lymph node. Surgical excision is its curative treatment. Definitive diagnosis is made by histopathological examination. A 32 year old pregnant patient having round ligament leiomyoma as diagnosed histopathologically in Recep Tayyip Erdogan University Hospital in 2014 was presented here as the sixth case in literature.

ARTICLE INFO

Received 26 Feb 2015;

Accepted 07 Apr 2016;

©Iran J Pathol. All rights reserved.

Corresponding Information: Dr. Recep BEDİR, Dept. of Pathology, Recep Tayyip Erdogan University School of Medicine, Rize, Turkey. Telephone: +90464.2130491, bedirrecep@gmail.com

COPYRIGHT © 2016, IRANIAN JOURNAL OF PATHOLOGY. This is an open-access article distributed under the terms of the Creative Commons Attribution-noncommercial 4.0 International License which permits copy and redistribute the material just in noncommercial usages, provided the original work is properly cited.

Introduction

Leiomyoma developing from round ligament of uterus is rare (1, 2). These tumors mimic generally the inguinal hernia sac. The pre-operative diagnosis can be made by a computed tomography scan of the abdomen or opening the inguinal channel (3, 4). To the best of our knowledge, there have been only five cases, reported in literature as leiomyoma developing during pregnancy (4-9).

We describe here a case of a round ligament leiomyoma of a pregnant woman as the sixth case in literature. Leiomyoma should be considered in the differential diagnosis of inguinal mass.

Case Report

A 32 year-old woman admitted to Rize State Hospital, Clinic of Obstetrics & Gynecology in conjunction with painful swelling in right inguinal region presenting of a 28 week of the pregnancy. Since our patient was pregnant, no computed tomography scan could be performed. An ultrasonographic (USG) examination was observed that inguinal region measured 50x35 mm size of hypoechoic mass. However, leiomyoma of the uterus was not observed (Written informed consent was obtained from the patient). The fine-needle aspiration of inguinal mass was reported to be insufficient. Since the patient gave birth via caesarean section, the inguinal mass was totally

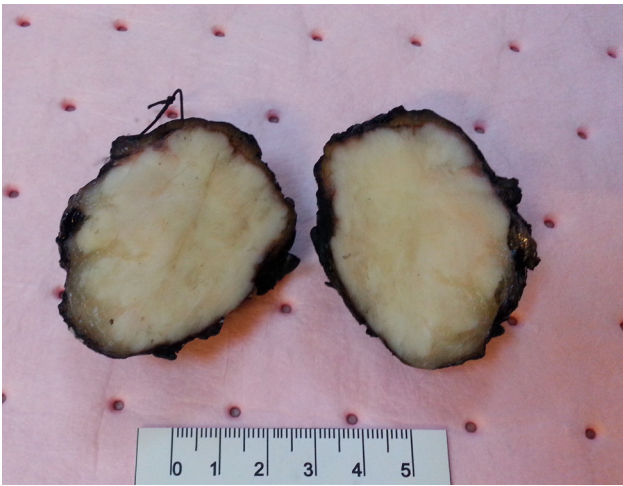


Fig. 1
A grey-white color, hard consistency, and well-circumscribed solid mass

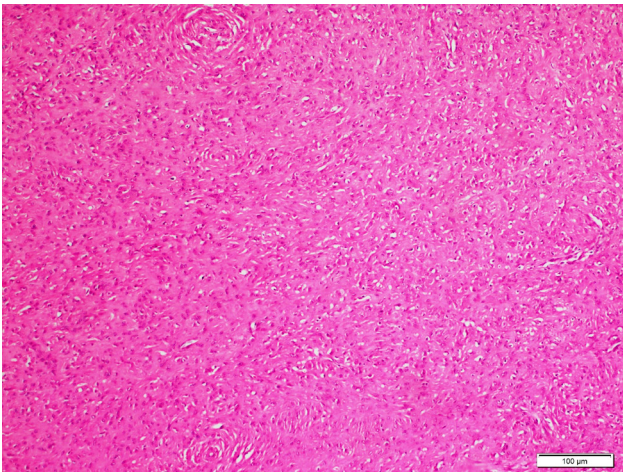


Fig. 2
Tumor showed proliferation spindle cells in storiform pattern (H&E stain x, 100)

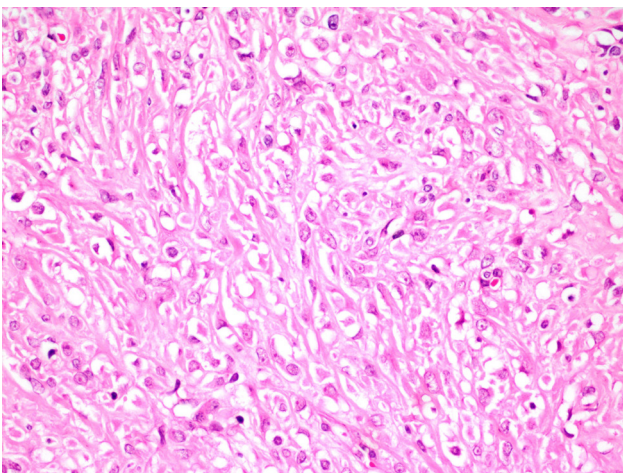


Fig. 3
Tumor showed slightly cellularity and there was no significant nuclear atypia and low mitotic activity (H&E stain x, 400)

excised with clinical diagnosis of mass lesion lymphadenopathy.

In macroscopic examination, a grey-white color, hard consistency, and well-circumscribed solid lesion in the fibrous appearance having 4.8x3.5x3 cm dimensions was observed (Fig. 1). In microscopic examination, a benign tumor establishing crossing bundles and characterized with fusiform cell proliferation was observed (Fig. 2). No cellularity increase, necrosis or pleomorphism was detected (Fig. 3) Tumor had low mitotic activity (up to 1 mitotic figure/50 HPF), and wide hyalinization regions were observed. In immunohistochemical examination, the smooth muscle actin (SMA) and desmin had positive stained, while S-100 negative stained. Based on these findings, the case was diagnosed as leiomyoma.

Discussion

Round ligament leiomyoma of uterus is very rare. They are the 3rd mostly frequently seen tumor in that region, after endometriosis and mesothelial cysts. Approximately, one-half to two-thirds of leiomyomas are seen in round ligament part of extra-peritoneal region. They are generally localized at right side, but the reason is not known (3, 10). In leiomyoma transformation of myofibrosis structures of genital system of women, there are complex interactions between sex steroids and local growth factors and somatic mutations of normal smooth muscle cells. Estrogen is the major trigger in growth of myoma, although the role of progesterone is not exactly known. Both of the receptors exist in the round ligament (3, 11, 12).

Leiomyomas exhibiting inguinal-localization are capable of mimicking incarcerated inguinal hernia or inguinal lymphadenopathies (13). In most of the cases, clinical diagnosis is consid-

ered as inguinal hernia. Inguinal hernias are a common clinical problem for general surgeons. The broad differential of hernial contents should include incarcerated uterine leiomyomas, particularly in the pregnant patient (7). In the literature, round ligament leiomyomas in pregnancy is briefly summarized in Table 1. Pre-operative CT scan may be useful for making diagnosis. In CT imaging, it is seen as a well-circumscribed

nation, SMA and desmin have positive stained.

Its curative treatment method is surgical excision. Canto et al. (2) reported a new case laparoscopic management of a leiomyoma of the round ligament. Final diagnosis is made by histopathological examination.

Although round ligament leiomyoma is seen rarely, it must be kept in mind in differential di-

Table 1

Brief summary of round ligament leiomyoma developing during pregnancy reported in the literature.

Cases	Age (gestasyonel week)	Localization	Size	Clinical pre-diagnosis
Pozzi (5)	Nil	Nil	Nil	Nil
Kelly et al.(6)	41 (26-week)	left groin	4x3 cm	Torted ovary
Meen and Vergis (7)	37 (15 week)	Right groin	5x5 cm	inguinal hernia.
Sciannameo et al. (8)	31 (20 week)	Nil	Nil	Nil
Sherer et al. (9)	35 (20-24 week)	Left groin	5x5 cm	inguinal hernia.
Our case	32 (28 week)	Left groin	4.8x3.5 cm	inguinal lymphadenopathy

heterogeneous mass in inguinal region. In USG examination, a heterogeneous hypoechoic mass is observed. In differential diagnosis, there are pre-peritoneal lipoma, lymphadenitis, hematoma, abscess, desmoid tumor, neurofibroma, femoral artery aneurysm, endometriosis, saphena magna thrombophlebitis, metastases, dermoid and epidermoid cysts that are originating from different structures in inguinal channel (14).

Our case was a clinical diagnosis different from other cases. Clinical diagnosis in most cases considered as inguinal hernia but in our case was considered as lymphoma.

Differential diagnosis of leiomyoma from leiomyosarcomas may be very problematic. Major criteria for malignancy are mitotic figures, nuclear atypia, and tumor necrosis. The mitotic activity was low and the proliferation index Ki-67 was also low (approximately 1%). The diagnosis was also confirmed with immunohistochemical stains desmin and SMA. In our case was not cellularity, increased mitotic activity and tumor necrosis. In immunohistochemical exami-

agnosis of masses having inguinal localization particularly in the pregnant patient. Pre-operative CT scan can be useful for preoperative diagnosis. Surgical excision is adequate treatment, and the final diagnosis is confirmed by histopathological examination.

Conflict of Interests

Authors have no conflict of interests to declare.

References

1. Birge O, Arslan D, Kinali E, Bulut B. Round ligament of uterus leiomyoma: an unusual cause of dyspareunia. *Case Rep Obstet Gynecol* 2015; 2015: 197842.
2. Canto MJ, Palmero S, Palau J, Ojeda F. Laparoscopic management of a leiomyoma of the round ligament. *J Obstet Gynaecol* 2015; 18:1. [Epub ahead of

print]

3. Colak E, Ozlem N, Kesmer S, Yildirim K. A rare inguinal mass: Round ligament leiomyoma. *Int J Surg Case Rep* 2013; 4(7): 577-8.

4. Ali SM, Malik KA, Al-Qadhi H, Shafiq M. Leiomyoma of the Round Ligament of the Uterus: Case report and review of literature. *Sultan Qaboos Univ Med J* 2012; 12(3): 357-9.

5. Pozzi PC. Leiomyoma of the round ligament complicating pregnancy. *Riv Ostet Ginecol Prat* 1957; 39(6): 549-59.

6. Kelly EG, Babiker M, Meshkat B, Beggan C, Leen E, Keeling P. An unusual finding in the inguinal canal of a 26-week pregnant patient. *Hernia* 2013; 17(4): 537-40.

7. Meen E, Vergis A. Rare cause of an inguinal mass in pregnancy. *Can J Surg* 2008; 51(6): E124.

8. Sciannameo F, Madami G, Madami C et al. Torsion of uterine fibroma associated with incarcerated inguinal hernia in pregnancy. Case report. *Minerva Ginecol* 1996; 48(11): 501-4.

9. Sherer DM, Edgar DM, Pulli GJ, Scibetta JJ. Pedunculated uterine fibroid simulating an incarcerated inguinal hernia in pregnancy. *Am J Obstet Gynecol* 1994;

170(3): 724-5.

10. David MW, Stanley RM. Leiomyoma of extraperitoneal round ligament: CT demonstration. *Clin Imaging* 1999; 23(6): 375-6.

11. Rein MS, Barbieri RL, Freidman AJ. Progesterone: A critical role in the pathogenesis of uterine myomas. *Am J Obstet Gynecol* 1995; 172(1): 14-8.

12. Smith P, Heimer G, Norgren A, Ulmsten U. The round ligament: A target organ for steroid hormones. *Gynecol Endocrinol* 1993; 7(2): 97-100.

13. Harish H, Sowmya NS, Induhara PB. A rare case of round ligament leiomyoma: an inguinal mass. *J Clin Diagn Res* 2014; 8(10): NJ05-6.

14. Bhosale PR, Patnana M, Viswanathan C, Szkalaruk J. The inguinal canal: anatomy and imaging features of common and uncommon masses. *Radiographics* 2008; 28(3): 819-35.

How to cite this article:

Bedir R, Yilmaz R, Sehitoglu İ, Yurdakul C. Round Ligament Leiomyoma Developing During Pregnancy: A Case Report and Literature Review. *Iran J Pathol.* 2016; 11(3):261-4.