

## Is adalimumab protective in ischemia-reperfusion injury in lung?

Aysel Kurt <sup>1\*</sup>, Levent Tumkaya <sup>2</sup>, Yildiray Kalkan <sup>2</sup>, Hasan Turut <sup>1</sup>, Medine Cumhuri Cure <sup>3</sup>, Erkan Cure <sup>4</sup>, Ibrahim Sehitoglu <sup>5</sup>, Hacer Bilgin <sup>3</sup>, Mustafa Usta <sup>4</sup>

<sup>1</sup> RecepTayyip Erdogan University, School of Medicine, Department of Thoracic Surgery, Rize, Turkey

<sup>2</sup> RecepTayyip Erdogan University, School of Medicine, Department of Histology and Embryology, Rize, Turkey

<sup>3</sup> RecepTayyip Erdogan University, School of Medicine, Department of Biochemistry, Rize, Turkey

<sup>4</sup> RecepTayyip Erdogan University, School of Medicine, Department of Internal Medicine, Rize, Turkey

<sup>5</sup> RecepTayyip Erdogan University, School of Medicine, Department of Pathology, Rize, Turkey

### ARTICLE INFO

#### Article type:

Original article

#### Article history:

Received: Apr 8, 2015

Accepted: Jul 23, 2015

#### Keywords:

Adalimumab  
Endothelin-1  
Ischemia reperfusion  
Lung injury  
Tumor necrosis factor-alpha

### ABSTRACT

**Objective(s):** Increasing cytokines and reactive oxygen species (ROS) during ischemia reperfusion (I-R) leads to the lung damage. Adalimumab (Ada) is a potent tumor necrosis factor-alpha (TNF- $\alpha$ ) inhibitor agent. We aimed to evaluate whether Ada would prevent the lung tissue from damage development over the I-R process.

**Materials and Methods:** Twenty seven Wistar albino male rats were divided into three groups (each group had 9 rats). To the control group, only laparotomy procedure was carried out. For I-R group, first infrarenal abdominal aorta was cross-clamped during 2 hr, and then reperfusion was performed for 2 hr. To I-R+Ada group, first a single dose of 50 mg/kg Ada was given intraperitoneally and 5 days later, same I-R procedure was carried out.

**Results:** Levels of TNF- $\alpha$ , malondialdehyde (MDA), myeloperoxidase (MPO), endothelin-1 (ET-1) and caspase-3 enzyme activity of I-R group were higher than that of both I-R+ Ada [TNF- $\alpha$  ( $P=0.021$ ), MDA ( $P=0.029$ ), MPO ( $P=0.012$ ), ET-1 ( $P=0.036$ , caspase-3 ( $P=0.007$ ), respectively] and control group [TNF- $\alpha$  ( $P=0.008$ ), MDA ( $P<0.001$ ), MPO ( $P=0.001$ ), ET-1 ( $P<0.001$ ), caspase-3 ( $P<0.001$ ), respectively]. In I-R group, severe damage was detected by hematoxylin-eosin staining. This damage was found less severe in Ada treatment group.

**Conclusion:** The release of cytokines and ET-1 in a large proportion after I-R injury, and generating of ROS in excessive quantity could cause severe damage in the lung tissue. Ada could be considered as a protective agent for lung tissue during I-R process.

#### ► Please cite this article as:

Kurt A, Tumkaya L, Kalkan Y, Turut H, Cumhuri Cure M, Cure E, Sehitoglu I, Bilgin H, Usta M. Is adalimumab protective in ischemia-reperfusion injury for lung? Iran J Basic Med Sci 2015; 18:1093-1099.

### Introduction

Ischemia reperfusion (I-R) induced acute lung injury seen often after lung transplantation and cardiac operations is one of the most important leading causes of early mortality and morbidity (1). Reperfusion of ischemic tissues could lead to altered tissue barrier function and microvascular dysfunction on account of local and systemic inflammatory response (1). Polymorphonuclear leukocytes (PMNL) and reactive oxygen species (ROS) have been shown as an important etiological substrates of I-R induced acute lung injury (1, 2).

Having rich microcapillary systems of lung tissue is one of the further organs damaged by systemic injury developing during the I-R process (3). Chemoattractants released post-IR period can cause an increase in number of PMNL, macrophages and mononuclear leucocytes, and this consequently leads an increased permeability to the lungs (4).

Moreover, ROS and pro-inflammatory cytokines like tumor necrosis factor-alpha (TNF- $\alpha$ ) increased after reperfusion of ischemic tissues could cause microvascular dysfunction and local inflammatory response, loss of alveolar capillary barrier, intestinal and alveolar edema and lipid peroxidation, and thus this process ends with cell death (1, 2). An increase in levels of malondialdehyde (MDA), a good marker of lipid peroxidation and oxidative stress, is correlated with tissue damage (3). Myeloperoxidase (MPO), released by active neutrophils, is a valuable and reliable marker for evaluating neutrophil infiltration to the lung tissue (5). In addition, endothelin-1 (ET-1), a highly potent vasoconstrictor peptide released by endothelial cells, which is produced in response to acute inflammatory stimuli is an integral component of the systemic inflammatory reaction that plays a crucial role in the inflammatory process (1, 6). Infusion of ET-1 causes PMNL sequestration in rat lung (7). It is well-

\*Corresponding author: Aysel Kurt. Department of Thoracic Surgery, University of Recep Tayyip Erdogan, School of Medicine, Rize, 53100, Turkey. Tel: +904642130491-1964; Fax: +90-46421703 64; email: drayselkurt@yahoo.com

documented that both ROS and increased cytokines would induce apoptosis by activating the caspase-3 enzyme, and thus it causes tissue damage (8).

Adalimumab (Ada) is a TNF- $\alpha$  blocker that is used in Crohn disease (an inflammatory bowel disease) (9), rheumatological diseases such as rheumatoid arthritis and ankylosing spondylitis (10) and psoriasis (11). It has high affinity to the both forms (soluble and transmembrane) of TNF- $\alpha$  and consequently blocks TNF- $\alpha$  from binding to its receptors (12). It has been shown that blocking the release of pro-inflammatory cytokines like TNF- $\alpha$  by infliximab and Ada, both TNF- $\alpha$  blockers, could decrease tissue damage during I-R (13).

In this study, the level of ET-1 and TNF- $\alpha$  as two pro-inflammatory cytokines, and the activity of MDA and MPO enzymes were measured to evaluate the role of generated ROS and apoptosis in damaged lung tissue during the I-R. Also, we aimed to reveal the effects of Ada on these parameters and whether it did play a preventive role in lung tissue damage.

## Materials and Methods

### Animals

A total of 27 male Wistar albino rats with a mean weight of 250 to 300 g, and 12 to 15 weeks old were included in the study. Rats were ensured with food and water *ad libitum*, and maintained in a standard temperature and humid environment with a 12 hr light-dark cycle. All protocols conformed to the Guide for the Care and Use of Laboratory Animals (NIH, 1985) and certificated by the local ethical committee (Approval numbers: 2014/10).

### Experimental design

The rats were randomly allocated into three groups (control, I-R and I-R+Ada), each with nine rats. The control group and I-R groups were given saline solution intraperitoneal and underwent a midline laparotomy. Infrarenal abdominal aorta (IAA) was dissected and crossed without obstruction in the control group. For the I-R group, IAA was clamped for 120 min then reperfusion was carried out for 120 min. Only one single dose of 50 mg/kg Ada (Humira; Abbott, Abbott Park, Ill) (40 mg/0.8 ml) was administered intraperitoneally to the I-R+Ada group (14). The I-R+Ada group underwent respectively 120 min of ischemia and 120 min of reperfusion after five days of Ada administration.

### Ischemia reperfusion injury model

The animals were anesthetized by intramuscularly injection of 50 mg/kg ketamine hydrochloride (Ketalar; Eczacıbası, Istanbul, Turkey). Anesthesia was maintained in all experiments by intramuscular injections of 25 mg/kg ketamine hydrochloride when needed. The rats were given the supine position under

a heating lamp for surgical procedures. After the abdomen was shaved, the skin prepared aseptically and a midline laparotomy was performed. IAA was explored and clamped with an atraumatic microvascular clamp. Fluid balance was provided with warm normal saline (10 ml) in the peritoneal cavity. The abdominal incision was closed and the wound was covered with plastic wrap to prevent loss of body heat and fluid. After 120 min of ischemia, the atraumatic microvascular clamp was removed on the IAA and lower extremities were reperfused for 120 min. The I/R model was planned in a method similar to previous studies (15). Aortic occlusion was followed by the loss of distal arterial pulsation. At the end of the procedures, the rats were sacrificed under anesthesia, and then lung tissues were obtained from all of the rats. The specimens were stored at -80 °C until biochemical and histological analyses were conducted.

### Tissue homogenates

Frozen lung tissue samples were weighed and homogenized by phosphate buffered saline (PBS) (50 mM, pH 7.4). The homogenates were centrifuged at 10,000 g for 20 min. The supernatant was removed to be aliquoted to tubes. It was kept frozen at -80 °C and the parameters were studied within a month. In tissue samples, levels of TNF- $\alpha$ , MDA, MPO, and ET-1 were measured.

### Measurement of protein

Tissue homogenate protein assay is Lowry protocol. The protocol is based on both the Biuret reaction, and the Folin-Ciocalteu reaction. In Biuret reaction, the peptide bonds of proteins react with copper under alkaline conditions to produce Cu<sup>+</sup>, which reacts with the Folin reagent (16).

### Tissue TNF- $\alpha$

The concentration of TNF- $\alpha$  was measured using enzyme-linked immunosorbent assay (ELISA) method. We used commercially available rat TNF- $\alpha$  ELISA kit (e Bioscience, Vienna, Austria). The procedure for the ELISA method was according to the instructions provided by the manufacturer. Absorbance was measured at a wave length of 450 nm using ELISA reader. The levels of TNF- $\alpha$  are presented as pg/ml. The intra-assay and inter-assay co-efficient of variation were <5% and <10%, respectively. The limit of detection (LOD) for the TNF- $\alpha$  assay was 11 pg/ml. After dividing the obtained values by the protein levels, the final results were founded as pg/mg protein.

### Tissue MDA

MDA levels were measured by the double heating method of Draper and Hadley. The principle of this method is the spectrophotometric measurement of

**Table 1.** All biochemical results of the three groups

	I-R	I-R + ADA	Control
TNF- $\alpha$ pg/mg protein	206.1 $\pm$ 55.7* $\eta$	154.0 $\pm$ 42.1a	140.3 $\pm$ 27.8
MDA nmol/mg protein	2.9 $\pm$ 0.4# $\pi$	2.5 $\pm$ 0.3b	2.1 $\pm$ 0.4
MPO ng/mg protein	0.59 $\pm$ 0.07 $\chi$ $\beta$	0.50 $\pm$ 0.11 $\zeta$	0.45 $\pm$ 0.08
ET-1pg/mg protein	10.3 $\pm$ 1.7# $\epsilon$	8.1 $\pm$ 2.6 $\mu$	5.0 $\pm$ 1.7

I-R : Ischemia reperfusion; I-R+Ada: Ischemia reperfusion+Adalimumab; TNF- $\alpha$ , Tumor necrosis factor-alpha; MDA, malondialdehyde; MPO, myeloperoxidase; ET-1, Endothelin-1

# $P$ <0.001, $\chi$  $P$ =0.005,\* $P$ =0.008, $\eta$  $P$ =0.010, $\beta$  $P$ =0.045, $\zeta$  $P$ =0.268, $\mu$  $P$ =0.549 vs. control group

$\pi$  $P$ =0.021, $\epsilon$  $P$ =0.036, $\rho$  $P$ =0.043, $\sigma$  $P$ =0.065 vs. I-R+Ada group

the color generated by the reaction of thiobarbituric acid (TBA) with MDA. The MDA levels are presented as mmol/l (17). Dividing the situated values by the protein levels, the eventual results were obtained as nmol/mg protein.

#### Tissue ET-1

The concentration of ET-1 was measured by ELISA method using commercially available rat ET-1 ELISA kit (Elabscience, WuHan, P.R.C). The procedure for the ELISA method was according to the instructions provided by the manufacturer. Absorbance was measured at 450 nm using ELISA reader. The levels of ET-1 are presented as pg/ml. The co-efficient of variation was <10%. The minimum detectable dose of ET-1 assay was 4.69 pg/ml. The final results were founded as pg/mg protein after dividing the obtained results by the protein levels.

#### Tissue MPO

The concentration of MPO was also measured by ELISA method using commercially rat MPO ELISA kit (Elabscience, WuHan, P.R.C). Absorbance was measured at 450 nm using ELISA reader. The levels of MPO are presented as ng/ml. The co-efficient of variation was <10%. The minimum detectable dose of MPO assay was 0.19 ng/ml. The obtained results divided by the protein levels and later the final results were obtained as ng/mg protein.

#### Immunohistological evaluation

The lung tissues were prepared for histopathological analysis and then were fixed in 10% neutral formaldehyde for 24 hr. They were cut in 3  $\mu$ m thickness for immunohistochemical staining and in 4  $\mu$ m thickness for hematoxylin-eosin (H&E) staining. These sections were kept in xylene for 20 min before the implementation of an alcohol series (50–100%), afterward allowed to keep for 30 min in H<sub>2</sub>O<sub>2</sub> solution. After washing with PBS, these sections were heated in a citrate buffer solution at 800 W for 4 to 5 min, and maintained in secondary blocker substance for 30 min. The slides were allowed to stand for 60 min in different dilutions of the primary antibody (Anti-Caspase-3 antibody (ab4051), Abcam plc, Cambridge, CB4, OFL, UK), and a diaminobenzidine solution was used as a chromogen.

the samples were treated with Mayer's hematoxylin as a counterstain for 4 to 5 minutes, then PBS was used a negative control. The preparations were examined under light microscope and then were photographed after being covered with the eligible covering materials. Analysis was performed by employing a blind evaluation protocol performed by two histologists and one pathologist. The sections were divided into 4 categories according to the tissue percentage of immunopositive reaction areas; the stain of preparations were evaluated as weak (+), mild (++), moderate (+++) and severe (++++).

#### Statistical analyses

Statistical analysis was performed by using SPSS for Windows (SPSS, USA) version 17.0 and continuous variables were reported as mean  $\pm$  standard deviation. Comparison of the groups' biochemical parameters analyses were performed using the one-way ANOVA and Bonferroni *post hoc* tests. The Mann-Whitney U test was used to compare the groups for histopathologic parameters and caspase-3. Differences of  $P$ <0.05 was considered significant.

## Results

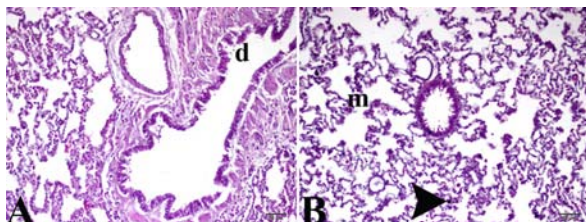
#### Biochemical results

In I-R group, TNF- $\alpha$ , MDA, MPO and ET-1 levels were significantly higher than that of the controls and the group treated with Ada. Compared to the control group, TNF- $\alpha$ , MDA, MPO and ET-1 levels were higher in I-R+Ada group but lower than that of I-R group. All biochemical variables were shown in the Table 1.

#### Histopathological findings

Histopathological examination of the lungs of the control group rats revealed that there was no tissue discontinuation and no pathologic findings. The control group had histopathologically normal cellular morphologic appearance and had not interstitial inflammation and congestion in lung tissues. Although there were mildly epithelial cells debris in especially terminal bronchioles; in addition, connective tissues in lamina propria was intact and normal in these areas. Excretory ductals and vessel patterns had also normal histological features (Figure 1).



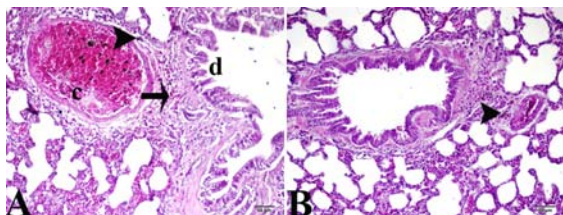


**Figure 1.** A, B; Normal lung tissue architecture in control rats by light microscopy, hematoxylin-eosin stain. d: epithelial cells debris, m: alveolar macrophages, arrowhead: pigmentation

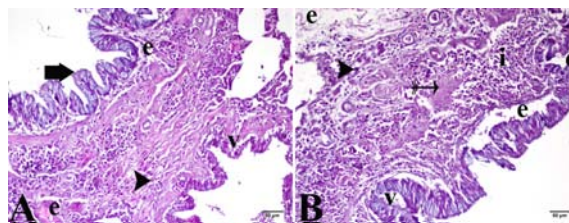
Histopathological findings of the lungs in I-R group showed that interstitial distance was expanded; in addition, edema, and severe damages of alveolar epithelial cells (alveolar epithelial injury) was found in this area. In lamina propria, PMNL infiltration and fibroblast accumulations were also observed. Also, increasing in the number of alveolar macrophages was found. In the lung tissue of I-R group, which had no normal histological morphology, there was increasing PMNL and mononuclear leukocyte infiltration in interstitial distance and congestion in small vessels lumens. There were mild pigmentations around the bronchioles and terminal bronchioles in the lungs of I-R group and this pigmentation was also found in alveolar macrophages. In some rats, mild perivascular edema, focal interstitial and intraalveolar mononuclear leukocyte infiltration and mild proteinaceous exudate were observed (Figure 2A, 2B).

In I-R+Ada group, the congestions in small vessels were decreased compared to I-R group. PMNL infiltration and fibroblastic foci were also decreased in lamina propria. Moreover, the severity of epithelial cell degeneration and cell debris in alveoli, increase of interstitial connection tissues and dense of alveolar macrophages were found significantly low in this group. Pigmentation emerging in this group around the bronchi and terminal bronchioles, their dense and size were also decreased. Pigmentations found in alveolar macrophages were similar with that in the control group (Figure 3).

Caspase-3 enzyme activity in I-R group was significantly higher than that of both control and I-R+Ada group. The amount of caspase-3 in I-R+Ada group was significantly higher than the control



**Figure 3.** Histopathological examination of lung tissue in I-R+Ada group stained by hematoxylin-eosin by light microscopy A: d: epithelial cells debris, arrowhead: pigmentation, arrow: decrease mononuclear cell infiltration, c: congestion, B: arrowhead: pigmentation, I-R+Ada: ischemia reperfusion+ adalimumab applied group



**Figure 2.** Histopathological examination of lung tissue in I-R group stained by hematoxylin-eosin by light microscopy. A: e: edema, v: vacuolization, short arrow: degenerating cells, arrowhead: pigmentation, B: v: vacuolization, i: mononuclear cell infiltration, thin arrow: fibrosis, e: edema, d: epithelial cells debris, arrowhead: pigmentation, I-R: ischemic reperfusion

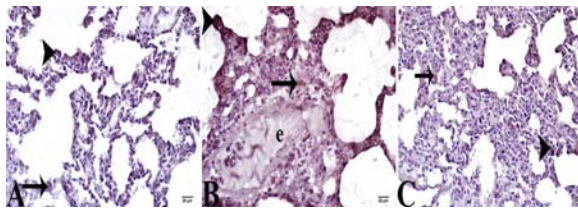
group, but it was much lower than I-R group. All histopathological findings and caspase-3 levels are shown in Table 2 and Figure 4.

## Discussion

In this study, TNF- $\alpha$ , MDA, MPO and ET-1 levels in I-R group were higher than that of both controls and I-R+Ada group. Histopathological examination revealed severe-dense damage in the lung tissue.

In I-R group, caspase-3 enzyme activity was found prominently higher. In I-R+Ada group, TNF- $\alpha$ , MDA, MPO and ET-1 levels were lower compared to the I-R group, but higher in comparison with controls. Histopathological examination of the lung tissue in I-R+Ada group showed little histopathological damage. Immunohistochemical analysis revealed that caspase-3 enzyme activity was significantly lower in I-R+Ada group than that of I-R group. All these findings suggested that Ada treatment could cause a prominent decrease in damage developing in the lung tissue during the I-R process.

Lung is one the most vulnerable and affected organs during the local and systemic I-R damages (3). There are many factors playing a role in the damaging of the lungs during I-R. In ischemia stage, decreasing of oxygen pressure and inability to supply increased metabolic needs alongside severe cytokine release during reperfusion stage all together cause an increase in ROS production and led to damage in both cells and tissues (1, 3). TNF- $\alpha$  is a major pro-inflammatory cytokine responsible for I-R damage. During I-R process lymphocytes,



**Figure 4.** Histopathological examination of lung tissue stained by immunoperoxidase method by light microscopy A: control group, B: I-R group, C: I-R+Ada, arrowhead: strong positivity, arrow: weak positivity, e: edema, immunoperoxidase stained Anti-Caspase-3 antibody. I-R: ischemia reperfusion, I-R+Ada: ischemia reperfusion +adalimumab

**Table 2.** Histopathological examination of lung tissue

	Control	I-R	I-R+Ada
Inflammation	0,00±0,35	3,00±0,71**	2,00±0,46*
Congestion	0,00±0,46	2,00±0,52*x	1,50±0,53*
Edema	0,00±0,35	3,00±0,46**	2,00±0,52*
Vacuolization	0,00±0,35	3,00±0,35**	2,00±0,52*
Epithelial degeneration	0,00±0,46	3,00±0,52**	1,50±0,53*
Alveolar macrophages density	0,00±0,46	3,50±0,74**	3,00±0,46*
Caspase-3	1,00±0,52	3,00±0,52**	2,00±0,52†

I-R, Ischemia reperfusion; I-R+Ada, Ischemia reperfusion+Adalimumab

\* $P < 0.001$ , \* $P = 0.006$  vs. control group

† $P < 0.001$ , † $P = 0.001$ , x $P = 0.022$ , \* $P = 0.038$  vs. I-R+Ada group

neutrophils and macrophages migrate to the damage sites and release a large quantity of TNF- $\alpha$ , and thereby it leads to ROS production in environment (3, 12). Both TNF- $\alpha$  releasing and ROS production induce apoptosis and consequently cause cell damage (13). During I-R process, blocking of TNF- $\alpha$  and other pro-inflammatory cytokines could prevent from tissue damage (18). Ada, a potent TNF- $\alpha$  blocker, has been shown to decrease the excessive TNF- $\alpha$  releasing during the I-R (13, 14). In our study, TNF- $\alpha$  level of lung tissue in I-R group was significantly higher than that of controls and I-R+Ada. In I-R model, created by clamping of abdominal aorta, the lung tissue was highly affected by I-R damage. In Ada group, TNF- $\alpha$  was prominently lower and lung tissue was significantly protected from I-R damages shown by histopathological examination.

During the reperfusion stage, there is excessive ROS generating with the entrance of oxygen to the cells. In addition, releasing of a large proportion of pro-inflammatory cytokines can enhance the ROS generation (1). MDA is a valuable marker showing the lipid peroxidation and ROS production (19). In the I-R damage, MDA levels increased, showing that it can be considered as an effective indicator pointing out the ROS production and tissue damage (20). ROS production triggers caspase-3 enzyme system and then increases apoptosis, and therefore leads to cell and tissue death (21). Ada was shown to decrease the tissue damage during acute pancreatitis via TNF- $\alpha$  blockage and decreasing ROS production (14). In another study, it has been reported that during I-R process Ada could regulate the levels of NO and then could cause a decrease in producing of peroxynitrite radicals, leading to a blockage in ROS generation and therefore reducing the damage of liver tissue (13). In our study, MDA levels were significantly higher and there was dense histopathological damage in I-R group. In I-R+Ada group, however, MDA levels were lower compared to the I-R group. Ada could probably decrease ROS production via TNF- $\alpha$  blocking, and thus caspase pathway might be activated at a lesser extent. Therefore, lung tissue in I-R+Ada group had

lesser histopathological damage than that of I-R group.

The azurophilic granules of neutrophils have got some enzymes such as MPO which is carry out oxidant effects; therefore, neutrophils playing a crucial role in developing ROS (22). MPO activity increases in reperfusion stage more than ischemic stage. MPO converts hydrogen peroxide and hydrogen chloride ions to hypochlorous acid during the I-R process (5). Increased activity of MPO over the I-R can also point out indirectly that ROS production has also increased in the lung tissue. On the other hand, MPO uses NO as a substrate and not only decreases bioavailability of NO, but also it damages NO-dependent blood vessel relaxation via generating peroxynitrite radicals (22). Consequently, vasoconstriction during the I-R process becomes more severe, and ROS production increases further. It has previously been reported that decreasing of MPO activities by using some agents during the I-R could prevent lung tissue damage (2, 21, 22). It has also been reported that Ada prevented oxidative damage by decreasing MPO activities (14). In our study, MPO levels in I-R group were significantly higher, and in group treated with Ada its levels were lower prominently. Ada could well prevent the lung tissue from damaging of I-R by decreasing MPO levels.

Increased ROS causes endothelial cell damage. Endothelium normally produces ET-1 and NO (23). With damage developed by ROS, endothelial cells begin to produce more ET-1 (1) resulting in severe vasoconstriction. Additionally, ET-1 releasing increases cytokines and ROS production that consequently activates caspase pathway leading to the lung tissues damage. During I-R process, decreasing in the NO levels and increasing ET-1 release via gene expression lead to vasoconstriction and tissue damage (6). In a study, it has been reported that during I-R Ada decreased I-R damage via balancing of NO release (13). No further study reported the effects of Ada and ET-1 together in the literature, except one in which Infliximab, another TNF- $\alpha$  inhibitor, prevented the tissue from damaging through reducing ET-1 levels (24). This study

showed that Ada reduced ET-1 levels by blocking vasoconstriction during the I-R process.

Leucocyte activation triggered by I-R induced damage alongside inflammatory mediators cause an edema, increase in vascular permeability and a rise in alveolar permeability in the lungs (1, 2). In this study, inflammation, edema and epithelial degeneration were observed severely in I-R group, whereas in I-R+Ada group these findings were at subtle levels compared to the I-R group. Caspase-3 enzyme activity was significantly higher in the I-R group, and severe histopathological damage was prominent. Caspase-3 activation was lesser in I-R+Ada group, and there was less histological damage.

## Conclusion

The severe release of cytokines and increased ROS generations activate caspase enzyme system and apoptosis in lung tissue through I-R. Therefore, they are extremely damage to lung tissue. Severe vasoconstriction occurs due to NO-related vasodilatation damages on account of ET-1 release and ROS generation during I-R that can lead to lung damage. Ada could well decrease the release of cytokines and generation of ROS via blockage of TNF- $\alpha$ , and consequently suppressed the activation of caspase pathway. Furthermore, Ada would diminish lung damage over I-R process by decreasing ET-1 release.

## Acknowledgment

Our experimental work was funded by all authors. All the co-authors have seen and approved the final version of this manuscript.

## Conflict of interest

Authors have no conflict of interest to declare.

## References

- Ng CS, Wan S, Arifi AA, Yim AP. Inflammatory response to pulmonary ischemia-reperfusion injury. *Surg Today* 2006; 36:205-214.
- Türüt H, Kurutas EB, Bulbuloglu E, Yasim A, Ozkaya M, Onder A, *et al.* Zinc aspartate alleviates lung injury induced by intestinal ischemia-reperfusion in rats. *J Surg Res* 2009; 151:62-67.
- Mao YF, Yu QH, Zheng XF, Liu K, Liang WQ, Wang YW, *et al.* Pre-treatment with Cobra venom factor alleviates acute lung injury induced by intestinal ischemia-reperfusion in rats. *Eur Rev Med Pharmacol Sci* 2013; 17:2207-2217.
- Garbaisz D, Turoczi Z, Fulop A, Rosero O, Aranyi P, Onody P, *et al.* Therapeutic option for managing lung injury induced by infrarenal aortic cross-clamping. *J Surg Res* 2013; 185:469-476.
- Faith M, Sukumaran A, Pulimood AB, Jacob M. How reliable an indicator of inflammation is myeloperoxidase activity? *Clin Chim Acta* 2008; 396:23-25.
- Sato Y, Hogg JC, English D, van Eeden SF. Endothelin-1 changes polymorphonuclear leukocytes' deformability and CD11b expression and promotes their retention in the lung. *Am J Respir Cell Mol Biol* 2000; 23:404-410.
- Helset E, Lindal S, Olsen R, Myklebust R, Jørgensen L. Endothelin-1 causes sequential trapping of platelets and neutrophils in pulmonary microcirculation in rats. *Am J Physiol* 1996; 271:L538-546.
- Zhang A, Fu S, Chen L, Ren L, Qu S, Zhang Y, *et al.* Lacidipine attenuates apoptosis via a caspase-3 dependent pathway in human kidney cells. *Cell Physiol Biochem* 2013; 32:1040-1049.
- Chang CW, Wei SC, Chou JW, Hsu TC, Chuang CH, Lin CP, *et al.* Safety and efficacy of adalimumab for patients with moderate to severe crohn's disease: the taiwan society of inflammatory bowel disease (TSIBD) study. *Intest Res* 2014; 12:287-292.
- Furst DE, Schiff MH, Fleischmann RM, Strand V, Birbara CA, Compagnone D, *et al.* Adalimumab, a fully human anti tumor necrosis factor-alpha monoclonal antibody, and concomitant standard antirheumatic therapy for the treatment of rheumatoid arthritis: results of STAR (Safety Trial of Adalimumab in Rheumatoid Arthritis). *J Rheumatol* 2003; 30:2563-2571.
- Nakamizo S, Miyachi Y, Kabashima K. Addition of cyclosporine to adalimumab improved psoriasis and adalimumab-induced injection site reaction. *Indian J Dermatol* 2014; 59:522-523.
- Shen C, Assche GV, Colpaert S, Maerten P, Geboes K, Rutgeerts P, *et al.* Adalimumab induces apoptosis of human monocytes: a comparative study with infliximab and etanercept. *Aliment Pharmacol Ther* 2005; 21:251-258.
- Cure E, Cumhuri Cure M, Tumkaya L, Kalkan Y, Aydin I, Kirbas A, *et al.* Adalimumab ameliorates abdominal aorta cross clamping which induced liver injury in rats. *Biomed Res Int* 2014; 2014:907915.
- Yilmaz M, Tekekoglu S, Herek O, Ozmen O, Sahinduran S, Buyukoglu T. Ameliorative effect of adalimumab on experimentally induced acute pancreatitis in rats. *Pancreas* 2010; 39:1238-1242.
- Oyar EÖ, Kiriş I, Gülmen S, Ceyhan BM, Cüre MC, Sütcü R, *et al.* Adrenomedullin attenuates aortic cross-clamping-induced myocardial injury in rats. *Am J Surg* 2011; 201:226-232.
- Lowry OH, Rosebrough NJ, Farr AL, Randall RJ. Protein measurement with the folin phenol reagent. *J Biol Chem* 1951; 193:265-275.
- Draper HH, Hadley M. Malondialdehyde determination as index of lipid peroxidation. *Methods Enzymol* 1990; 186:421-431.
- Cure E, Cure MC, Tumkaya L, Kalkan Y, Aydin I, Kirbas A, *et al.* Topiramate ameliorates abdominal aorta cross-clamping induced liver injury in rats. *Saudi J Gastroenterol* 2014; 20:297-303.
- Nielsen F, Mikkelsen BB, Nielsen JB, Andersen HR, Grandjean P. Plasma malondialdehyde as biomarker for oxidative stress: reference interval and effects of life-style factors. *Clin Chem* 1997; 43:1209-1214.
- Fu Z, Liu X, Geng B, Fang L, Tang C. Hydrogen sulfide protects rat lung from ischemia-reperfusion injury. *Life Sci* 2008; 82:1196-1202.
- Cao QF, Qu MJ, Yang WQ, Wang DP, Zhang MH, Di SB. Ischemia postconditioning preventing lung ischemia-reperfusion injury. *Gene* 2015; 554:120-124.
- Bayomy NA, Elshafhey SH, ElBakary RH, Abdelaziz EZ. Protective effect of hesperidin against lung injury induced by intestinal ischemia/reperfusion in adult

albino rats:histological, immunohistochemical and biochemical study. *Tissue Cell* 2014; 46:304-310.

23. De Perrot M, Liu M, Waddell TK, Keshavjee S. Ischemia-reperfusion-induced lung injury. *Am J Respir Crit Care Med* 2003; 167:490-511.

24. Kotyla PJ, Owczarek A, Rakoczy J, Lewicki M,

Kucharz EJ, Emery P. Infliximab treatment increases left ventricular ejection fraction in patients with rheumatoid arthritis:assessment of heart function by echocardiography, endothelin 1, interleukin 6, and NT-pro brain natriuretic peptide. *J Rheumatol* 2012; 39:701-706.