

**Pelvic tuberculosis presenting with pyometra in a post-menopausal woman**

Post menopozal bir kadında pyometra ile presente olan pelvik tüberküloz

Balık G<sup>1</sup> Ustuner I<sup>1</sup> Ural U M<sup>1</sup> Bayoglu Tekin Y<sup>1</sup> Kagitci M<sup>1</sup> Gucer H<sup>2</sup> Guvendag Guven E S<sup>1</sup><sup>1</sup>Recep Tayyip Erdogan University Faculty Of Medicine, Department of Gynecology and Obstetrics, Rize, Turkey<sup>2</sup>Recep Tayyip Erdogan University Faculty Of Medicine, Department of Pathology, Rize, Turkey**Summary**

A 63-years-old postmenopausal woman was admitted to the gynecology clinic with vaginal discharge, abdominal pain, and pyrexia. Ultrasonography revealed evidence of pyometra. Serum CA-125 and CA 19-9 levels were elevated. Endometrial biopsy revealed no malignant cells or acid-fast bacilli. We performed total hysterectomy with bilateral salpingo-oophorectomy. Histological examination revealed caseous granulomatous inflammation. The diagnosis of genital tuberculosis was made and antituberculosis treatment was initiated. Here, we present a pelvic tuberculosis with pyometra in a post-menopausal women with elevated CA 125 and CA 19 9 levels.

**Key Words:** CA 125 Antigen, post-menopausal period, urogenital tuberculosis.

**Özet**

63 yaşında, postmenopozal kadın hasta vajinal akıntı, karın ağrısı ve ateş şikayetiyle jinekoloji polikliniğine başvurdu. Ultrasonografide pyometri tespit edildi. Serum CA-125 ve CA 19-9 düzeyleri yüksekti. Endometrial biyopside malignite ve aside dirençli basil saptanmadı. Bilateral salpingo-ooferektomi ve total histerektomi yapıldı. Histolojik incelemede kazeöz granülomatöz inflamasyon saptandı. Genital tüberküloz tanısı koyuldu ve antitüberküloz tedavi başlandı. Burada, postmenopozal bir hastada yüksek CA 125 ile CA 19 9 seviyeleri ve pyometri ile presente olan pelvik tüberküloz vakası sunulmaktadır.

**Anahtar Sözcükler:** CA 125, postmenopozal dönem, ürogenital tüberküloz.

**Introduction**

Accumulation of pus in the uterine cavity is termed pyometra and has an incidence of 0.1 - 0.5% in women. Pyometra is a rare event in the general population but more common in elderly women. The most common causes of pyometra are genital tract malignancies and radiotherapy applications. Other causes are benign tumors like leiomyoma, endometrial polyps, senile cervicitis, post-surgical cervical occlusion, genital tuberculosis and congenital cervical anomalies (1).

Genital tuberculosis is a chronic disease and often has low-grade symptomatology, with very few specific complaints. Genital tuberculosis has an incidence of 0.3-1.3% in women (2). The most common presentation is infertility. The other symptoms are pelvic pain, vaginal bleeding, amenorrhea, vaginal discharge, and postmenopausal bleeding.

Less common presentations include abdominal mass, ascites, tubo ovarian abscess, and vague abdominal distention (3). Genital tuberculosis may mimic ovarian malignancy and CA-125 may be falsely elevated (4).

In this case, we present genital tuberculosis presenting with pyometra in a post-menopausal woman with elevated CA 125 and CA 19-9 levels.

**Case Report**

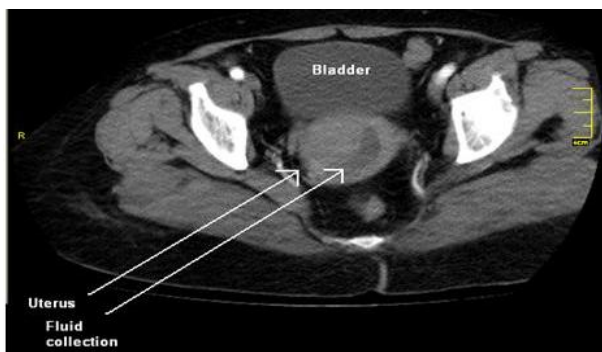
A 63-year-old postmenopausal, nulliparous woman was admitted to our clinic with a 6 month history of purulent vaginal discharge, lower abdominal pain and night fevers. There was no history of weight loss, vomiting, urinary or bowel complaints. On clinical examination, the vital signs were stable. There was no rebound and defense. The pathologic findings of pelvic examination were symmetrical enlargement of the uterus, cervical motion tenderness and purulent vaginal discharge. Ultrasound examination revealed pyometra, and normal adnexa and the pouch of Douglas. Hemoglobin and white blood cell count were unremarkable. The CA125 (62 U/mL) and CA 19-9 (249 U/mL) levels were elevated.

Corresponding Author: Gulsah BALIK

Recep Tayyip Erdogan University Faculty of Medicine, Department of Gynecology and Obstetrics, Rize, Turkey

Received: 24.06.2013 Accepted: 31.07.2013

Computed tomography scanning of abdomen revealed the presence of fluid within the uterine cavity (Figure-1). The patient was administered broad spectrum antibiotics. Approximately 150 ml of pus from uterine cavity was drained and an endometrial biopsy was performed. The biopsy revealed endometritis. The routine culture of pus sample was negative for growth. Mammography was normal. At the laparotomy stage, there were dense adhesions in the pelvic cavity. A total abdominal hysterectomy with bilateral salpingo-oophorectomy was performed. Frozen sections demonstrated caseous granulomatous inflammation and pyometra with no evidence of malignancy (Figure-2,3). In the final histopathology examination, caseous necrosis associated with Langhan's giant cells and epithelial cells was observed. After the operation, the levels of CA 125 (16 U/mL) and CA 19.9 (21 U/mL) returned to normal.

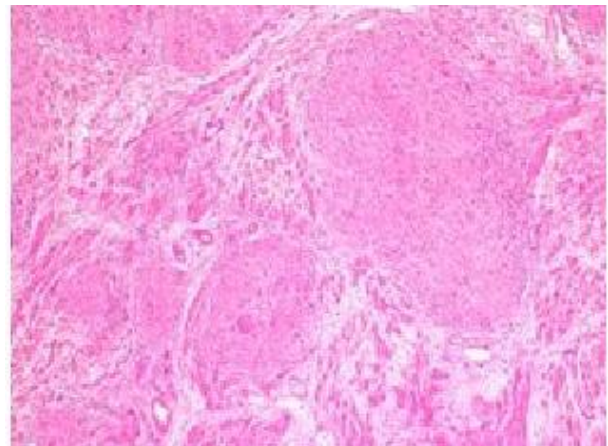


**Figure-1.** The computed tomography appearance of fluid within the uterine cavity.

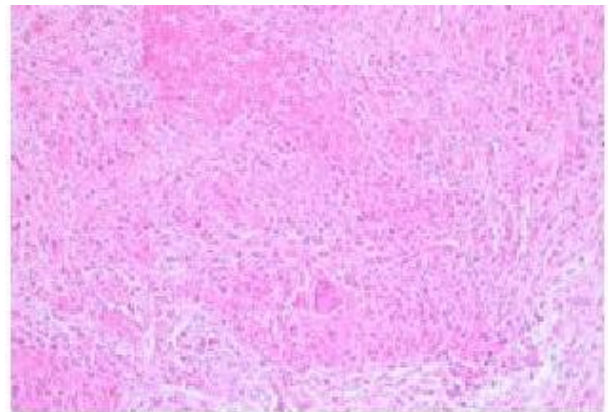
Other tests were then performed. A culture for *M. tuberculosis* and Ziehl-Neelsen stain for acid-fast bacilli of the peritoneal fluid remained negative. A tuberculin test was positive at 25 mm. Chest X-ray imaging excluded the thorax/lungs as a possible primary site of tuberculosis. Thus, the likely diagnosis of the case was genital tuberculosis. The patient was discharged four days after the operation and received anti-tuberculosis treatment for eight months. She had no complaint at her postoperative 1 year control.

### Discussion

According to the World Health Organization (WHO) report, one third of the whole world population is infected with the tuberculosis bacillus and it remains an important health care issue worldwide (5). Pulmonary tuberculosis is the most common form. Pulmonary tuberculosis may be accompanied by extra-pulmonary tuberculosis (EPTB) in 12-75% of patients (6). Genital localization of tuberculosis is rare. Genital tuberculosis in females occurs secondary to primary (usually lung) disease. Spreading from the primary site usually occurs by blood or lymph.



**Figure-2.** Granulomatous formations of various sizes in the myometrium, with necrotic foci showing a fusion tendency (hematoxylin-eosin x 100).



**Figure-3.** Caseous necrosis in the center and Langerhan's type multi-nucleated giant cells in the walls of granulomas (hematoxylin-eosin x 200).

The most common clinical symptom of genital tuberculosis is infertility (7). In women of reproductive age, the most common presenting symptoms are menstrual disturbance, oligo-amenorrhea or pelvic pain. Postmenopausal women may present with postmenopausal bleeding, pyometra or leukorrhea (3).

The diagnosis of tuberculosis can be done if the following conditions are present: (1) a positive acid-fast bacilli (AFB) of smear or culture; (2) histopathology showing tubercular granuloma (with or without caseation); (3) radiological features compatible with tuberculosis on abdominal barium X-rays, abdominal ultrasound, or abdominal computed tomography (CT); and (4) patients with a high index of clinical suspicion and negative diagnostic workup who nevertheless showed a good response to a therapeutic trial of anti-tuberculosis medications (8). In our case, diagnosis was based on histopathologic findings of the hysterectomy sample. The Montoux test (tuberculin skin test) has a sensitivity of 55% with a specificity of 80% in female genital TB. The typical lesions in genital TB are

epitheloid cell granulomas with or without Langerhans giant cells and are necessary for diagnosing genital tuberculosis. The presence of epitheloid cell granulomas can be in different stages. The treatment of genital tuberculosis is the same as lung tuberculosis (8).

The causes of pyometra are various. Chan et al. reported that pyometra was revealed as follows; 6 (22.2%) cases were associated with malignancy, 1 (3.7%) was associated with genital tract abnormality, and 20 (74.1%) were idiopathic (1). The diagnosis of pyometra is difficult because it is usually asymptomatic. The classic triad of symptoms in patients with pyometra consists of purulent vaginal discharge, postmenopausal bleeding and lower abdominal pain. Spontaneous perforation with diffuse peritonitis is very rare, and the incidence is 0.01-0.05% (3,8). Ruptured pyometra is rare but should be considered in the differential diagnosis of acute abdomen in elderly women, especially those with malignant disorders of the genital tract (9).

Dilatation and drainage is a treatment choice for pyometra, and regular monitoring after the initial treatment is warranted to detect persistent and recurrent disease (1). Many women are treated with cervical dilation and pus drainage. Pyometra sometimes requires hysterectomy. Pyometra can recur; hence regular monitoring is necessary. Antibiotics should be given if there is an invasive infection characterized by generalized malaise, pyrexia or altered laboratory parameters. A total hysterectomy along with bilateral salpingo-oophorectomy and thorough drainage with irrigation of the abdominal cavity remain the preferred immediate treatment in an emergency. Postoperatively, broad spectrum antibiotics and intensive care can help in recovery, followed by definitive management according to the etiology. Cases of pyometra, which are not associated with malignancy, have a better prognosis (1). Early diagnosis of pyometra and prompt treatment will

have a better prognosis. Anti-tuberculous chemotherapy is a treatment for tubercular pyometra (1).

The CA125 level is a very useful tumor marker in the treatment monitoring of epithelial ovarian cancer, but it can also be elevated in a series of benign gynecological conditions such as pelvic infections, tuberculosis, Meigs syndrome, and endometriosis. In cases of an elevated serum CA125 level in a woman with a pelvic mass, ovarian cancer should be considered unless proven otherwise. Pelvic tuberculosis may mimic ovarian malignancy and the CA-125 level may be falsely elevated (4,9,10). Therefore, physicians should be aware that CA125 is a nonspecific epithelial tumor marker. Thus, pelvic tuberculosis should be considered in the differential diagnosis of pelvic malignancy. There is also literature suggesting that certain tumor markers such as CA125 are used both in diagnosis of TB and in evaluation of the efficacy of treatment.

Elevation of CA 19-9 occurs in pancreatic, gastric and hepatobiliary malignancies. Benign conditions associated with the elevation of CA 19-9 include pneumonia, renal failure, miliary tuberculosis and autoimmunity (11). Takayama et al. found an association between serum CA 19-9 levels and benign pulmonary diseases (12). Tascı et al. reported no significant association between the disease activity and the response to treatment (10).

In conclusion, if tubercular pyometra is suspected, a diagnosis can be confirmed by tuberculin testing, histology or PCR. Genital Tuberculosis should be considered for differential diagnosis, particularly in elderly women, with pyometra and elevated serum CA125 and CA 19-9 levels. During laparotomy, frozen sections may rule out malignancy and an intraoperative frozen section is recommended when the diagnosis is in doubt.

## References

1. Chan LY, Lau TK, Wong SF, Yuen PM. Pyometra. What is its clinical significance? *J Reprod Med* 2001;46(11):952-6.
2. Carter JR. Unusual presentations of genital tract tuberculosis. *Int J Gynaecol Obstet* 1990;33(2):171-6.
3. Chow TW, Lim BK, Vallipuram S. The masquerades of female pelvic tuberculosis: Case reports and review of literature on clinical presentations and diagnosis. *J Obstet Gynaecol Res* 2002;28(4):203-10.
4. Bilgin T, Karabay A, Dolar E, Develioglu OH. Peritoneal tuberculosis with pelvic abdominal mass, ascites and elevated CA125 mimicking advanced ovarian carcinoma: A series of 10 cases. *Int J Gynecol Cancer* 2001;11(4):290-4.
5. World Health Organisation, Treatment of Tuberculosis. Guidelines for National Programmes. Geneva; 1997.
6. Sharma SK, Mohan A. Extrapulmonary tuberculosis. *Indian J Med Res* 2004;120(4):316-53.
7. Çetin MT, Demir CS, Kadayıfçı O, Kurdoğlu N. Neglected disease; genital tuberculosis. *J Turkish German Gynecol Assoc* 2006;7(2):94-97.
8. Saracoglu OF, Mungan T, Tanzer F. Pelvic tuberculosis. *Int J Gynaecol Obstet* 1992;37(2):115-20.
9. Straughn JM, Robertson MW, Partridge EE. A patient presenting with a pelvic mass, elevated Ca-125 and fever. *Gynecol Oncol* 2000;77(3): 471-2.
10. Tascı C, Ozkaya S, Ozkara B, et al. The utility of tumor markers CA 125, CA 15-3, and CA 19-9 in assessing the response to therapy in pulmonary and pleural tuberculosis. *Onco Targets Ther* 2012;5(4):385-90.
11. Pavai S, Yap SF. The clinical significance of elevated levels of serum CA 19-9. *Med J Malaysia* 2003;58(5):667-72.
12. Takayama S, Kataoka N, Usui Y, et al. CA 19-9 in patients with benign pulmonary diseases. *Nihon Kyobu Shikkan Gakki Zasshi* 1990;28(10):1326-31.