

The protective effect of syringic acid on ischemia injury in rat brain

Mustafa GÜVEN^{1*}, Adem Bozkurt ARAS¹, Naci TOPALOĞLU², Adile ÖZKAN³, Halil Murat ŞEN³,
Yıldırım KALKAN⁴, Ali OKUYUCU⁵, Ayla AKBAL⁶, Ferhat GÖKMEN⁶, Murat COŞAR¹

¹Department of Neurosurgery, Faculty of Medicine, Çanakkale Onsekiz Mart University, Çanakkale, Turkey

²Department of Pediatrics, Faculty of Medicine, Çanakkale Onsekiz Mart University, Çanakkale, Turkey

³Department of Neurology, Faculty of Medicine, Çanakkale Onsekiz Mart University, Çanakkale, Turkey

⁴Department of Histology and Embryology, Faculty of Medicine, Recep Tayyip Erdoğan University, Rize, Turkey

⁵Department of Medical Biochemistry, Faculty of Medicine, Ondokuz Mayıs University, Samsun, Turkey

⁶Department of Physical Therapy and Rehabilitation, Faculty of Medicine, Çanakkale Onsekiz Mart University, Çanakkale, Turkey

Received: 13.02.2014 • Accepted: 10.05.2014 • Published Online: 12.01.2015 • Printed: 09.02.2015

Background/aim: Brain ischemia and treatment are important topics in neurological science. Free oxygen radicals and inflammation formed after ischemia are accepted as the most significant causes of damage. Currently there are studies on many chemopreventive agents to prevent cerebral ischemia damage. Our aim is to research the preventive effect of the active ingredient in syringic acid, previously unstudied, on oxidative damage in cerebral ischemia.

Materials and methods: The rats were randomly divided into 4 groups: control group (no medication or surgical procedure), sham group (artery occlusion), artery occlusion + syringic acid group sacrificed at 6 h, and artery occlusion + syringic acid group sacrificed at 24 h. Obtained brain tissue from the right hemisphere was investigated histopathologically and for tissue biochemistry.

Results: Superoxide dismutase and nuclear respiratory factor 1 values decreased after ischemia and they increased after syringic acid treatment, while increased malondialdehyde levels after ischemia were reduced after treatment. Caspase-3 and caspase-9 values increased after ischemia and decreased after treatment; this reduction was more pronounced at 24 h.

Conclusion: Our study revealed that syringic acid treatment in cerebral ischemia reduced oxidative stress and neuronal degeneration. In the light of the biochemical and histopathologic results of the present study, we think that syringic acid treatment may be an alternative treatment method.

Key words: Brain ischemia, syringic acid, rats, oxidative stress, apoptosis

1. Introduction

Brain ischemia is still a serious clinical problem that may lead to permanent neurological deficits and serious complications. Contusion, the initial mechanical damage, may cause edema and pressure causes brain cell death and produces permanent damage. If pressure is removed or continues after the primary injury, the capillary permeability of the damaged area and surroundings increases; with the effect of reactive oxygen species (ROS) and inflammation, more dramatic results may occur due to secondary damage (1). To prevent ischemia and later damage, current studies have been and continue to be conducted on many chemopreventive agents.

Polyphenols, naturally found in many plants, have antiinflammatory and immunomodulatory effects and are known to show antioxidant effects, cleaning out ROS formed by cellular damage and oxidative stress. Simonyi

et al. (2) showed the neuroprotective effect of polyphenols on cerebral ischemic lesions. Studies on a polyphenolic derivative of benzoic acid (2,3), syringic acid (SA), have shown it to have chemoprotective (4) and antimicrobial (5) activity. In addition, Morton et al. (6) showed that SA was a strong inhibitor of low-density lipoprotein oxidation, supporting the scavenging of free radicals, reducing production of malondialdehyde, and thus slowing atherosclerosis.

There are no studies on the effects of SA on brain ischemia found in the literature. The aim of this study was to investigate the preventive effect of the active ingredient in SA, a member of the polyphenol group with known antioxidant properties, on injury due to brain ischemia. SA may provide a novel and promising therapeutic strategy for treatment of human cerebral ischemia via antioxidants and antiapoptotic effects.

* Correspondence: drmustafagüven@comu.edu.tr

2. Materials and methods

2.1. Experimental animals and study groups

This study used 32 male Sprague Dawley rats weighing 270–320 g. All animals were fed ad libitum with 7–8 mm pellet rat food (Bil-Yem Ltd., Turkey) and tap water. To provide a 12 h darkness, 12 h light environment, photoperiodic white fluorescent light was used and the temperature and humidity were held at 21 ± 2 °C and 55%–60%, respectively. The methods used for animal experiments were in accordance with the National Institute of Health Guide for the Care and Use of Laboratory Animals protocols. Permission was granted by the Çanakkale Onsekiz Mart University Animal Experiments Local Ethics Committee (No: 2012/08-16). The rats were randomly divided into 4 groups of 8. Group 1 was the control group (n = 8, no medication or surgical procedure), Group 2 was the sham group (n = 8, intraperitoneal single dose of 1 mL of 10% ethanol and middle cerebral artery occlusion (MCAO), sacrificed at 24 h), Group 3 was the MCAO + SA group sacrificed at 6 h (n = 8, 10 mg/kg SA intraperitoneally), and Group 4 was MCAO + SA group sacrificed at 24 h (n = 8, 10 mg/kg SA intraperitoneally). Before the rats were sacrificed, a craniotomy was performed and the complete brain was obtained, and then they were sacrificed. At the end of the experiment all animals were deeply anesthetized with ketamine (50–60 mg/kg) and decapitated. Brain tissue was investigated histopathologically and immunohistochemically.

2.2. Surgical procedure

All groups were anesthetized with 5 mg/kg xylazine (Bayer, Turkey) and 50 mg/kg ketamine hydrochloride (Parke Davis, Turkey) with spontaneous respiration and at room temperature. The rats were incised under sterile conditions on the operating table in the supine position with a right paramedian skin and subdermis incision in the neck. Using the previously described intraluminal filament technique, MCAO with focal cerebral ischemia was induced (7). To induce MCAO, a 4/0 nylon monofilament suture material (Ethilon Inc., USA) was advanced intraluminally through a small incision in the internal carotid artery until 18 mm distal to the right carotid bifurcation. Five minutes after MCAO was induced, the rats were given 10 mg/kg SA intraperitoneally (Groups 3 and 4; SA was obtained from Sigma-Aldrich's Turkish distributor, İnterlab). Neurological examinations at hours 6 and 24 were completed using a scoring system described by Bederson and modified by Kawamura (8). At the end of hour 6 Group 3 and at the end of hour 24 Groups 1, 2, and 4 were given a high dose of anesthetic material (ketamine, 50 mg/kg) and sacrificed. Immediately before sacrifice, the brains of the rats were obtained by craniotomy. The tissue was stored in 4% paraformaldehyde solution as previously described (9). The right hemisphere with MCAO was sent to the

laboratory for histopathological examination and tissue biochemical investigation (malondialdehyde (MDA), superoxide dismutase (SOD), and nuclear respiratory factor 1 (NRF1)).

2.3. Tissue MDA levels

MDA levels were analyzed for lipid peroxidation products and results were expressed as MDA nmol/g tissue (10). MDA levels were obtained using the ELISA method.

2.4. Tissue SOD activity

Tissue SOD activity was measured with a modified spectrophotometric method at 560 nm as described by Sun et al. (11). SOD activity was reported as U/mg protein.

2.5. NRF1 assays

NRF1 activates the expression of some key genes regulating cell growth and nuclear genes necessary for both mitochondrial DNA transcription and replication as well as heme biosynthesis and respiration. NRF1 controls the apoptosis, proliferation, migration, cellular distribution, and adhesion of target genes. NRF1 levels were measured with the ELISA method (12,13). Results are reported as ng mL⁻¹ mg protein⁻¹.

2.6. Histopathological investigation

The brains were labeled and left in 10% neutral formaldehyde solution. After 24 h in fixative, they were washed for 6–8 h in running water and rinsed with an ethanol-xylene series for automatic tissue tracking (Citadel 2000, Thermo Fisher Scientific Shandon, UK), and they were submerged in liquid paraffin. Sections 4–6 µm in thickness were cut for routine hematoxylin and eosin and Luxol fast blue staining, and sections 3–4 µm in thickness were cut for immunohistochemical staining. At appropriate places under light microscope at different magnifications, they were examined and photographed. Sections made for immunohistochemical staining were left in xylene for 20 min after rinsing with alcohol (70%–99%), and were then left in 3% H₂O₂ solution for 10 min. After washing with PBS they were heated 4 times at 700–800 W for 5–10 min in citrate buffer solution and left in secondary blocking material for 20 min. Different primary antibody dilutions (1/200–1/250) of every preparation (anticaspase-3 antibody (ab4051) and anticaspase-9 antibody [E23] (ab32539), Abcam plc, UK) were left for 60–75 min. Chromogeneous diaminobenzidine solution was used for contrast staining and Mayer's hematoxylin stain was also used. PBS was used for negative controls. The preparations were covered with an appropriate capping material and photographed. Results of immunohistochemical staining tissues were evaluated as % area of immunopositive reaction in 4 different categories: mild (+), moderate (++), severe (+++), and very severe (++++). Preparations with hematoxylin stain were examined in 15 different areas. Each area was 1200 µm, with remaining neuronal cells in the area counted to determine cell density.

2.7. Statistical evaluation

SPSS 19.0 (SPSS Inc., USA) was used for statistical analysis. Statistical analysis data are expressed as mean \pm SD. The comparisons among pre- and postoperation or drugs were made by using paired t-tests; comparisons between 2 groups were made with unpaired t-tests. The comparisons among the 4 groups were made using one-way analysis of variance followed by Bonferroni posttests. Histopathological findings were evaluated with the Kruskal–Wallis test as they were nonparametric. Statistical significance was accepted as $P < 0.05$.

3. Results

The means and standard deviations of SOD, MDA, and NRF1 values in the groups are given in Table 1.

Comparing the control group to the other groups, the SOD values were reduced, and this was found to be statistically significant ($P < 0.05$). There was a statistically significant difference between the ischemia group and all other groups ($P < 0.05$), with no significant difference observed between the 6 and 24 h groups ($P > 0.05$).

Comparing MDA values between the control group and other groups, the MDA values increased, and this was observed to be statistically significant ($P < 0.05$). In the ischemia group there was a significant difference between the other groups ($P < 0.05$), and only in the 6 and 24 h groups was the difference not significant ($P > 0.05$).

NRF1 values were reduced in the other groups compared to the control group and this was statistically significant ($P < 0.05$). There was a significant difference between the ischemia group and all other groups ($P < 0.05$). Only in the 6 and 24 h groups was this difference not significant ($P > 0.05$).

In the control group, no cellular structure or tissue injury was observed in brain tissue examined with immunohistochemical and hematoxylin and eosin staining for histopathology; neurons and neuroglia with normal morphology and histological appearance were

identified. Only in the sham ischemia group given alcohol were focal ischemia lesions observed in both hemispheres, though more so on the right side (Figure 1).

Hematoxylin and eosin staining in the sham ischemia group showed that neuronal death was increased, acidophilic neuronal cytoplasm in cells was reduced in size and had pyknotic shape, and severe vacuolization had developed. Histomorphometric red neurons were observed to appear as karyorrhexis-damaged neurons moving from the cortex regions towards the center (Figure 1).

In the SA (6 h) group, while a negligible increase in red neuron cell counts was observed compared to the control group, there was a significant reduction compared to the sham ischemia group.

Cells in the sham ischemia group stained with Luxol fast blue showed slightly darker blue color for pyramidal neurons compared to the control group and severe vacuolization and edema formed around both granular and pyramidal neurons (Figure 2).

In the SA (24 h) group, red neuron cell counts were higher than in the control group. While the cellular degeneration was most severe in the sham ischemia group, it was reduced in the SA groups; however, it was not fully resolved (Table 2).

Immunoperoxide staining showed edema and microglial cell clusters around damaged areas in brain tissue in the ischemia groups. Although edema was observed in various regions of the hippocampus, it was more often present surrounding granular cells. In areas near the hippocampus, the observed microglial cells and lymphocyte infiltration were at minimal levels.

Caspase-3 immunoactivity was increased, especially in the cortex and external granular layers. Immunoreactivity was observed to be greater in situations with alcohol and long-term ischemia. In the ischemic region, dense groupings of apoptotic cells were identified (Figure 3; Table 3).

Table 1. The activity of superoxide dismutase (SOD) and levels of malondialdehyde (MDA) and nuclear respiratory factor-1 (NRF1).

Groups	SOD (U/mg protein)	MDA (nmol mL ⁻¹ mg protein ⁻¹)	NRF1 (nmol mL ⁻¹ mg protein ⁻¹)
Group 1	7.2 \pm 0.88	0.3 \pm 0.12	2.8 \pm 0.67
Group 2	1.8 \pm 0.33 ^a	2.1 \pm 0.29 ^a	0.3 \pm 0.11 ^a
Group 3	4.2 \pm 0.97 ^{b,d}	1.1 \pm 0.34 ^{b,d}	1.3 \pm 0.19 ^{b,d}
Group 4	3.7 \pm 0.90 ^{c,e}	1.2 \pm 0.40 ^{c,e}	1.2 \pm 0.24 ^{c,e}

Data are expressed as mean \pm SD. Significant difference between groups was analyzed by one-way ANOVA, where: ^{a,b,c}, $P < 0.05$ compared to Group 1 (control group); ^{d,e}, $P < 0.05$ compared to Group 2 (sham group).

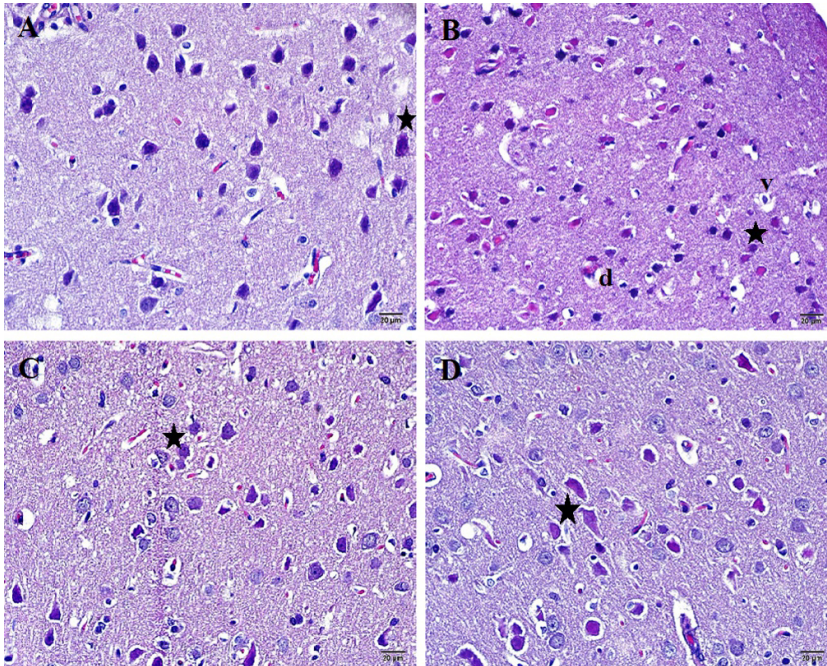


Figure 1. Representative photomicrographs showing neurons, astrocytes, and microglial cells stained with hematoxylin and eosin in the ischemic brain area of rats after 6 h and 24 h of MCA occlusion. **A)** Control group, **B)** MCAO group, **C)** MCAO + SA (10 mg/kg body wt., i.p.) group, sacrificed after 6 h; **D)** MCAO + SA (10 mg/kg body wt., i.p.) group, sacrificed after 24 h. Red neurons are shown with stars. Vascular dilatation (d) and vacuolization (v) are shown. Scale bars = 20 µm.

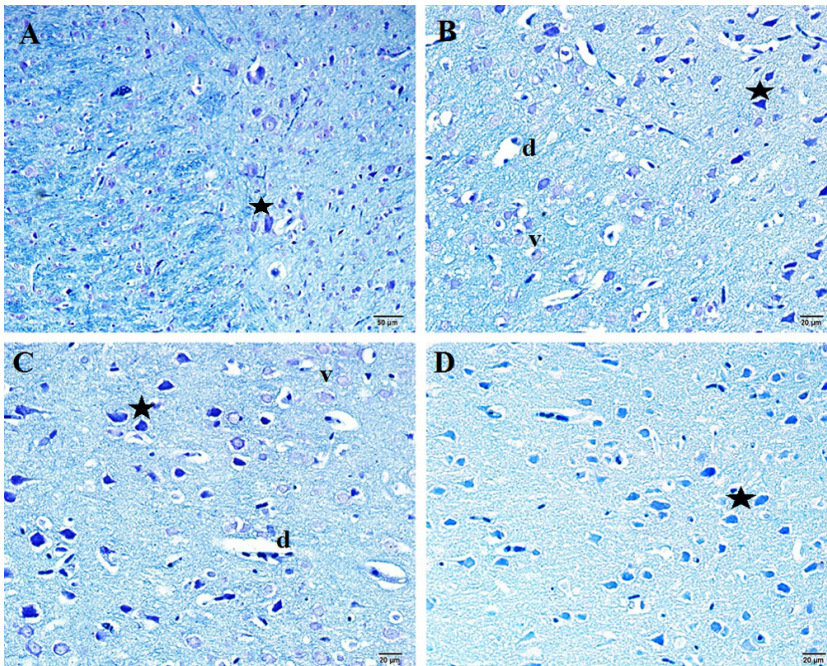


Figure 2. Representative photomicrographs showing neurons, astrocytes, and microglial cells stained with Luxol fast blue in the ischemic brain area of rats after 6 h and 24 h MCA occlusion. **A)** Control group; **B)** MCAO group; **C)** MCAO + SA (10 mg/kg body wt., i.p.) group, sacrificed after 6 h; **D)** MCAO + SA (10 mg/kg body wt., i.p.) group, sacrificed after 24 h. Red neurons are shown with stars. Vascular dilatation (d) is shown. Scale bars = 20 µm.

Table 2. Histopathological findings for all groups. Neuronal cells in the area were counted to determine cell density.

Groups	Red neuron	Vacuolization	Cellular degeneration	Edema
Group 1	1.0 ± 0.46	1.0 ± 0.00	1.0 ± 0.00	0.0 ± 0.46
Group 2	4.0 ± 0.76 ^a	3.0 ± 0.53 ^a	3.0 ± 0.00 ^a	3.0 ± 0.64 ^a
Group 3	2.0 ± 0.64 ^{b,d}	2.0 ± 0.35 ^{b,d}	1.0 ± 0.00 ^{b,d}	1.0 ± 0.74 ^{b,d}
Group 4	3.0 ± 0.00 ^{c,e,f}	2.0 ± 0.53 ^{c,e}	2.0 ± 0.00 ^{c,e,f}	1.0 ± 0.74 ^{c,e}

Data are expressed as median ± SD. Significant difference between groups was analyzed by Kruskal–Wallis test, where: ^{a,b,c}, $P < 0.05$ compared to Group 1 (control group); ^{d,e}, $P < 0.05$ compared to Group 2 (sham group); ^f, $P < 0.05$ compared to Group 3 (ischemia-SA (6 h) group).

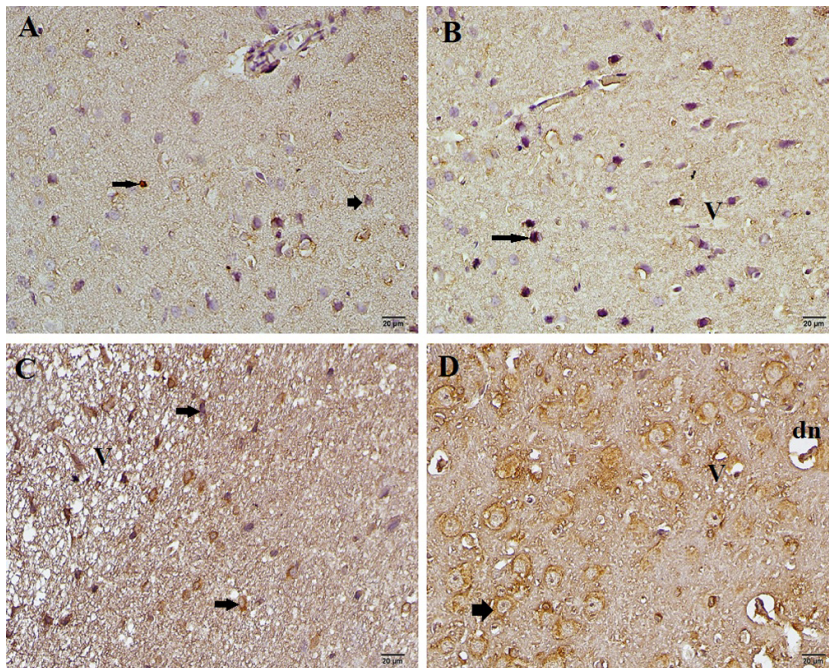


Figure 3. Effects of SA on caspase-3 expression in the ischemic brain site by immunohistochemical methods at 6 h and 24 h after experimental stroke. Representative examples of caspase-3 immunohistochemical images in ischemic brain sections are shown in the control group (A), sham-operated (vehicle) group (B), MCAO + SA (6 h) group (10 mg/kg, i.p.) (C), and MCAO + SA (24 h) group (10 mg/kg, i.p.) (D). Caspase-3 expression in neurons (black arrows) is shown. Vacuolization (v) and neuronal degeneration (dn) are also shown. Scale bars = 20 μ m.

Staining of brain tissue with immunoperoxidase showed reduction in the caspase-3 positivity toward white matter. Along the zone, different cells were observed to have different rates of immune reactivity. Along the cortex and subcortex, glial cells were identified to have strong caspase-3-positive immunoreactivity. In the hippocampus CA1 region, caspase-3 immunoreactivity was observed to be greater in the cytoplasm of granular cells (Figure 3).

In the group administered alcohol after cerebral ischemia, neuronal degeneration was determined with severe caspase-9 positivity. In the 6 h ischemia group,

the immunopositivity for caspase-9 was slightly greater than in the 24 h group. In the large ventricular zone surrounding cortical neurons, caspase-9 staining showed immunopositivity in the shape of rings (Figure 4; Table 3).

Neurons in the external granular layer and pyramidal cell layers were observed to have varying rates of immunopositivity. The most sensitive area for ischemia was the CA1 region, with the CA3 and dentate gyrus regions identified to have cell structures and morphology more resistant to apoptosis. In the CA1 and CA2 regions of the hippocampus, cells showed high immunoreactivity

Table 3. Anticaspase-3 and anticaspase-9 immunoperoxidase staining results for all groups.

Groups	Anticaspase-3	Anticaspase-9
Group 1	1.0 ± 0.35	1.0 ± 0.46
Group 2	4.0 ± 0.53 ^a	4.0 ± 0.74 ^a
Group 3	2.0 ± 0.46 ^{b,d}	3.0 ± 0.74 ^{b,d}
Group 4	1.0 ± 0.46 ^{c,e,f}	2.0 ± 0.88 ^{c,e}

Data are expressed as median ± SD. Significant difference between groups was analyzed by the Kruskal–Wallis test, where: ^{a, b, c}, $P < 0.05$ compared to Group 1 (control group); ^{d, e}, $P < 0.05$ compared to Group 2 (sham group); ^f, $P < 0.05$ compared to Group 3 (ischemia-SA (6 h) group).

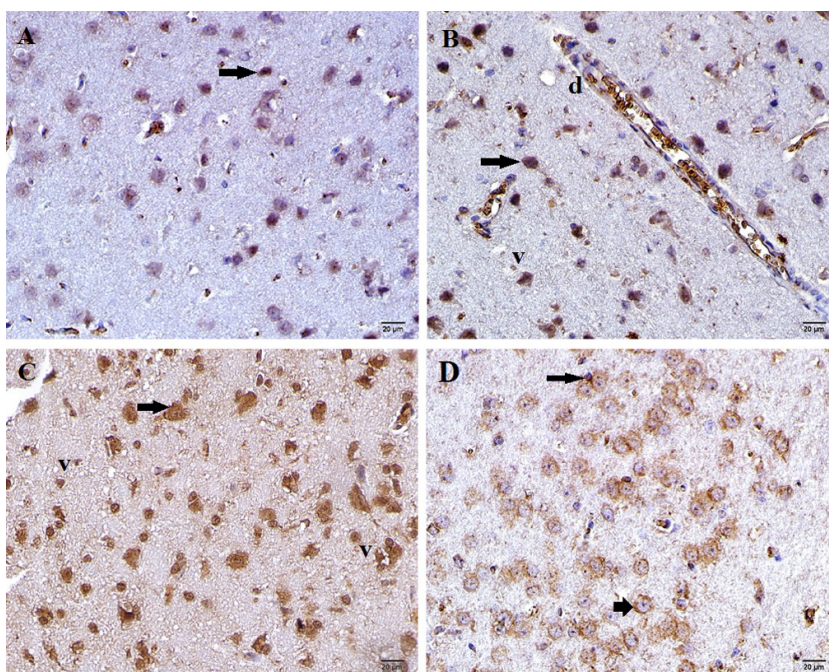


Figure 4. Effects of SA on caspase-9 expression in the ischemic brain site by immunohistochemical methods at 6 h and 24 h after experimental stroke. Representative examples of caspase-9 immunohistochemical images (black arrows) in ischemic brain sections are shown in the control group (A), sham-operated (vehicle) group (B), MCAO + SA (6 h) group (10 mg/kg, i.p.) (C), and MCAO + SA (24 h) group (10 mg/kg, i.p.) (D). Caspase-9 expression in neurons (black arrows) is shown. Vacuolization (v) and dilatation (d) are shown. Scale bars = 20 μm.

to caspase-9, while in the CA3–CA4 region and the dentate gyrus area the cells were observed to have mild immunopositivity.

4. Discussion

To reduce neuronal damage caused by cerebral ischemia, experimental studies of many possible protective agents have been completed. In our study, a polyphenol that can be obtained naturally from plants, SA, was used. In the induced cerebral ischemia model in rats, SA was shown histopathologically to have a protective effect on the

ischemic brain area. In addition, after treatment MDA was decreased and SOD and NRF1 values increased in biochemical tests, showing a reduction in the formation of oxidative stress after ischemia.

In spite of developments in treatment of acute strokes, deaths due to stroke are still the third highest cause of death in many countries. In addition, strokes are first in terms of morbidity and cause large economic losses. As a result, the timely and successful treatment of strokes is very important. If the blood flow in the brain reduces by more than 20%, the ATP in brain tissue is quickly consumed

and anoxic depolarization waves form. As a result of this, the amount of calcium within cells increases. Increased calcium may cause activation of catabolic enzymes such as protease, kinase, endonuclease, and phospholipase. The increasing calcium within the cells may also cause edema and functional disruption in mitochondria, destroying the energy source of the cell. Free oxygen radicals formed during the ischemic process, along with nitric oxide and peroxynitrite, trigger apoptotic and necrotic cell death through a variety of pathways (14,15).

Excessive free oxygen radicals formed during the ischemic process react with polyunsaturated fat acids and cause lipid peroxidation (16). MDA is the end product of lipid peroxidation and at the same time is accepted as one of the most sensitive markers of lipid peroxidation (17–19). In a study by Karaođlan et al. (20), temporary forebrain ischemia caused an 80% increase in tissue MDA levels; they found that this increase reduced by 43% with treatment with tirofiban, a glycoprotein receptor blocker. Cirak et al. (21) showed that after head trauma, the tissue MDA levels in rat brains increased in the first 2 h; as time passed it reduced and the use of melatonin reduced serum MDA levels. In our study of rats with induced cerebral ischemia, MDA values were reduced after SA treatment. There was no significant difference between values 6 and 24 h after ischemia.

SOD, an endogenous mitochondrial antioxidant enzyme, is a free radical scavenger that turns superoxide radicals created by cerebral ischemia into less reactive hydrogen peroxide forms. In increased oxidative stress situations, SOD is neutralized by H_2O_2 and other radicals and thus levels are reduced. In an experimental model in rats, Islekel et al. (22) showed that SOD activity was clearly reduced after cerebral ischemia. Both Deng et al. (23) and Karaođlan et al. (20) reported that tissue SOD activity fell after cerebral ischemia, while after treatments such as 3,6-dimethamidodibenzopyridonium gluconate and tirofiban tissue, SOD activity rose again. Kumar et al. (24) showed that decreasing SOD activity increased markedly after SA treatment in hypertensive rats. The main mechanism of the 50 mg/kg dose of SA treatment was associated with antioxidant effect in this study. In our study, after SA treatment the rise in SOD values indicated a reduction in oxidative stress. This supports the view that SA has antioxidant properties.

Mitochondria are important regulators of the metabolic activity of cells while also enabling production and breakdown of free radicals. Mitochondrial biogenesis is activated in response to cellular stress or environmental stimuli by many different signals. NRF1 and NRF2 are mitochondrial transcription factors that activate the majority of genes coding subunits of the respiratory complex. Kumari et al. (25) induced cerebral ischemia/

reperfusion in normal and hyperglycemic rats and showed that after the reperfusion period NRF1 levels increased. In our study, which simulated an embolism in the human brain, the intraluminal filament was not retracted to allow reperfusion. NRF1 values, a marker for mitochondrial biogenesis, were reduced in the MCAO group. In the ischemic groups with SA treatment, a significant increase was observed. In accordance with our study, in the literature the increase in NRF1 values in the ischemia/reperfusion groups was in proportion with the reperfusion time and was shown to increase further with the use of neuroprotective agents (12,13,25,26) (Table 1).

In ischemic stroke, apoptosis may begin by 2 paths: intrinsic or extrinsic. Cytochrome c and caspase-3 stimulation triggered by mitochondria forms the intrinsic pathway (27). Caspase-3 and caspase-9 are known to be important in apoptosis caused by ischemia of neuronal cells. Studies of apoptotic neuronal cells found that caspase-3 may be activated by both intrinsic and extrinsic signal pathways and as a result supported the idea that caspase-3 plays a key role in ischemic stroke apoptosis (28). Activated caspase-3 causes breakdown of DNA (29). Some studies have shown a relationship between DNA breakdown and development of ischemic infarction (30). Li et al. (31), in a temporary focal cerebral ischemia model in rats, showed that caspase-3 and caspase-9 activity clearly increased compared to the control group, but this was not statistically significant. In our study, in the brain tissue along the cortex and subcortex, glial cells were identified to have positive immunoreactivity for caspase-3, while in the hippocampus CA1 region it was more pronounced in the cytoplasm of granular cells. Neuronal degeneration after cerebral ischemia was determined by severe caspase-9 positivity. Especially in the 6 h group after ischemia, caspase-9 immunopositivity was observed to be slightly greater than in the 24 h group (Figures 3 and 4).

Kim et al. (32) used 2 different doses of caffeic acid-SA treatment at 10 and 20 mg/kg in experimental cerebral ischemia. They observed moderate neuroprotective effects with 10 mg/kg and strong neuroprotective effects with 20 mg/kg in the hippocampus CA1 region. In the present study, it was shown that 10 mg/kg SA treatment had a neuroprotective effect both biochemically and pathologically, despite induced permanent cerebral ischemia.

In conclusion, data from our study support the view that in cerebral ischemia, SA treatment reduces neuronal degeneration as a result of oxidative stress and may be an alternative treatment. More comprehensive studies are definitely required.

Acknowledgment

The authors thank the director of the Çanakkale Onsekiz Mart University Experimental Research Center.

References

- Cernak I. Animal models of head trauma. *NeuroRx* 2005; 2: 410–422.
- Simonyi A, Wang Q, Miller RL, Yusof M, Shelat PB, Sun AY, Sun GY. Polyphenols in cerebral ischemia: novel targets for neuroprotection. *Mol Neurobiol* 2005; 31: 135–147.
- Scalbert A, Williamson G. Dietary intake and bioavailability of polyphenols. *J Nutr* 2000; 130: 2073S–2085S.
- Hudson EA, Dinh PA, Kokubun T, Simmonds MS, Gescher A. Characterization of potentially chemopreventive phenols in extracts of brown rice that inhibit the growth of human breast and colon cancer cells. *Cancer Epidemiol Biomarkers Prev* 2000; 9: 1163–1170.
- Cho JY, Moon JH, Seong KY, Park KH. Antimicrobial activity of 4-hydroxybenzoic acid and trans 4-hydroxycinnamic acid isolated and identified from rice hull. *Biosci Biotechnol Biochem* 1998; 62: 2273–2276.
- Morton LW, Croft KD, Puddey IB, Byrne L. Phenolic acids protect low density lipoproteins from peroxynitrite-mediated modification in vitro. *Redox Rep* 2000; 5: 124–125.
- Hata R, Mies G, Wiessner C, Fritze K, Hesselbarth D, Brinker G, Hossmann KA. A reproducible model of middle cerebral artery occlusion in mice: hemodynamic, biochemical, and magnetic resonance imaging. *J Cereb Blood Flow Metab* 1998; 18: 367–375.
- Kawamura S, Li Y, Shirasawa M, Yasui N, Fukasawa H. Reversible middle cerebral artery occlusion in rats using an intraluminal thread technique. *Surg Neurol* 1994; 41: 368–373.
- Bederson JB, Pitts LH, Germano SM, Nishimura MC, Davis RL, Bartkowski HM. Evaluation of 2,3,5-triphenyltetrazolium chloride as a stain for detection and quantification of experimental cerebral infarction in rats. *Stroke* 1986; 17: 1304–1308.
- Buege JA, Aust SD. Microsomal lipid peroxidation. *Methods Enzymol* 1978; 52: 302–310.
- Sun Y, Oberley LW, Li Y. A simple method for clinical assay of superoxide dismutase. *Clin Chem* 1988; 34: 497–500.
- Gutsaeva DR, Carraway MS, Suliman HB, Demchenko IT, Shitara H, Yonekawa H, Piantadosi CA. Transient hypoxia stimulates mitochondrial biogenesis in brain subcortex by a neuronal nitric oxide synthase-dependent mechanism. *J Neurosci* 2008; 28: 2015–2024.
- Yin W, Signore AP, Iwai M, Cao G, Gao Y, Chen J. Rapidly increased neuronal mitochondrial biogenesis after hypoxic-ischemic brain injury. *Stroke* 2008; 39: 3057–3063.
- Bontke CF, Boake C. Principles of brain injury rehabilitation. In: Braddom RL, editor. *Physical Medicine and Rehabilitation*. 1st ed. Philadelphia, PA, USA: W.B. Saunders; 1996. pp. 1027–1051.
- Greenwald BD, Burnett DM, Miller MA. Congenital and acquired brain injury. 1. Brain injury: epidemiology and pathophysiology. *Arch Phys Med Rehabil* 2003; 84: S3–7.
- Braughler JM, Hall ED. Central nervous system trauma and stroke. I. Biochemical considerations for oxygen radical formation and lipid peroxidation. *Free Radic Biol Med* 1989; 6: 289–301.
- Esterbauer H, Schaur RJ, Zollner H. Chemistry and biochemistry of 4-hydroxynonenal, malonaldehyde and related aldehydes. *Free Radic Biol Med* 1991; 11: 81–128.
- Gutteridge JM. Lipid peroxidation and antioxidants as biomarkers of tissue damage. *Clin Chem* 1995; 41: 1819–1828.
- Ohkawa H, Ohishi N, Yagi K. Assay for lipid peroxides in animal tissues by thiobarbituric acid reaction. *Anal Biochem* 1979; 95: 351–358.
- Karaođlan A, Uçankale MH, Barut S, Uzun H, Belce A, Çolak A. Neuroprotective effect of tirofiban on temporary brain ischemia in rats: a preliminary report. *Türk Nöroşirürji Dergisi* 2002; 12: 40–47 (in Turkish with English abstract).
- Cirak B, Rousan N, Kocak A, Palaoglu O, Palaoglu S, Kilic K. Melatonin as a free radical scavenger in experimental head trauma. *Pediatr Neurosurg* 1999; 31: 298–301.
- Islekel S, Islekel H, Guner G, Ozdamar N. Alterations in superoxide dismutase, glutathione peroxidase and catalase activities in experimental cerebral ischemia-reperfusion. *Res Exp Med (Berl)* 1999; 199: 167–176.
- Deng XL, Qian ZY, Liu NF, Ma XY, Wang HF, Hou ZJ. Antagonistic effect of 3,6-dimethamidodibenzopyridonium gluconate on lipid peroxidation in cerebral cortical neuronal cultures and rat brains during focal cerebral ischemia reperfusion. *Acta Pharmacol Sin* 2000; 21: 460–462.
- Kumar S, Prahalathan P, Raja B. Syringic acid ameliorates (L)-NAME-induced hypertension by reducing oxidative stress. *Naunyn Schmiedebergs Arch Pharmacol* 2012; 385: 1175–1184.
- Kumari S, Anderson L, Farmer S, Mehta SL, Li PA. Hyperglycemia alters mitochondrial fission and fusion proteins in mice subjected to cerebral ischemia and reperfusion. *Transl Stroke Res* 2012; 3: 296–304.
- Mehta SL, Kumari S, Mendelev N, Li PA. Selenium preserves mitochondrial function, stimulates mitochondrial biogenesis, and reduces infarct volume after focal cerebral ischemia. *BMC Neurosci* 2012; 13: 79.
- Broughton BR, Reutens DC, Sobey CG. Apoptotic mechanisms after cerebral ischemia. *Stroke* 2009; 40: e331–339.
- Porter AG, Janicke RU. Emerging roles of caspase-3 in apoptosis. *Cell Death Differ* 1999; 6: 99–104.
- Abas F, Alkan T, Goren B, Taskapilioglu O, Sarandol E, Tolunay S. Neuroprotective effects of postconditioning on lipid peroxidation and apoptosis after focal cerebral ischemia/reperfusion injury in rats. *Turk Neurosurg* 2010; 20: 1–8.
- Li P, Nijhawan D, Budihardjo I, Srinivasula SM, Ahmad M, Alnemri ES, Wang X. Cytochrome c and dATP-dependent formation of Apaf-1/caspase-9 complex initiates an apoptotic protease cascade. *Cell* 1997; 91: 479–489.
- Li Y, Chopp M, Jiang N, Yao F, Zaloga C. Temporal profile of in situ DNA fragmentation after transient middle cerebral artery occlusion in the rat. *J Cereb Blood Flow Metab* 1995; 15: 389–397.
- Kim IH, Yan BC, Park JH, Yeun GH, Yim Y, Ahn JH, Lee JC, Hwang IK, Cho JH, Kim YM et al. Neuroprotection of a novel synthetic caffeic acid-syringic acid hybrid compound against experimentally induced transient cerebral ischemic damage. *Planta Med* 2013; 79: 313–321.