

Özlem BİLİR<sup>1</sup>  
Gökhan ERSUNAN<sup>1</sup>  
Özcan YAVAŞI<sup>1</sup>  
Kamil KAYAYURT<sup>1</sup>  
Atıf BAYRAMOĞLU<sup>2</sup>

İletişim (Correspondance)

Özcan YAVAŞI  
Recep Tayyip Erdoğan Üniversitesi Eğitim ve Araştırma  
Hastanesi, Acil Tıp Kliniği RİZE

Tlf: 0464 217 03 66  
e-posta: ozcanyavasi@yahoo.com.tr

Geliş Tarihi: 18/11/2013  
(Received)

Kabul Tarihi: 06/02/2014  
(Accepted)

<sup>1</sup> Recep Tayyip Erdoğan Üniversitesi Eğitim ve Araştırma  
Hastanesi, Acil Tıp Kliniği RİZE  
<sup>2</sup> Atatürk Üniversitesi Tıp Fakültesi Acil Tıp Anabilim  
Dalı ERZURUM



CASE REPORT

## MAD HONEY POISONING PRESENTING AS TRANSIENT ISCHEMIC ATTACK

### ABSTRACT

Mad honey poisoning is a clinical state resulting from the ingestion of honey produced in the Black Sea region of Turkey. This honey is produced from the nectar of the Rhododendron Ponticum plant. Grayanotoxin is responsible for this cholinergic syndrome, presenting with either one or a combination of two or more of lightheadedness, weakness, diaphoresis, nausea, vomiting, salivation, depressed cognitive function, syncope, blurred vision, paresthesia in the perioral region or extremities, cyanosis and convulsions shortly following ingestion of mad honey. Hypotension and bradycardia are the most commonly seen signs of toxicity. Symptoms usually respond well to intravenous fluid replacement and atropine, and relieve within 24 hours. In this paper, we report a case of mad honey poisoning in a 67 years old patient who presented with weakness on his right side, mimicking transient ischemic attack.

**Key Words:** Honey; Poisoning; Toxicology; Ischemic Attack, Transient.



OLGU SUNUMU

## GEÇİCİ İSKEMİK ATAĞI ŞEKLİNDE ORTAYA ÇIKAN DELİ BAL ZEHİRLENMESİ

### Öz

Deli bal zehirlenmesi Türkiye'nin Doğu Karadeniz bölgesinde üretilen balın yenmesinden kaynaklanan klinik bir durumdur. Bu bal, Rhododendron Ponticum bitkisinin nektarından üretilir. Deli bal yenmesini takiben, sersemlik hissi, güçsüzlük, terleme, bulantı, kusma, tükürük salgılama, kognitif fonksiyonlarda baskılanma, senkop, bulanık görme, ağız çevresinde veya ekstremitelerde parestezi, siyanoz veya konvulziyondan biri veya iki ya da daha fazlasının birlikte görülmesiyle ortaya çıkan bu kolinerjik sendromdan grayanotoksin sorumludur. Hipotansiyon ve bradikardi en sık görülen zehirlenme bulgularıdır. Semptomlar genellikle intravenöz sıvı replasmanı ve atropine iyi cevap verir ve 24 saat içinde düzelir. Bu yazı kapsamında, sağ tarafında güçsüzlükle başvuran 67 yaşındaki hastada, geçici iskemik atakla taklit eden deli bal zehirlenmesi olgusu sunulmuştur.

**Anahtar Sözcükler:** Deli Bal; Zehirlenme; Toksikoloji; Geçici İskemik Atak.



## INTRODUCTION

Honey has both medicinal and poisonous properties. The toxic effect is associated with grayanotoxin in honey. Grayanotoxin containing honey, called “mad honey” is one of the oldest biological agents (1). Plants containing grayanotoxin, are found in different geographical regions in the world such as Turkey, Japan, Nepal, Brazil and North America. The intoxication signs occur after the ingestion of honey produced from the flower and nectar of *Rhododendron Ponticum*, which is also called ‘mountain flower’ in Turkey. As these toxins taken from rhododendron type plants cannot be detoxified by bees, they are directly blended into the honey, resulting in intoxication (2). Besides its nutraceutical values, there is a general belief that mad honey can act as an aphrodisiac, or as a treatment for gastritis, peptic ulcer, weakness, arthritis, diabetes, and hypertension and is commonly used in alternative medicine (1,3,4). This makes it attractive for elderly patients who are on multidrug medication for several accompanying diseases. Here we report a case of mad honey poisoning in a 67 years old patient who presented with weakness on his right side, mimicking transient ischemic attack.

## CASE REPORT

A 67 year old male patient was presented at our emergency department by emergency medical staff with complaining of weakness on his right extremities. From the history taken from his relatives it was learnt that he developed a sense of

fainting, nausea, vomiting, and loss of consciousness following ingestion of a spoonful of honey. 14 years and 9 months ago he had developed ischemic stroke, but he had been performing his daily activities without any sequela. His vital signs were as follows: arterial blood pressure, 60/40 mmHg; heart rate, 40 beats/minute; respiratory rate, 10/minute; and oxygen saturation, 89%. His general status was poor, non-cooperating, and non-oriented, with a Glasgow coma scale (GCS) score of 9 (E2,M5,V2). His pupils were isocoric but pinpoint. His neurological examination revealed 3/5 motor deficits on right upper and lower extremities and a positive Babinsky sign on the right. This unstable patient was monitored, an intravenous line placed, and oxygen started at a rate of 4 L/minute. His ECG showed sinus bradycardia (Figure 1 A). After 1 mg intravenous Atropine, a 0.9% saline infusion was started. Following this therapy, his symptoms started to recover gradually and GCS reached 13. His new blood pressure was 110/60 mmHg and heart rate 84 beats/minute (Figure 1B). After stabilization of the patient, a cranial tomography scan was ordered but did not show any pathological findings related to the clinical status of the patient except for a widening of cortical cerebral sulci secondary to atrophy and bilateral hypodense encephalomalacic gliotic changes in the temporoparietal regions. Cranial and diffusion magnetic resonance imaging (MRI) revealed the same results. Two hours later, he was cooperating, oriented, GCS was 15, Babinsky was negative and his motor deficit recovered except for paresthesia on the right side. There were no pathological findings in laboratory tests. He was admitted to

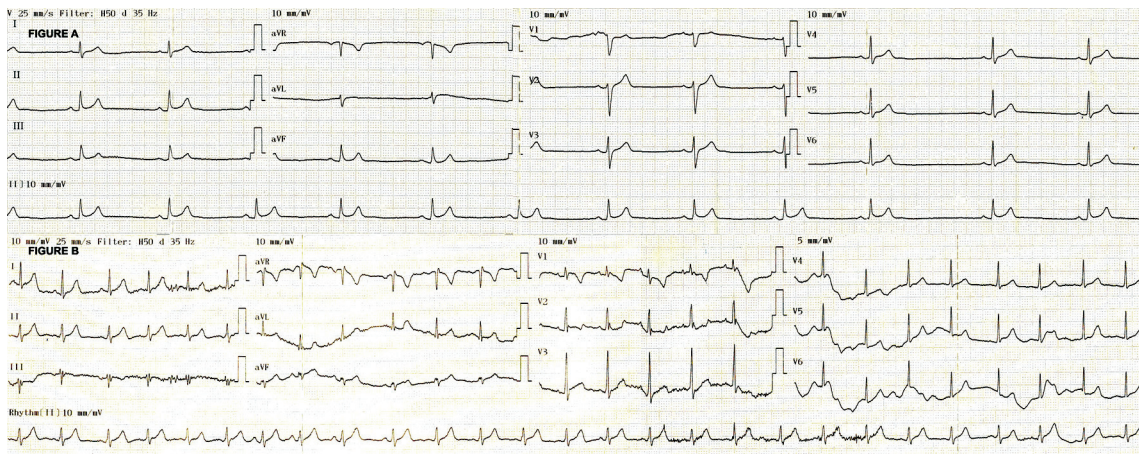


Figure 1— A, ECG trace showing sinus bradycardia at presentation. B, ECG trace showing normal sinus rhythm after therapy.



the intensive care unit for follow-up. His carotid artery Doppler showed only calcified plaques. After recovering from the paresthesia, the patient was discharged for ambulatory follow-up.

## DISCUSSION

Grayanotoxin-containing plants are found in different regions of the world, particularly in the eastern Black Sea region of Turkey. Although there are different forms of this toxin, the type responsible for the toxicity is Grayanotoxin I, also called andromedotoxin (2). Grayanotoxins are neurotoxins that block sodium channels in the cell membrane by affecting the conduction of action potential. The resulting effects are related to the activation and inactivation of the voltage gated sodium channels in the cell membrane. Thus, grayanotoxin inhibits inactivation of excitable cells, particularly nerve and muscle cells, by holding them in a depolarization state. In this period, calcium influx into the cell is facilitated. All events seen in the central nervous system, nerves, heart and skeletal muscles are the results of effects of the toxin on the cell membrane (5,6). The chain of events at the cellular level triggered by grayanotoxin resembles the changes in brain cells during ischemia. This is because, during ischemia and other energy deficient conditions such as hypoxia and stroke, the chain of events in neurons beginning with the insufficiency of the sodium/potassium pump is followed by cellular dysfunction, resulting from the opening of the calcium channels. Sodium/potassium pump dysfunction is often a major early pathological response, which leads to a loss in membrane potential and neuronal function (7).

The clinical picture of mad honey poisoning mimics cholinergic syndrome (6). Although this patient had meiosis, urine and gaita incontinence, nausea, vomiting, bradycardia, and hypotension as in cholinergic syndrome, actually it was a mad honey poisoning. The symptoms of intoxication are dose-related and occur acutely or after a latent period (2). The patients usually present with either one or a combination of two or more of lightheadedness, nausea, vomiting, diaphoresis, salivation, blurred vision, paresthesia in the perioral region or extremities, cyanosis shortly following ingestion. More serious forms may present with convulsion, depressed cognitive function, syncope, coordination disorder or progressive muscle weakness as in our case (1,8,9). Hypotension and bradycardia are the most commonly seen signs of toxicity (1,8-11). In the present case, besides neurological findings, hypotension and bradycardia were in the foreground. A tran-

sient ischemic attack is defined as “a transient episode of neurologic dysfunction caused by focal brain, spinal cord, or retinal ischemia, without acute infarction” (12). As diffusion MRI of the patient did not show any acute ischemic finding, the clinical state of the patient was considered to indicate a transient ischemic attack as a result of decrease in cerebral perfusion secondary to systemic hypotension induced by mad honey poisoning. Thus, the hypotension and neurological findings in the present case were resolved by fluid replacement.

Symptoms of mad honey poisoning usually respond well to intravenous fluid replacement and atropine, and relieve within 24 hours (1,8,10,11). Close cardiac monitorization is mandatory. Although patients with mild symptoms such as lightheadedness, weakness, diaphoresis, hypersalivation, paresthesia, nausea, and vomiting can safely be discharged after 2-9 hours of monitoring, there is no consensus on the duration of hospital observation for patients that were admitted because of poisoning (6,10).

As a result of an increase in natural product consumption recently, there may be an increase in mad honey poisoning in endemic areas. Emergency physicians should include mad honey ingestion in the differential diagnosis, in addition to primary cardiac and neurological disorders while dealing with a patient with unexplained bradycardia, hypotension and neurological symptoms in the ED and early resuscitative efforts should immediately be attempted.

## REFERENCES

- Demircan A, Keles, Bildik F, et al. Mad honey sex: Therapeutic misadventures from an ancient biological weapon. *Ann of Emerg Med* 2009;54(6):824-9. (PMID:19683834).
- Gunduz A, Turedi S, Uzun H, Topbas M. Mad honey poisoning. *Am J Emerg Med* 2006;24(5):595-8. (PMID:16938599).
- Ajibola A, Chamunorwa JP, Erlwanger KH. Nutraceutical values of natural honey and its contribution to human health and wealth. *Nutr Metab* 2012;9:61. (PMID:22716101).
- Jansen SA, Kleerekooper I, Hofman ZL, et al. Grayanotoxin poisoning: 'mad honey disease' and beyond. *Cardiovasc Toxicol* 2012;12(3):208-15. (PMID:22528814).
- Maejima H, Kinashita E, Seyama I, Yamaoka K. Distinct site regulating grayanotoxin binding and unbinding to D4S6 of sodium channel as revealed by improved estimation of toxin sensitivity. *J Biological Chemistry* 2003;278(11):9464-71. (PMID:12524436).
- Gündüz A, Turedi S, Russel M, Ayaz FA: Clinical review of grayanotoxin/mad honey poisoning past and present. *Clin Toxicol* 2008;46(5):437-42. (PMID:18568799).



7. Khatri N, Man HY. Synaptic activity and bioenergy homeostasis: Implications in brain trauma and neurodegenerative diseases. *Front Neurol* 2013;4:199. (PMID:24376435).
8. Bostan M, Bostan H, Kaya AO, et al. Clinical events in mad honey poisoning: A single centre experience. *Bull Environ Contam Toxicol* 2010;84(1):19-22. (PMID:19937314).
9. Dilber E, Kalyoncu M, Yariş N, Ökten A. A case of mad honey poisoning presenting with convulsion: Intoxication instead of alternative therapy. *Turk J Med Sci* 2002;32:361-2.
10. Erođlu SE, Urgan O, Onur ÖE, Denizbaşı A, Akođlu H. Grayanotoxin (Mad Honey) ongoing consumption after poisoning. *Balkan Med J* 2013;30:293-5.
11. Alp A, Şappak S, Sezer SD, et al. A rare cause of syncope among geriatric patients: Mad honey intoxication. *Turkish Journal of Geriatrics* 2012;15(1):115-8. (in Turkish).
12. Easton JD, Saver JL, Albers GW, et al. Definition and evaluation of transient ischemic attack. *Stroke* 2009;40(6):2276-93. (PMID:19423857).