

## Resveratrol against lung injury in an ischemia/reperfusion model of abdominal aortic rupture

*Abdominal aort rüptürü iskemi/reperfüzyon modelinde akciğer hasarına karşı resveratrol*

Sedat Ozan Karakişi<sup>1</sup>, Doğuş Hemşinli<sup>1</sup>, Levent Tümkaya<sup>2</sup>, Şaban Ergene<sup>1</sup>, Tolga Mercantepe<sup>2</sup>, Adnan Yılmaz<sup>3</sup>

<sup>1</sup>Department of Cardiovascular Surgery, Recep Tayyip Erdoğan University, Faculty of Medicine, Faculty, Rize, Turkey

<sup>2</sup>Department of Histology and Embryology, Recep Tayyip Erdoğan University, Faculty of Medicine, Faculty, Rize, Turkey

<sup>3</sup>Department of Medical Biochemistry, Recep Tayyip Erdoğan University, Faculty of Medicine, Faculty, Rize, Turkey

### ABSTRACT

**Background:** The aim of this study was to examine the effects on the lungs of ischemia/reperfusion injury in a ruptured abdominal aortic aneurysm model in rats and to investigate the potential protective effects of resveratrol.

**Methods:** Thirty-two male Sprague-Dawley rats were randomly divided into four groups: control, ischemia/reperfusion, sham (ischemia/reperfusion + solvent/dimethyl sulfoxide), and ischemia/reperfusion + resveratrol. In the groups subjected to ischemia/reperfusion, following 60-min shock to the abdominal aorta, vascular clamps were attached from the levels of the infrarenal and iliac bifurcation. A total of 60-min ischemia was applied, followed by 120-min reperfusion. In the ischemia/reperfusion + resveratrol group, intraperitoneal 10 mg/kg resveratrol was administered 15 min before ischemia and immediately after reperfusion. Malondialdehyde, glutathione, and catalase levels were analyzed and histopathological examination of the lung tissues was performed.

**Results:** Malondialdehyde levels increased in the ischemia/reperfusion and ischemia/reperfusion + dimethyl sulfoxide groups, compared to the control group, while catalase levels decreased, and no significant difference was observed in the glutathione levels. Malondialdehyde levels decreased with the administration of resveratrol, while glutathione levels increased, and catalase levels remained unchanged. The increased inflammation in interstitial spaces, thickening in the alveolar septal walls, increased numbers of cleaved caspase-3 apoptotic pneumocytes, and increased histopathological lung damage scores observed in the ischemia/reperfusion and ischemia/reperfusion + dimethyl sulfoxide groups improved with the application of resveratrol.

**Conclusion:** These findings suggest that resveratrol may exhibit a protective effect in preventing acute lung injury developing due to ischemia/reperfusion in ruptured abdominal aortic aneurysm surgery by reducing oxidative damage.

**Keywords:** Abdominal aorta, antioxidant, glutathione peroxidase, lung, malondialdehyde, resveratrol.

### ÖZ

**Amaç:** Bu çalışmada sıçanlarda rüptüre abdominal aort anevrizması modelinde iskemi/reperfüzyon hasarının akciğerlerdeki etkileri incelendi ve resveratrolün olası koruyucu etkileri araştırıldı.

**Çalışma planı:** Otuz iki erkek Sprague-Dawley sıçanı rastgele dört gruba ayrıldı: kontrol, iskemi/reperfüzyon, sham (iskemi/reperfüzyon+solvent/dimetil sülfoksit) ve iskemi/reperfüzyon +resveratrol. İskemi/reperfüzyon uygulanan gruplarda abdominal aorta 60 dk. şokun ardından infrarenal ve iliyak bifurkasyon seviyelerinden vasküler klempler yerleştirildi. Toplamda 60 dk. iskemiye takiben 120 dk. reperfüzyon uygulandı. İskemi/reperfüzyon + resveratrol grubuna, iskemiden 15 dk. önce ve reperfüzyondan hemen önce intraperitoneal yoldan 10 mg/kg resveratrol uygulandı. Malondialdehit, glutatyon ve katalaz düzeyleri araştırıldı ve akciğer dokusunda histopatolojik değerlendirme yapıldı.

**Bulgular:** Kontrol grubuna kıyasla iskemi/reperfüzyon ve iskemi/reperfüzyon + dimetil sülfoksit gruplarında, malondialdehit düzeyleri arttı, katalaz düzeyleri azaldı ve glutatyon düzeylerinde anlamlı bir fark gözlenmedi. Resveratrol uygulanması ile malondialdehit düzeyleri azalırken, glutatyon düzeyleri arttı ve katalaz düzeyleri değişmedi. Ayrıca, iskemi/reperfüzyon ve iskemi/reperfüzyon + dimetil sülfoksit gruplarında gözlenen interstisyel alanlarda enflamasyon artışı, damarlarda hiyalin membran yapılarının birikimi, alveolar septal duvarında kalınlaşma ve cleaved caspase-3 pozitif apoptotik pnömositlerin sayısındaki ve akciğer histopatolojik tahribat skorundaki artış resveratrol uygulanması ile geriledi.

**Sonuç:** Bu bulgular, resveratrolün rüptüre abdominal aort anevrizması cerrahisinde iskemi/reperfüzyon nedeniyle gelişen akut akciğer hasarının önlenmesinde oksidatif tahribatı azaltarak koruyucu etkinliği olabileceğini göstermektedir.

**Anahtar sözcükler:** Abdominal aort, antioksidan, glutatyon peroksidaz, akciğer, malondialdehit, resveratrol.

Received: March 10, 2021 Accepted: July 05, 2021 Published online: July 26, 2021

**Correspondence:** Sedat Ozan Karakişi, MD. Recep Tayyip Erdoğan Üniversitesi Tıp Fakültesi Kalp ve Damar Cerrahisi Anabilim Dalı, 53020 Rize, Türkiye.

Tel: +90 505 - 645 27 88 e-mail: ozankar@hotmail.com

### Cite this article as:

Karakişi SO, Hemşinli D, Tümkaya L, Ergene Ş, Mercantepe T, Yılmaz A. Resveratrol against lung injury in an ischemia/reperfusion model of abdominal aortic rupture. Turk Gogus Kalp Dama 2021;29(3):330-338

©2021 All right reserved by the Turkish Society of Cardiovascular Surgery.

This is an open access article under the terms of the Creative Commons Attribution-NonCommercial License, which permits use, distribution and reproduction in any medium, provided the original work is properly cited and is not used for commercial purposes (<http://creativecommons.org/licenses/by-nc/4.0/>).

Lower torso ischemia/reperfusion (I/Rep) injury developing due to cross-clamping of the abdominal aorta during surgical repair and hemorrhagic shock triggers systemic inflammatory response syndrome (SIRS). The process commencing with reperfusion of the ischemic lower torso following removal of the cross-clamp plays a key role in the increased levels of proinflammatory cytokines in the circulation and increased microvascular permeability.<sup>[1]</sup> Pulmonary sequestration of activated neutrophils is followed by acute respiratory distress syndrome linked to acute pulmonary microvascular damage and high mortality rates.<sup>[1]</sup>

The severity of distant organ injury occurring due to I/Rep after ruptured abdominal aortic aneurysm (RAAA) surgery is affected by several factors, such as severity of hemodynamic impairment, duration of ischemia, and tissue susceptibility to ischemia.<sup>[2]</sup> Depletion of energy stores during ischemia results in membrane ion gradient impairment and cellular swelling. In reperfusion, reactive oxygen species (ROS) emerging from such sources as activated neutrophils cause lipid peroxidation in the phospholipid layer of the cell membrane.<sup>[2-5]</sup> Measurement of levels of malondialdehyde (MDA) that occurs as a result of this damage in tissues is used to prove oxidant-mediated injury. Glutathione peroxidase (GSH) and catalase (CAT) are important endogenous antioxidant enzymes that protect living cells against ROS damage. Measurement of levels of these antioxidant enzymes indicates the severity of the oxidative stress.<sup>[2,5]</sup>

Resveratrol (RES), obtained from renewable plants such as grape and peanut, is a bioactive molecule that exhibits physiological effects on several organs. It prevents oxidative stress caused by ROS and neutrophil activation through its rich phenolic content.<sup>[6]</sup> The aim of the present study was to determine the possible protective effects of RES against I/Rep-related lung damage using histological and biochemical parameters to classify the degree of oxidative injury.

## MATERIALS AND METHODS

### Animals

Thirty-two male Sprague Dawley rats (3 to 5-month-old) with a mean weight of 245±30 g were used in this study. The study protocol was approved by the Recep Tayyip Erdoğan University, Faculty of Medicine Animal Experiments Ethics Committee (No: 2018-14). All animals were cared for in our experimental animals' research center in compliance with Guide for the Care and Use of Laboratory Animals criteria.

### Experimental design

In this study, the RAAA model designed by Lindsay *et al.*<sup>[7]</sup> to investigate ischemia reperfusion injury in distant organs was used. The procedures during the determination of the experimental groups (control, I/Rep, I/Rep+solvent/dimethyl sulfoxide [DMSO], I/Rep+RES), anesthesia applications, carotid artery and jugular vein cannulations, vascular clamping in the infrarenal abdominal aorta (IAA) were performed as described previously.<sup>[7,8]</sup> In the I/Rep+RES group, 10 mg/kg RES was applied intraperitoneally 15 min before the clamps were placed in the IAA and immediately before the clamps were removed. To the I/Rep+DMSO group, 10 mg/kg DMSO was given intraperitoneally, and the same amount of saline was given to the I/Rep group (Table 1).<sup>[9]</sup>

### Biochemical analysis

#### Tissue homogenization

Tissue samples were washed in ice-cold phosphate buffered saline. All samples were homogenized 5 min at 30 Hz and were, then, centrifuged at +40°C at 3,000 g for 15 min. The MDA, GSH, and CAT assays were performed using the supernatant.<sup>[10]</sup>

#### Determination of MDA, GSH, and CAT

In supernatant samples from tissues, MDA levels (YL Biont Rat MDA kit, catalog no. YLA0029RA), GSH levels (YL Biont Rat GSH kit, catalog no. YLA0121RA), and CAT levels (YL Biont Rat CAT kit, catalog no. YLA0123RA) were determined in accordance with the instructions of a commercial rat-specific enzyme-linked immunosorbent assay (ELISA) kit.

#### Histopathological analysis

Lung tissue samples removed from the rats and trimmed in a volume of 1.5 cm<sup>3</sup> were fixed in 10% neutral formalin for 48 h (Sigma-Aldrich, Saint Louis, MO, USA). After the fixation step, in line with routine histological procedures, the specimens were dehydrated by being passed through increasing ethanol series (50%, 70%, 80%, 90%, and 100%; Merck KGaA, Darmstadt, Germany) with a tissue processor device (Shendon Citadel 2000, Thermo Fisher Scientific Inc., Altrincham, WA, UK). Next clearing was performed with xylol solution (Merck KGaA, Darmstadt, Germany) and the specimens were, then, embedded in soft paraffin (42-44°C, Merck KGaA, Darmstadt, Germany) for 2 h. Finally, after being kept overnight in hard paraffin (52 to 54°C, Merck KGaA, Darmstadt, Germany), the specimens were

embedded into the tissue cassettes (Isolab Laborgeräte GmbH, Eschau, Germany) using a tissue embedding device (Leica, EG1150, Leica Germany). Lung tissue sections, 4 to 5 µm in thickness, were prepared from the paraffin blocks using a rotary microtome (Leica RM2525, Leica Germany). These sections were stained with Harris's hematoxylin (Merck KGaA, Darmstadt, Germany) and eosin G (Merck KGaA, Darmstadt, Germany) using a tissue staining device (Leica RM2525, Leica, Germany). The sections were, then, examined under a light microscope (Olympus BX51, Olympus Corp., Tokyo, Japan) with an attached digital camera (Olympus DP71, Olympus Corp., Tokyo, Japan) and photographed.

### Immunohistochemical (IHC) analysis

Lung tissue sections, 1 to 3 µm in thickness, were prepared from the paraffin blocks using a rotary microtome (Leica RM2525, Leica Germany). These sections were placed into positively charged slides (Parola Biomedical, Istanbul, Turkey). They were, then, stained using anti-cleaved caspase-3 antibody primary antibody (Rabbit polyclonal, ab2302, Abcam, UK) and secondary antibody (Goat Anti-Rabbit IgG H&L (HRP), ab205718, Abcam, UK) kits, in line with the manufacturer's instructions, on a Leica Bond Max IHC staining device (Leica microsystem, Melbourne, Australia), a closed and fully automated system. Counterstaining was, then, performed with Harris's hematoxylin (Merck KGaA, Darmstadt, Germany).

### Semi-quantitative analysis

Semi-quantitative analysis was scored as shown in Table 2 by modifying the lung tissue histopathological damage score (LHDS).<sup>[11]</sup> Immunohistochemically immune-positive cells in sections were scored as shown in Table 3.<sup>[12]</sup> At semi-quantitative analysis, 25 randomly selected areas in sections were scored by two histopathologists using a ×20 magnifying lens. The histopathologists were blinded to the study groups.

### Statistical analysis

Statistical analysis was performed using the SPSS version 20.00 software (IBM Corp., Armonk, NY, USA). Descriptive data were expressed in mean ± standard deviation (SD). Differences between the groups were analyzed using one way analysis of variance (ANOVA) followed by the Tukey's honestly significant difference test. Non-parametric data obtained from histopathological analyses were expressed in median (interquartile range 25<sup>th</sup>-75<sup>th</sup> percentile). Intergroup differences were evaluated using the Kruskal-Wallis and Tamhane T2 tests.

**Table 1. Interventions applied to experimental groups**

Groups (n=8)	Lap	Shock (60 min)	Heparin (100 U/kg)	Treatment (15 min before the clamp)	Clamp (60 min)	Blood resuscitation	Treatment (before removing the clamp)	Reperfusion (120 min)	Blood and tissue samples
Control	+	-	-	-	-	-	-	-	+
I/Rep	+	+	+	10 mg/kg Saline	+	+	10 mg/kg Saline	+	+
I/Rep+solvent (DMSO)	+	+	+	10 mg/kg DMSO	+	+	10 mg/kg DMSO	+	+
I/Rep+RES	+	+	+	10 mg/kg RES	+	+	10 mg/kg RES	+	+

I/Rep: Ischemia/reperfusion; DMSO: Dimethyl sulfoxide; RES: Resveratrol; Lap: Laparotomy.

**Table 2. Lung histopathological damage score**

Findings	Score			
	0	1	2	3
Infiltration	None	≤5%	≤25%	≤50%
Hyaline membrane	None	≤5%	≤25%	≤50%
Alveolar debris accumulation	None	≤5%	≤25%	≤50%
Alveolar septum thickness (Treatment/Control Group)	<X2	2X-4X	>X4	

A *p* value of <0.05 was considered statistically significant.

## RESULTS

### Biochemical analysis results

An increase was observed in MDA levels in the I/Rep and I/Rep+DMSO groups compared to the control group (*p*=0.001 and *p*=0.046, respectively) (Table 4). In contrast, MDA levels were lower in the RES treatment group, compared to the I/Rep group (*p*=0.046) (Table 4). No significant difference was observed in terms of GSH levels in lung tissues between the I/Rep and I/Rep+DMSO groups and the control group. However, the GSH levels increased significantly in the RES treatment group compared to the I/Rep and I/Rep+DMSO groups (*p*=0.011

and *p*=0.001, respectively) (Table 4). Catalase levels in lung tissue decreased significantly in the I/Rep and I/Rep+DMSO groups, compared to the control group (*p*=0.003 and *p*=0.001, respectively) (Table 4). However, no significant difference was observed in catalase levels between the RES group and the I/Rep and I/Rep+DMSO groups (Table 4).

### Histopathological analysis results

Lung tissue parenchyma consisting of normal alveoli were present in tissues from the control group (Figure 1a, b; Table 5). However, hyaline membrane structures in vessels and inflammation in interstitial areas were present in the I/Rep and I/Rep+DMSO groups. In addition, thickening in the alveolar septal wall and debris accumulations in alveoli were observed (Figure 1c-f; Table 5). In contrast, alveolar septal wall thickening and alveolar debris deposition decreased in the RES group. A decrease was also observed in inflammation in interalveolar spaces and in hyaline membrane structures in the vascular wall (Figure 1g-h; Table 5).

### IHC analysis results

The numbers of cleaved caspase-3 positive apoptotic pneumocytes increased in the I/Rep and I/Rep+ DMSO groups compared to the control group (Figure 2a-c; Table 6). However, numbers of apoptotic pneumocytes

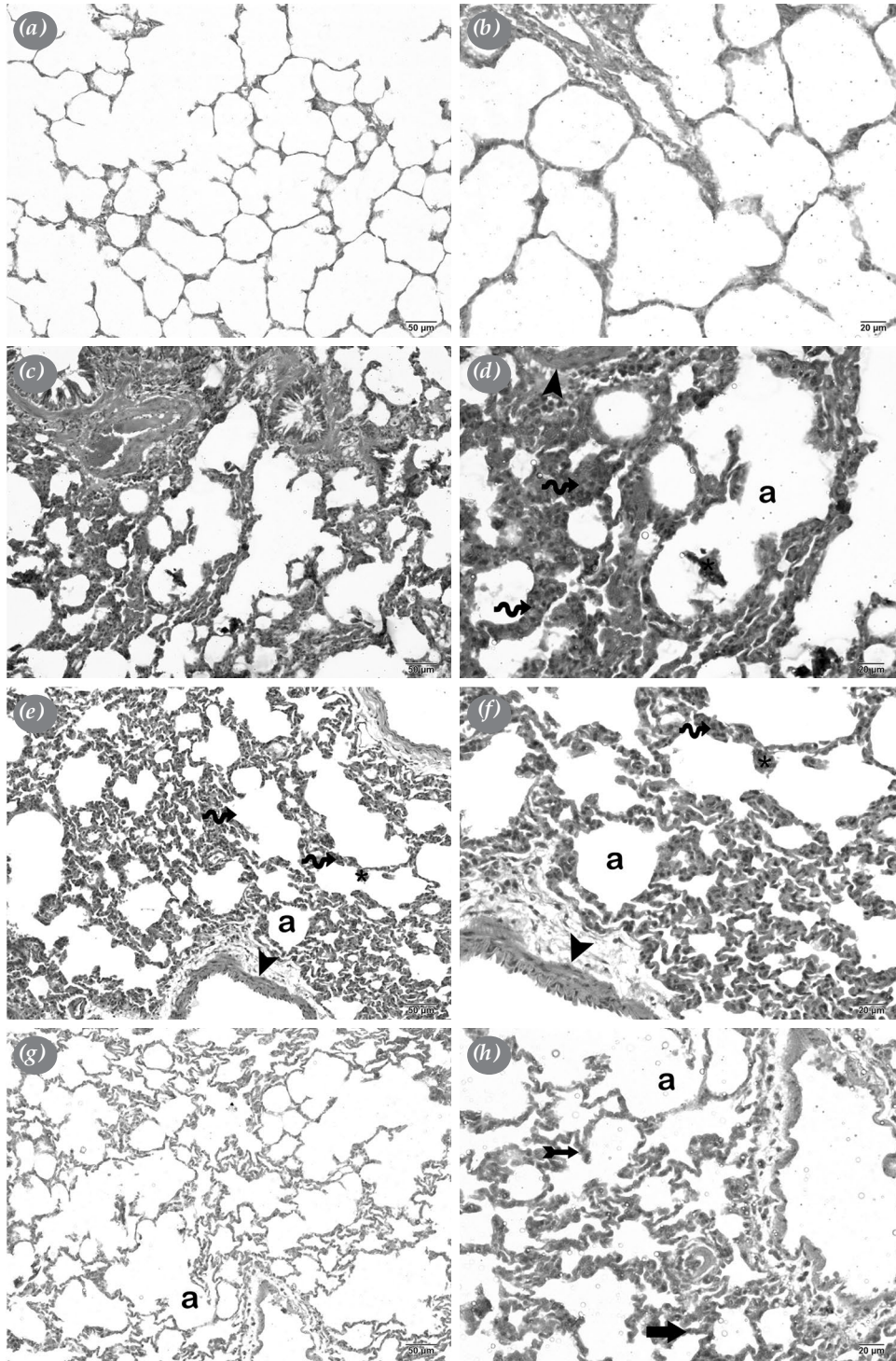
**Table 3. Grading of immune positivity scores**

Score	
0	None
1	Mild (less than 5%)
2	Moderate (6-25%)
3	Severe (26-50%)
4	Very severe (more than 50%)

**Table 4. Biochemical analysis results**

Groups (n=8)	MDA (nmol/g tissue)	GSH (µg/g tissue)	CAT (µg/g tissue)
	Mean±SD	Mean±SD	Mean±SD
Control	15.6±1.6	3.0±0.2	0.3±0.0
I/Rep+DMSO	22.6±3.8 <sup>a</sup>	2.9±0.1	0.2±0.0 <sup>f</sup>
I/Rep	19.6±2.0 <sup>b</sup>	2.9±1.0	0.2±0.0 <sup>e</sup>
I/Rep+RES	18.8±2.6 <sup>c</sup>	3.5±0.3 <sup>d,e</sup>	0.3±0.0

SD: Standard deviation; I/Rep: Ischemia/reperfusion; DMSO: Dimethyl sulfoxide; RES: Resveratrol; <sup>a</sup>*p*=0.001; Compared to the control group; <sup>b</sup>*p*=0.046; Compared to the control group; <sup>c</sup>*p*=0.046; Compared to the control group; <sup>d</sup>*p*=0.011; Compared to the control group; <sup>e</sup>*p*=0.001; Compared to the I/Rep group; <sup>f</sup>*p*=0.005; Compared to the control group; <sup>g</sup>*p*=0.003; Compared to the control group; One way-ANOVA/Bonferroni.

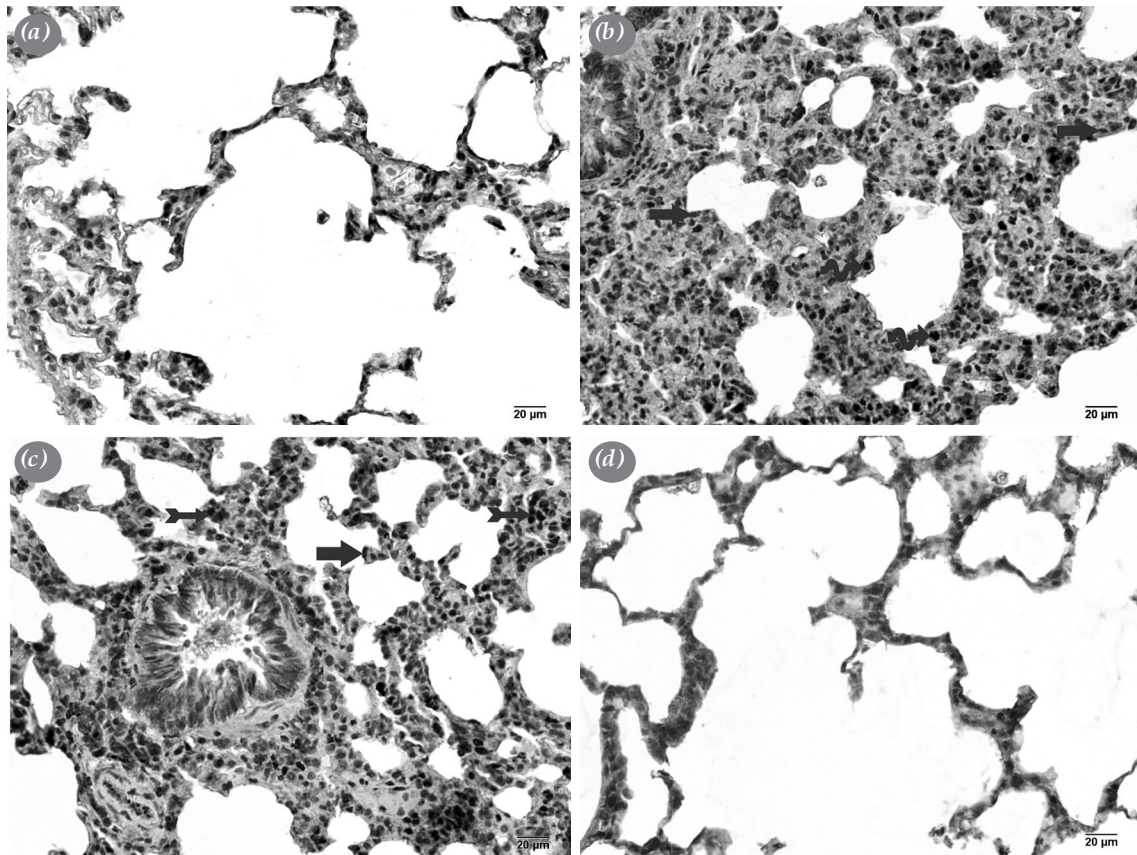


**Figure 1.** Representative light microscopic image of H-E-stained pulmonary tissue. (a) ( $\times 20$ )-(b) ( $\times 40$ ) Control Group: Alveoli consisting of typical type I pneumocytes (arrow) and type II pneumocytes (tailed arrow) are observed (LHDS: 0.5(0-1)). (c) ( $\times 20$ )-(d) ( $\times 40$ ) I/R Group: Thickening of the alveolar septal wall (arrow) and alveolar debris deposits (asterisk) are observed. Besides, hyaline membrane structures (arrow head) are observed (LHDS: 8(7-8)). (e) ( $\times 20$ )-(f) ( $\times 40$ ) I/Rep+DMSO Group: Thickening of the alveolar septal wall (spiral arrow), alveolar debris deposits (asterisk) and hyaline membrane structures (arrow head) are observed (LHDS: 8(8-8)). (g) ( $\times 20$ )-(h) ( $\times 40$ ) I/Rep+RES Group: Decreased thickening of the alveolar septal wall, typical I type pneumocytes (arrow) and type II pneumocytes (tailed arrow) are observed. However, it is noteworthy that alveolar debris deposits and hyaline membrane structures decrease. (LHDS: 3.5(2-5)).

**Table 5. LHDS analysis results**

Groups (n=8)	Infiltration		Hyaline membrane		Alveolar debris accumulation		Alveolar septum thickness (Treatment/Control Groups)		LHDS	
	Median	IQR 25 <sup>th</sup> -75 <sup>th</sup> percentile	Median	IQR 25 <sup>th</sup> -75 <sup>th</sup> percentile	Median	IQR 25 <sup>th</sup> -75 <sup>th</sup> percentile	Median	IQR 25 <sup>th</sup> -75 <sup>th</sup> percentile	Median	IQR 25 <sup>th</sup> -75 <sup>th</sup> percentile
Control	0.00	0-0	0.00	0-0	0.00	0-0	0.00	0-0	0.5	0-1
I/Rep	1.5	1-2 <sup>a</sup>	2	2-3 <sup>a</sup>	2	2-2 <sup>a</sup>	2	2-2 <sup>a</sup>	8.00	7-8 <sup>a</sup>
I/Rep+DMSO	2	2-2 <sup>b</sup>	2	2-3 <sup>a</sup>	2	2-2 <sup>a,d</sup>	2	2-2 <sup>d</sup>	8.00	8-8 <sup>a</sup>
I/Rep+RES	0	1-1 <sup>b,d</sup>	1	1-1 <sup>c</sup>	1	1-1 <sup>c</sup>	1	0-1 <sup>f</sup>	3.50	2-5 <sup>g</sup>

LHD: Lung tissue histopathological damage score; IQR: interquartile range; I/Rep: Ischemia/reperfusion; DMSO: Dimethyl sulfoxide; RES: Resveratrol; <sup>a</sup>p=0.000; Compared to the control group; <sup>b</sup>p=0.006; Compared to the control group; <sup>c</sup>p=0.002; Compared to the I/Rep group; <sup>d</sup>p=0.001; Compared to the control group; <sup>e</sup>p=0.028; Compared to the I/Rep group; <sup>f</sup>p=0.010; Compared to the I/Rep group; <sup>g</sup>p=0.003; Compared to the I/Rep group; Kruskal Wallis -Tamhane's T2 test.



**Figure 2.** Representative light microscopic image of Cleaved Caspase-3 primary antibody stained pulmonary tissue. (a) (×40) Control Group: Normal type I pneumocytes (arrow) and type II pneumocytes (tailed arrow) are observed (Cleaved Caspase-3 positivity score: 1(0-1)). (b) (×40) I/Rep Group: Apoptotic type I pneumocytes (arrow) and type II pneumocytes (tailed arrow) are observed (Cleaved Caspase-3 positivity score: 2(2-2)). (c) (×40) I/Rep+DMSO Group: An increase in caspase-3 positivity is observed in type I pneumocytes (arrow) and type II pneumocytes (blue tailed arrow) (Cleaved Caspase-3 positivity score: 3(2-3)). (d) (×40) I/Rep+RES Group: A decrease in caspase-3 positivity is observed in type I pneumocytes (arrow) and type II pneumocytes (tailed arrow) (Cleaved Caspase-3 positivity score: 1(1-2)).

**Table 6. Cleaved Caspase-3 positivity scores results**

Groups (n=8)	Cleaved caspase-3 positivity grade scores	
	Median	25-75% IQR
Control	1	0-1
I/Rep	2	2-2 <sup>a</sup>
I/Rep+DMSO	3	2-3 <sup>a</sup>
I/Rep+RES	1	1-2 <sup>b,c</sup>

IQR: Interquartile range; I/Rep: Ischemia/reperfusion; DMSO: Dimethyl sulfoxide; RES: Resveratrol; <sup>a</sup>p=0.000; Compared to the control group; <sup>b</sup>p=0.000; Compared to the I/Rep group; <sup>c</sup>p=0.000; Compared to the I/Rep group; Kruskal Wallis -Tamhane's T2 test.

were lower in the RES group than in the I/Rep group (Figure 2a-d; Table 6).

### Semi-quantitative analysis results

Alveolar-septal wall thickness, inflammation, and LHDS scores increased in the I/Rep group, compared to the control group (Table 5). In contrast, alveolar-septal wall thickness, inflammation, and LHDS scores decreased in the RES group, compared to the I/Rep group (Table 5).

## DISCUSSION

Systemic inflammatory response syndrome develops during RAAA surgery as a result of hypovolemic shock, massive blood transfusion, cross-clamping, and activation of inflammatory mediators. Both SIRS and multiorgan failure are the principal causes of high mortality observed during intensive care follow-up. The prevalence of multiorgan failure following non-ruptured aneurysm surgery is 3.8%, but 64% after RAAA.<sup>[13]</sup> Lung ischemia reperfusion injury (LIRI) that develops in association with inflammatory mediators and triggers a process leading to multiorgan failure continues to be an important problem in patients undergoing RAAA surgery. It can be defined as reversible tissue injury occurring in the ischemic period worsening and becoming irreversible during reperfusion, when the blood flow is restored.<sup>[14]</sup>

Previous studies have reported severe degeneration in alveolar structures, interstitial edema, inflammatory cell infiltration, and vascular congestion as a result of I/Rep induced by occlusion of the IAA.<sup>[15-17]</sup> Additionally, Kurt et al.<sup>[17]</sup> observed edema and hyaline cast structures in transition areas of the respiratory bronchioles, dilatation in the saccus alveolaris, edema in the subepithelial bronchial region, as well as irregularity in the lamina propria, perivascular edema,

and obstruction in small capillary vessels as a result of I/Rep at examination of pulmonary tissues. Yaman et al.<sup>[16]</sup> recorded swelling and vacuolization in the bronchial epithelium, increased pulmonary vascular permeability, and dilatation in the alveoli. They also observed that interstitial edema and inflammatory cell inflammation caused capillary obstruction, and thickening of and damage to the alveolar wall in some regions. Similarly, in the present study, we observed alveolar wall thickening, debris deposition in the alveoli, increased inflammation in the alveolar septal wall and interstitial areas, hyaline membrane in vascular structures, and increased LHDS scores in lung tissue as a result of I/Rep.

Caspase-3 is one of the essential enzymes involved in the development of cell apoptosis. The ROS production and cytokine activation occur during I/Rep. Additionally, the release of proteolytic enzymes as a result of neutrophil adhesion to the endothelium and the activation of caspase-3 enzyme systems results in apoptosis and lung cell death.<sup>[16-18]</sup> Kurt et al.<sup>[17]</sup> determined that I/Rep induced by occlusion of the IAA exacerbated the activity of caspase-3 and increased the incidence of apoptosis in pulmonary cells. Wang et al.<sup>[18]</sup> also reported significant increases in caspase-3 enzyme content, apoptotic cells, and cell death in lung tissue with I/Rep. In the present study, we also concluded that I/Rep was associated with an increase in caspase-3-positive apoptotic pneumocyte numbers.

The ROS are toxic molecules that play a critical role in the development of I/Rep-related lung damage. Cell membrane injury and intracellular oxidative phosphorylation disorder caused by ROS during I/Rep lead to cell death, inflammation, and leukocyte chemotaxis.<sup>[19]</sup> The ROS lead to increased cell permeability and lysis by causing lipid peroxidation in the cell membrane.<sup>[16]</sup> As one of the end products of I/Rep injury, MDA emerges with the breakdown of polyunsaturated fatty acids. It provides reliable information about the every of the peroxidation reaction and tissue damage, and is used as a marker in determining oxidative damage.<sup>[4]</sup> The I/Rep has been reported to cause a significant increase in MDA levels in lung tissues in studies involving clamping of the IAA and in studies involving pulmonary hilus clamping.<sup>[4,14,16,17,20]</sup> Similarly, in the present study, and consistent with previous research, we observed that I/Rep increased the lung tissue MDA levels.

Antioxidant enzymes produced against oxidative stress can inhibit oxidation even at low concentrations. The GSH and CAT are important antioxidant enzymes

that prevent cellular structures from undergoing oxidative damage. Determination of GSH and CAT levels is used to gain insight into the severity of oxidative stress exposed.<sup>[15,16]</sup> Yaman *et al.*<sup>[16]</sup> reported depletion of endogenous GSH due to I/Rep and low GSH levels in lung tissue in I/Rep group. Kumbasar *et al.*<sup>[4]</sup> reported significant decreases in both GSH and CAT levels in lung tissue after I/Rep. On the other hand, Cevirme *et al.*<sup>[15]</sup> did not observe that I/Rep damage caused by IAA occlusion caused a decrease in GSH levels in the lung tissue. Another study reported a decrease in CAT levels in lung tissue following I/Rep.<sup>[14]</sup> However, in the present study, we found no significant decrease in GSH levels in lung tissue, while CAT levels decreased significantly in groups subjected to I/Rep.

The RES (trans-3,4,5-trihidroksistilben) is a natural polyphenolic compound with antioxidant, anti-inflammatory, and anti-fibrotic properties.<sup>[19,21]</sup> The antioxidant effects of RES have been investigated in various I/Rep models and tissues. However, to the best of our knowledge, there are no previous studies investigating the effects of RES on lung tissue in the I/Rep model induced by occlusion of the IAA. Yeh *et al.*<sup>[20]</sup> clamped the pulmonary hilum and reported that RES reduced MDA levels and alveolar neutrophils in ischemic lung tissue, while preserving mitochondrial hemostasis. Huang *et al.*<sup>[21]</sup> also reported that RES showed preservative effects against oxidative stress in an intestinal ischemia model by producing a decrease in MDA levels and an increase in GSH in ischemic bowel tissue, while reducing expression of the inflammatory markers, cyclooxygenase 2 (COX-2) and nuclear factor-kappa b (NF- $\kappa$ B). In addition, the authors showed that RES reduced LIRI and improved respiratory functions by stabilizing mast cells in the lung and inhibiting NADPH oxidase. Xu *et al.*<sup>[19]</sup> reported that RES preserved the alveolar structure in pulmonary tissue exposed to ischemia in lung transplantation models, and reduced tissue edema, necrosis, and inflammation. Another study showed that RES increased GSH and CAT levels in ischemic spinal cord tissue.<sup>[22]</sup> In the present study, MDA levels decreased, GSH levels increased, and CAT levels remained unchanged with RES treatment in lung tissue exposed to I/Rep. Additionally, we observed inflammation in interalveolar areas, thickening of the alveolar septal wall, debris deposition in alveoli, hyaline membrane deposition in the vascular walls and decreased numbers of apoptotic cells, and a reduction in LDHS scores with RES treatment.

Nonetheless, this study has some limitations. This study, in which we examined the effects of the RES active ingredient on I/Rep damage, is a pilot study. Studies evaluating I/Rep damage in the lungs with other biomarkers such as cytokines, chemokines, and transcription factors would increase the value of our results. In addition, it would be beneficial to support the apoptosis finding with studies addressing Terminal deoxynucleotidyl transferase dUTP nick end labeling (TUNEL), intracellular, and mitochondrial calcium levels. Our study is the first experimental animal model study that addresses the effects of the RES active ingredient on I/Rep damage in the lungs. Therefore, our results should be supported by pharmacologically based studies focused on dose and duration of treatment. On the other hand, in the working model, a group given DMSO alone was formed to eliminate the possibility of the solvent affecting the results.

In conclusion, our study findings show that resveratrol exhibits protective effects against ischemia/reperfusion injury induced in the lungs through clamping of the infrarenal abdominal aorta. These findings suggest that resveratrol may have a future role among therapeutic methods developed to increase quality of life following ruptured abdominal aortic aneurysm surgery and to prevent lung ischemia reperfusion injury.

#### Declaration of conflicting interests

The authors declared no conflicts of interest with respect to the authorship and/or publication of this article.

#### Funding

This work was supported by the Recep Tayyip Erdogan University Scientific Research Support Fund (Grant number: TSA-2018-884).

#### REFERENCES

1. Harkin DW, Rubin BB, Romaschin A, Lindsay TF. Selective inducible Nitric Oxide Synthase (iNOS) inhibition attenuates remote acute lung injury in a model of ruptured abdominal aortic aneurysm. *J Surg Res* 2004;120:230-41.
2. Lindsay TF, Luo XP, Lehotay DC, Rubin BB, Anderson M, Walker PM, *et al.* Ruptured abdominal aortic aneurysm, a "two-hit" ischemia/reperfusion injury: Evidence from an analysis of oxidative products. *J Vasc Surg* 1999;30:219-28.
3. Lieberg J, Pruks LL, Kals M, Paapstel K, Aavik A, Kals J. Mortality after elective and ruptured abdominal aortic aneurysm surgical repair: 12-year single-center experience of Estonia. *Scand J Surg* 2018;107:152-7.
4. Kumbasar U, Demirci H, Emmez G, Yıldırım Z, Gönül II, Emmez H, *et al.* Protection from spinal cord ischemia-reperfusion damage with alpha-lipoic acid preconditioning in an animal model. *Turk Gogus Kalp Dama* 2018;26:138-145.



5. Al-Salam S, Hashmi S. Myocardial ischemia reperfusion injury: Apoptotic, inflammatory and oxidative stress role of galectin-3. *Cell Physiol Biochem* 2018;50:1123-39.
6. Baltaci AK, Gokbudak H, Baltaci SB, Mogulkoc R, Avunduk MC. The effects of resveratrol administration on lipid oxidation in experimental renal ischemia-reperfusion injury in rats. *Biotech Histochem* 2019;94:592-9.
7. Lindsay TF, Walker PM, Romaschin A. Acute pulmonary injury in a model of ruptured abdominal aortic aneurysm. *J Vasc Surg* 1995;22:1-8.
8. Hemşinli D, Ergene S, Karakişi SO, Mercantepe T, Tumkaya L, Yılmaz A, et al. Tea grape reduces abdominal aortic occlusion-induced lung injury. *Braz J Cardiovasc Surg* 2020;35:512-20.
9. Hemsinli D, Tumkaya L, Ergene S, Karakisi SO, Mercantepe T, Çınar S, et al. Resveratrol prevents acute renal injury in a model of ruptured abdominal aortic aneurysm. *Hum Exp Toxicol* 2021;40:555-65.
10. Tumkaya L, Yılmaz A, Akyildiz K, Mercantepe T, Yazici ZA, Yılmaz H. Prenatal effects of a 1,800-MHz electromagnetic field on rat livers. *Cells Tissues Organs* 2019;207:187-96.
11. Matute-Bello G, Downey G, Moore BB, Groshong SD, Matthay MA, Slutsky AS, et al. An official American Thoracic Society workshop report: Features and measurements of experimental acute lung injury in animals. *Am J Respir Cell Mol Biol* 2011;44:725-38.
12. Kostakoglu U, Topcu A, Atak M, Tumkaya L, Mercantepe T, Uydu HA. The protective effects of angiotensin-converting enzyme inhibitor against cecal ligation and puncture-induced sepsis via oxidative stress and inflammation. *Life Sci* 2020;241:117051.
13. Pulathan Z, Altun G, Hemşinli D, Menteşe A, Yuluğ E, Civelek A. Role of ethyl pyruvate in systemic inflammatory response and lung injury in an experimental model of ruptured abdominal aortic aneurysm. *Biomed Res Int* 2014;2014:857109.
14. Liang S, Wang Y, Liu Y. Dexmedetomidine alleviates lung ischemia-reperfusion injury in rats by activating PI3K/Akt pathway. *Eur Rev Med Pharmacol Sci* 2019;23:370-7.
15. Çevirme D, Adademir T, Kafalı Başaran E, Şavluk ÖF, Elibol A, Erkanlı Şentürk G, et al. Comparison between iloprost and alprostadil for protection against ischemia/reperfusion injury in a rat model. *Turk J Med Sci* 2018;48:661-9.
16. Yaman OM, Guner I, Guntas G, Sonmez OF, Tanriverdi G, Cakiris A, et al. Protective effect of thymosin  $\beta$ 4 against abdominal aortic ischemia-reperfusion-induced acute lung injury in rats. *Medicina (Kaunas)* 2019;55:187.
17. Kurt A, Kalkan Y, Turut H, Cure MC, Tumkaya L, Cure E. Topiramate reduces aortic cross-clamping-induced lung injury in male rats. *Acta Medica (Hradec Kralove)* 2018;61:144-9.
18. Wang F, Wang F, Li F, Wang D, Li H, He X, et al. Methane attenuates lung ischemia-reperfusion injury via regulating PI3K-AKT-NF $\kappa$ B signaling pathway. *J Recept Signal Transduct Res* 2020;40:209-17.
19. Xu HC, Lv W, Wang LM, Ye P, Hu J. Early protection by resveratrol in rat lung transplantation. *Med Sci Monit* 2019;25:760-70.
20. Yeh DY, Fu YH, Yang YC, Wang JJ. Resveratrol alleviates lung ischemia and reperfusion-induced pulmonary capillary injury through modulating pulmonary mitochondrial metabolism. *Transplant Proc* 2014;46:1131-4.
21. Huang X, Zhao W, Hu D, Han X, Wang H, Yang J, et al. Resveratrol efficiently improves pulmonary function via stabilizing mast cells in a rat intestinal injury model. *Life Sci* 2017;185:30-7.
22. Fu S, Lv R, Wang L, Hou H, Liu H, Shao S. Resveratrol, an antioxidant, protects spinal cord injury in rats by suppressing MAPK pathway. *Saudi J Biol Sci* 2018;25:259-66.