

ORIGINAL ARTICLE

Open Access



Evaluation of periostin, fibronectin and tenascin-C in patients chronic otitis media with cholesteatoma

Mehmet Birinci^{1*}, Suat Terzi², Emine Demir², Metin Çeliker², Oğuzhan Okçu³, Medeni Arpa⁴, Özlem Çelebi², Zerrin Özergin² and Engin Dursun²

Abstract

Background: Although many studies have investigated the mechanisms of cholesteatoma formation, its pathogenesis remains unclear. The aim of this study was to evaluate the levels of periostin, fibronectin and tenascin-C, which are involved in many mechanisms, such as cell adhesion, cell differentiation, inflammation, fibrosis, angiogenesis and cell proliferation, in patients with chronic otitis media (COM). A total of 80 participants, 65 COM patients undergoing surgery and 15 healthcare personnel volunteers serving as controls, were included in this study. The participants were divided into four groups: cholesteatoma, granulation, avivation and control group. The serum periostin, fibronectin and tenascin-C levels of all participants were determined biochemically. Histopathological evaluation of tissue samples and 20 skin samples used as controls was performed by immunohistochemistry.

Results: Of the 65 patients, 22 presented with cholesteatoma, 15 with granulation tissue and 28 with the edge of the tympanic membrane perforation freshening tissue. There were no significant differences in serum periostin, fibronectin and tenascin-C levels between the groups. In the immunohistochemical evaluation, fibronectin and periostin staining was significantly more intense in the cholesteatoma group than in the other groups ($p = 0.001$). Epithelial tenascin-C staining was significantly more intense in the avivation group than in the other groups ($p = 0.041$).

Conclusion: The levels of periostin and fibronectin were higher in cholesteatoma tissue than in other forms of chronic otitis and skin tissue. This suggests that they may be involved in the mechanism of cholesteatoma formation. These proteins could be used as biomarkers in the diagnosis and treatment of cholesteatoma.

Keywords: Chronic otitis media, Cholesteatoma, Periostin, Fibronectin, Tenascin-C

Background

Chronic otitis media (COM) and chronic otitis media with cholesteatomas are still important health problems in underdeveloped and developing countries. Four theories of cholesteatoma formation have been proposed: invasion, squamous metaplasia, basal cell hyperplasia and retraction pocket theory [1]. Despite these theories, its formation mechanism has still not been clarified.

Periostin, fibronectin and tenascin-C are extracellular proteins that could be involved in cholesteatoma formation and chronic otitis media. Periostin, also called osteoblast-specific factor 2, is a matricellular protein first identified in mouse osteoblast cells [2]. Periostin is involved in fibrogenesis and cell adhesion, differentiation and death [3, 4].

Fibronectin is a large dimer glycoprotein found in all tissues and is necessary in various cell-matrix interactions, it is involved in events such as inflammation, fibrosis, wound healing, embryogenesis, haemostasis and angiogenesis [5, 6].

*Correspondence: birincimehmet_61@hotmail.com

¹ Department of Otorhinolaryngology, Of State Hospital, Trabzon, Turkey
Full list of author information is available at the end of the article

Tenascin-C is a hexameric glycoprotein expressed in the extracellular matrix of various tissues. Tenascin-C regulates cell migration, adhesion and growth. It physiologically regulates mesenchymal transitions and cell migration in embryonic tissues. It is also known to participate in various stages of wound healing, fibrosis and tumorigenesis [7, 8].

Although many studies have investigated the mechanisms of cholesteatoma formation, its pathogenesis remains unclear. It has been shown in various studies that periostin, fibronectin and tenascin-C proteins have many functions such as cell adhesion, fibrosis, cell proliferation, inflammation, angiogenesis and cell differentiation [2–8]. Therefore, we aimed to determine the levels of periostin, fibronectin and tenascin-C in COM and cholesteatoma patients in order to investigate their role in the pathogenesis mechanisms and determine whether they can be used as biomarkers in the diagnosis and treatment of cholesteatoma.

Methods

This study included 65 patients undergoing surgery for COM in our clinic. Patients with chronic drug use, diffuse tympanosclerosis, previous operation on the same ear and congenital cholesteatoma and eosinophilic otitis media were excluded. All included patients were provided with detailed information about the aims and methods of the study and signed informed consent forms. The study protocol was in line with the principles of the Declaration of Helsinki and ethics approval was obtained from the Clinical Research Ethics Committee (No. 2018/6).

The study included biochemical and histopathological examinations. For the biochemical examinations, blood samples collected from the patients preoperatively were centrifuged after having been studied. The obtained blood serum was stored at - 20 °C until further analysis. Serum samples from blood collected from 15 hospital staff volunteers used as controls were similarly stored. Serum periostin, fibronectin and tenascin-C levels were measured with an enzyme-linked immunosorbent assay (ELISA).

For the histopathological examination, 85 tissue samples taken from the 65 patients were divided into four groups: cholesteatoma tissue, granulation tissue, the edge

of tympanic membrane (TM) perforation freshening tissue and skin tissue samples collected from 20 patients for control purposes. The levels of fibronectin polyclonal antibody (PAA037Hu01), periostin polyclonal antibody (PAH339Hu01) and tenascin-C polyclonal antibody (PAB975Hu01) were determined using an automatic immunohistochemistry device (SN: 714592, Ref: 750-700; Ventana Medical Systems, AZ, USA). In the staining scoring, epithelial and stromal staining rates were evaluated separately, and a semi-quantitative scoring system ranging from 0 to 3 for epithelia and from 0 to 4 for stroma was used. In the epithelial staining scoring [9], 0 represented no staining, 1 focal staining (+), 2 moderate staining (++) and 3 strong staining (+++). In the stromal staining scoring [10], 0 represented no staining, 1 focal staining (+), 2 diffuse staining in 1/2 area (++) and 3 diffuse staining in more than 1/2 area (+++) and 4 diffuse staining (++++).

Statistical analyses were performed using IBM SPSS Statistics 23.0 for Windows. Besides descriptive statistical methods (frequencies), the chi-square test was used to compare qualitative data, and one-way analysis of variance was used to compare quantitative data. The results were evaluated in the 95% confidence interval, and the significance level was $p < 0.05$. For chi-square p values of less than 0.05, the Bonferroni correction was used and separate chi-square analyses were performed for each category.

Results

The mean age of the 65 patients with COM (35 females and 30 males) was 39.84 years (range: 18–65 years). The average age of the 15 healthy controls (8 males and 7 females) was 36.87 ± 13.38 years. Twenty-two patients presented with cholesteatoma, 15 with granulation tissue and 28 with the edge of the tympanic membrane perforation freshening tissue. Twenty-two patients underwent canal wall down tympanoplasty, 16 underwent canal wall up tympanoplasty, and 27 underwent endoscopic tympanoplasty.

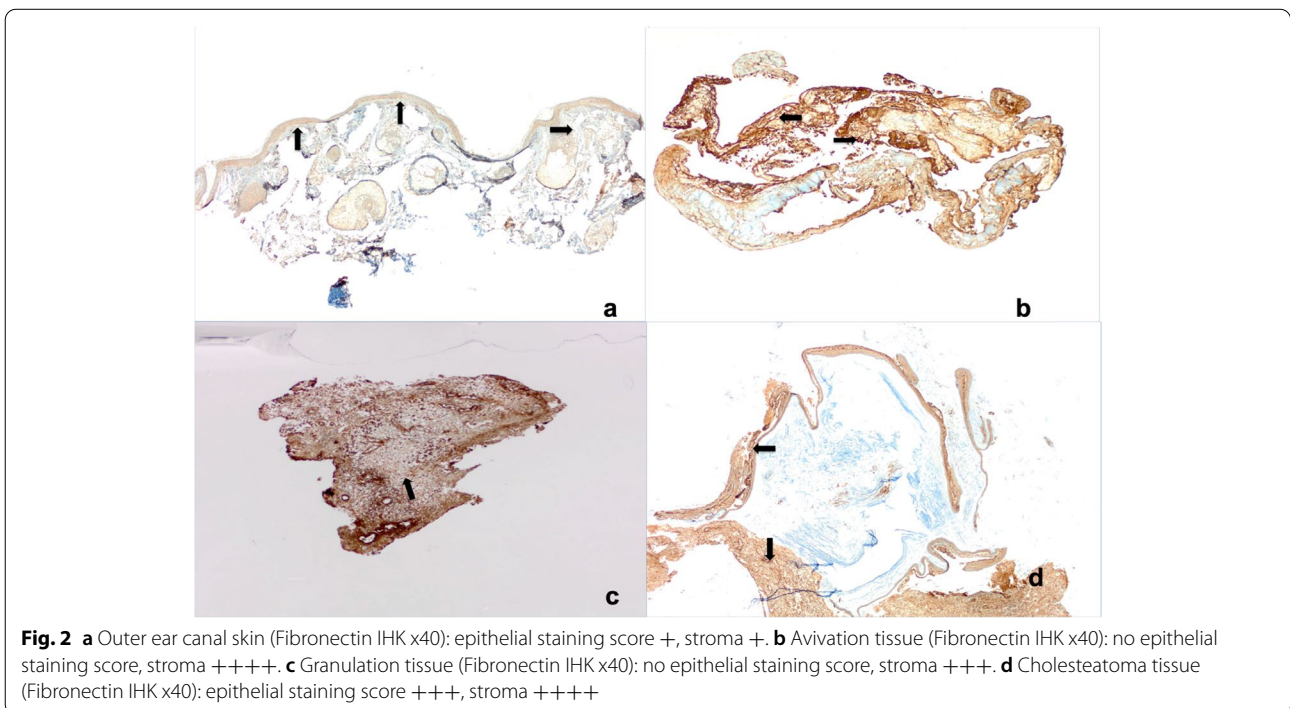
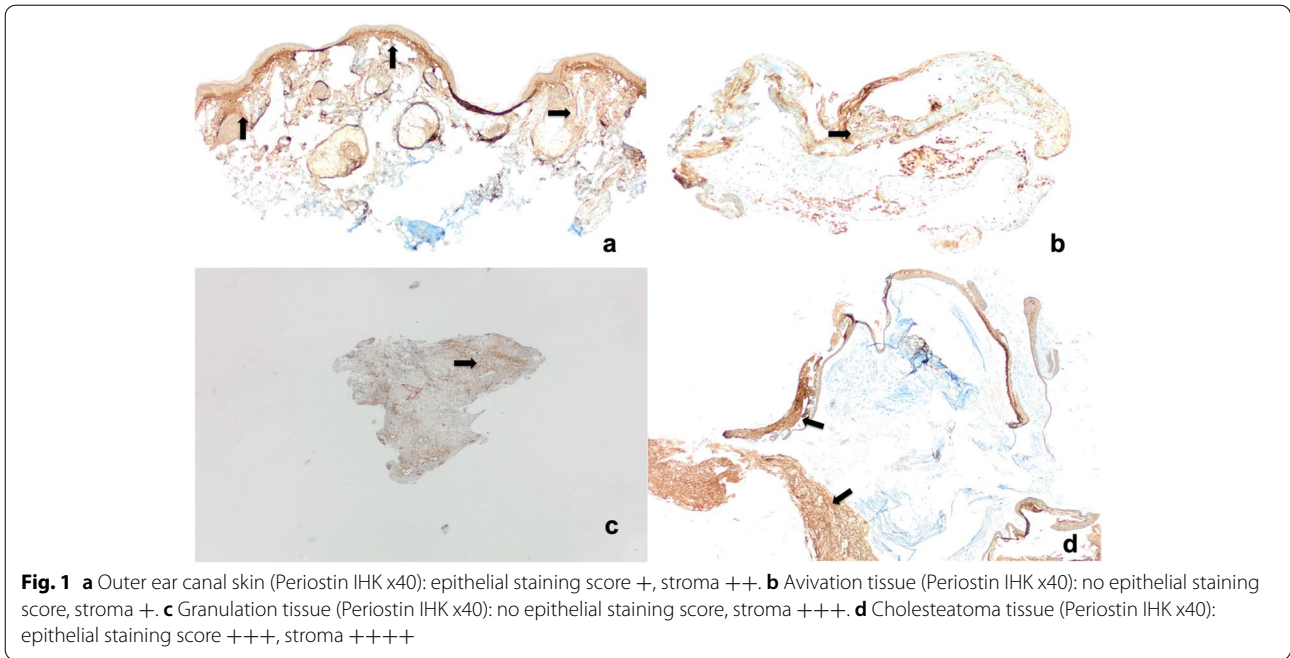
No significant differences were found between the groups in terms of serum periostin, fibronectin and tenascin-C levels ($p = 0.749$, $p=0.342$ and $p=0.093$, respectively; Table 1).

Table 1 Serum periostin, fibronectin and tenascin-C levels of the groups

	Cholesteatoma group (n = 22)	Granulation group (n = 15)	Aviation group (n = 25)	Control group (n = 15)	p
Periostin	546.29 ± 295.01	496.62 ± 212.3	559.75 ± 271.7	612.46 ± 373.4	0.749
Fibronectin	180.79 ± 47.91	207.53 ± 66.55	200.67 ± 77.22	171.65 ± 63.06	0.342
Tenascin-C	16.27 ± 5.5	17.72 ± 6.57	14.49 ± 3.1	13.64 ± 5.23	0.093

The staining characteristics of 63 epithelial and 67 stromal samples with staining properties were evaluated. In terms of epithelial periostin staining, cholesteatoma samples were significantly more strongly stained than the other groups ($p = 0.001$). Likewise, in terms of stromal periostin staining, more intense staining

was observed in the cholesteatoma group than in the other groups (Fig. 1). In terms of fibronectin staining, both epithelia and stroma were significantly more strongly stained in the cholesteatoma group than in the other groups ($p = 0.001$; Fig. 2). In terms of tenascin-C, stromal staining was significantly less intense in the



skin sample group than in the other groups ($p = 0.013$; Fig. 3).

Discussion

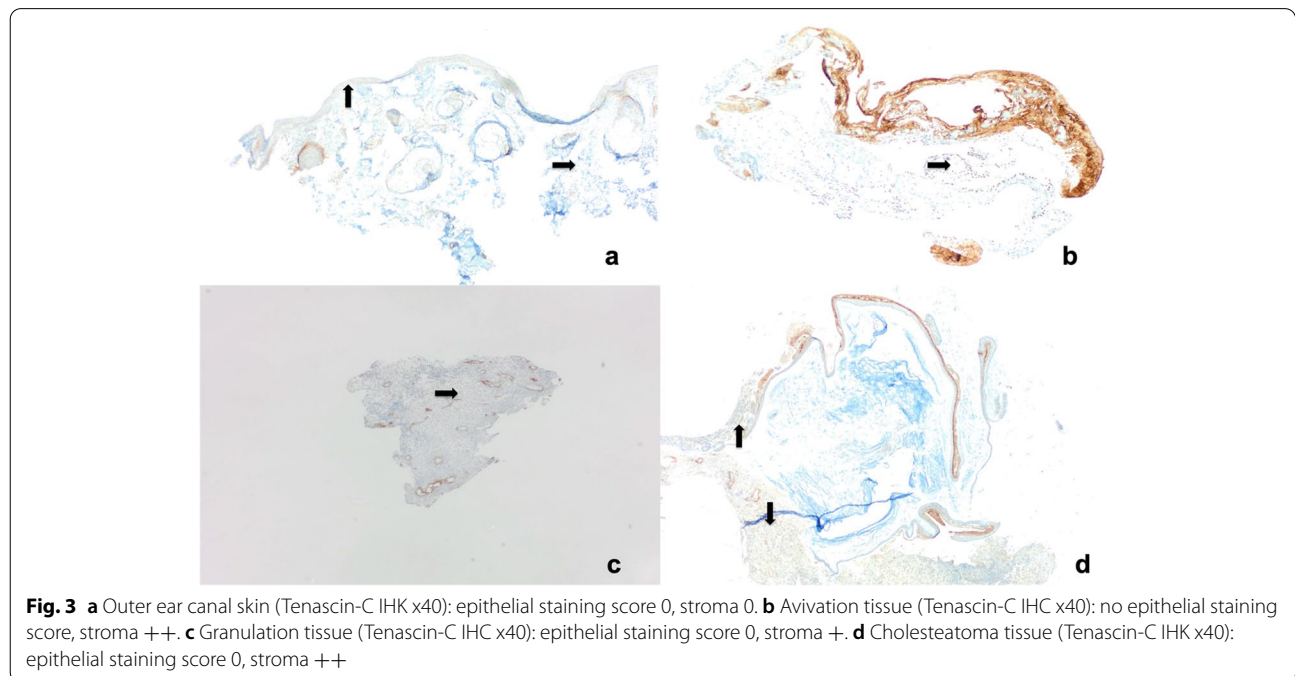
It is known that histological changes occur in the tympanic membrane (TM) and the middle ear mucosa in COM. Normally, the tympanic membrane has no cellular structure other than mast and Langerhans cells. A previous study found that mast and Langerhans cells in the TM increased in COM [11]. Another study reported an increase in connective tissue and cell proliferation in the TM in a cholesteatoma model [12]. In our study, a few fibroblasts, inflammatory cells and vascular structures forming the stromal connective tissue were detected in the avivation group.

Although many studies have investigated the mechanisms of cholesteatoma formation, its pathogenesis remains unclear [1]. Many molecules and proteins have been investigated [13–16]. Studies on cholesteatoma tissue have shown that epidermal growth factor receptor (EGFR) disorder plays a role in the development of cholesteatoma. Bujia et al. reported EGFR upregulation in cholesteatoma tissue [13]. Heparin-binding epidermal growth factor-like growth factor (HB-EGF) is a protein that binds to the EGFR and participates in cell proliferation. It has been observed that HB-EGF is more expressed in cholesteatoma tissue than in normal skin, and its expression level correlates with bone degradation [14]. Although high keratinocyte growth factor (KGF) levels have been found in cholesteatoma tissue, its receptor

levels have been shown to be the same as those in normal skin tissue [15]. A study suggested that heat shock proteins 60 and 70 may play a role in the aetiopathogenesis of cholesteatoma and that they produce their effects through IL-1 and TNF- α [16]. These findings are promising for cholesteatoma treatment options. In a case report, Chao et al. [17] reported that the patient completely recovered from cholesteatoma after long-term anti-TNF- α antibody (infliximab) treatment. Our study found high periostin and fibronectin levels in cholesteatoma tissue. This suggests that periostin and fibronectin may play a role in the mechanism of cholesteatoma formation and that agents targeting periostin and fibronectin may be used in the treatment of cholesteatoma in the future.

In a study comparing cholesteatoma and normal skin, type 4 collagen continuity was observed in the basement membrane but not in cholesteatoma tissue. Moreover, increased immune reactivity of fibronectin was found in the basement membrane and subepithelial connective tissue [18]. Another study found that tenascin and fibronectin expressed along the epidermal–stromal junction were in the form of a band and extended to the deep stroma. Furthermore, tenascin and fibronectin expression was suggested to disturb cell-matrix interactions during the proliferation phase of cholesteatoma tissue [19].

Periostin expression has been shown to play a role in the pathogenesis of otolaryngologic diseases such as allergic rhinitis, chronic rhinosinusitis with nasal polyps, aspirin-induced asthma, eosinophilic otitis media



and IgG4-related diseases [20–25]. Our results suggest that COM can be added to these diseases. A study on ankylosing spondylitis patients found an inverse relationship between disease activity and blood periostin levels. Serum periostin levels were considerably low in patients with high disease activity. The authors also suggested that serum periostin levels in patients with nasal polyps can be used to predict the presence, extent and outcome of the disease [24]. In our study, we detected high periostin levels in cholesteatoma tissue samples but found no significant difference between serum periostin, fibronectin and tenascin-C levels. We speculate that this may be because cholesteatoma is a local disease.

A study on cholesteatoma reported that fibronectin was significantly upregulated in cholesteatoma and granulation tissue. It is known that fibronectin mediates in vitro adhesion of fibroblasts and endothelial cells and promotes in vitro keratinocyte migration and proliferation. Therefore, fibronectin was assumed to play an important role in the pathogenesis of cholesteatoma [18]. In our study, stromal staining of fibronectin was markedly more intense in cholesteatoma tissue than in other tissues. This suggests that fibronectin may play a role in the development of cholesteatoma.

Tenascin-C promotes cell migration and adhesion [26]. It also plays a role in regulating cell functions, such as tenascin-C epithelial proliferation and migration [27]. It has been reported that tissue tenascin-C levels can be used as predictors of disease severity in fibrosis, myocarditis and inflammatory bowel disease [28]. In our study, stromal tenascin-C staining was significantly less intense in the skin samples. However, no correlation was found between tenascin-C and cholesteatoma.

Certain limitations of this study should be mentioned. Firstly, the small sample size of our groups. Secondly, we could not include normal middle ear mucosa in the study due to ethical barriers. Finally, samples cannot be evaluated by a quantitative reverse transcription-polymerase chain reaction and gene expression because we did not have the appropriate equipment and equipment to perform gene analysis. As a continuation of this work, we will continue to work on this issue as well.

Conclusions

In our study, periostin and fibronectin levels were higher in cholesteatoma tissue than in other forms of chronic otitis and skin samples. This suggests that periostin and fibronectin may play an important role in the development of cholesteatoma. However, larger studies are needed to ascertain the role of these proteins in the aetiopathogenesis of cholesteatoma and their value as biomarkers for its diagnosis and treatment.

Acknowledgements

Not applicable.

Authors' contributions

MB, ST, MC. Data curation: ST, ED. Formal analysis: MB, ST, OCE. Funding acquisition: OO, MA. Methodology: MB, ST, MC. Project administration: ED, OCE, ZOC, EDu. Writing—original draft: MB, MC, ZOC, EDu. Writing—review & editing: all authors. The authors read and approved the final manuscript.

Funding

This work was supported by the Scientific Research Projects Coordinator of Recep Tayyip Erdoğan University (Project code: TTU-2018-831).

Availability of data and materials

The datasets used and/or analysed during the current study are available from the corresponding author on reasonable request.

Declarations

Ethics approval and consent to participate

The study protocol was in line with the principles of the Declaration of Helsinki and ethics approval was obtained from the Clinical Research Ethics Committee (protocol number: No: 08/04/2018- 6). All included patients were provided with detailed information about the aims and methods of the study and signed informed consent forms.

Consent for publication

All included patients were provided with detailed information about the aims and methods of the study and signed informed consent forms.

Competing interests

The authors declare that they have no competing interests.

Author details

¹Department of Otorhinolaryngology, Of State Hospital, Trabzon, Turkey. ²Department of Otorhinolaryngology, Faculty of Medicine, Recep Tayyip Erdoğan University, Rize, Turkey. ³Department of Pathology, Faculty of Medicine, Recep Tayyip Erdoğan University, Rize, Turkey. ⁴Department of Biochemistry, Faculty of Medicine, Recep Tayyip Erdoğan University, Rize, Turkey.

Received: 27 December 2021 Accepted: 28 January 2022

Published online: 02 March 2022

References

1. İncesulu A (2005) Chronic suppurative otitis media. *Turkiye klinikleri J Surg Med Sci* 1:66–70
2. Takeshita S, Kikuno R, Tezuka K, Amann E (1993) Osteoblast-specific factor 2: cloning of a putative bone adhesion protein with homology with the insect protein fasciclin I. *Biochem J* 294:271–278
3. Horiuchi K, Amizuka N, Takeshita S, Takamatsu H, Katsuura M, Ozawa H et al (1999) Identification and characterization of a novel protein, periostin, with restricted expression to periosteum and periodontal ligament and increased expression by transforming growth factor beta. *J Bone Miner Res* 14:1239–1249
4. Kudo A, Kii I (2018) Periostin function in communication with extracellular matrices. *J Cell Commun Signaling* 12:301–308
5. Maurer LM, Ma W, Mosher DF (2016) Dynamic structure of plasma fibronectin. *Crit Rev Biochem Mol Biol* 51:213–227
6. Lemańska-Perek A, Adamik B (2019) Fibronectin and its soluble EDA-FN isoform as biomarkers for inflammation and sepsis. *Adv Clin Exp Med* 28(11):1561–1567. <https://doi.org/10.17219/acem/104531>
7. Pas J, Wyszko E, Rolle K, Rychlewski L, Nowak S, Zukiel R et al (2006) Analysis of structure and function of tenascin-C. *Int J Biochem Cell Biol* 38:1594–1602
8. Grzegorz LIS, Ewa J, Mariusz G et al (2011) Participation of tenascin C in native and homograft aortic valve degeneration. *Adv Clin Exp Med* 20:157–164

9. Binnetoglu A, Sari M, Baglam T, Erbatur Seven I, Yumusakhuylu AC et al (2015) Fascin expression in cholesteatoma: correlation with destruction of the ossicular chain and extent of disease. *Clin Otolaryngol* 40:335–340
10. Leppanen J, Lindholm V, Isohookana J, Haapasaari KM, Karihtala P, Lehenkari PP et al (2019) Tenascin C, fibronectin, and tumor-stroma ratio in pancreatic ductal adenocarcinoma. *Pancreas* 48:43–48
11. Ichimiya I, Kurono Y, Mogi G (1997) Immunological potential of the tympanic membrane. Observation under normal and inflammatory conditions. *Am J Otolaryngol* 18:165–172
12. Larsson C, von Unge M, Bagger-Sjöbäck D (1999) Tympanic membrane changes in experimental cholesteatoma in the gerbil. *Am J Otol* 20:309–316
13. Bujía J, Kim C, Holly A, Sudhoff H, Ostas P, Kastanauer E et al (1996) Epidermal growth factor receptor (EGF-R) in human middle ear cholesteatoma: an analysis of protein production and gene expression. *Am J Otol* 17:203–206
14. Xie S, Wang X, Ren H, Liu X, Ren J, Liu W (2017) HB-EGF expression as a potential biomarker of acquired middle ear cholesteatoma. *Acta Otolaryngol* 137:797–802
15. Ishibashi T, Shinogami M, Kaga K, Fukaya T (1997) Keratinocyte growth factor and receptor mRNA expression in cholesteatoma of the middle ear. *Acta Otolaryngol* 117:714–718
16. Shinoda H, Huang C (1996) Heat shock proteins in middle ear cholesteatoma. *Otolaryngol Head Neck Surg* 114:77–83
17. Chao J, Dewyer N, McKenna MJ (2019) Spontaneous Resolution of Cholesteatoma in a Patient on Long-Term Infliximab. *Ann Otol Rhinol Laryngol* 128:365–368
18. Sudhoff H, Bujía J, Borkowshi G, Koc C, Holly A, Hildmann H et al (1996) Basement membrane in middle ear cholesteatoma. Immunohistochemical and ultrastructural observations. *Ann Otol Rhinol Laryngol* 105:804–810
19. Lang S, Schilling V, Mack B, Wollenberg B, Nerlich A (1997) Localization of transforming growth factor-beta-expressing cells and comparison with major extracellular components in aural cholesteatoma. *Ann Otol Rhinol Laryngol* 106:669–673
20. Nishizawa H, Matsubara A, Nakagawa T, Ohta N, Izuhara K, Shirasaki T et al (2012) The role of periostin in eosinophilic otitis media. *Acta Otolaryngol* 132:838–844
21. Ishida A, Ohta N, Suzuki Y, Kakehata S, Okubo K, Ikeda H et al (2012) Expression of pendrin and periostin in allergic rhinitis and chronic rhinosinusitis. *Allergol Int* 61:589–599
22. Xu M, Zhang W, Chen D, Zhou H, Chen L (2018) Diagnostic significance of serum periostin in eosinophilic chronic sinusitis with nasal polyps. *Acta Otolaryngol* 138:387–391
23. Ohta N, Ishida A, Kurakami K, Suzuki Y, Kakehata S, Ono J et al (2014) Expressions and roles of periostin in otolaryngological diseases. *Allergol Int* 63:171–180
24. Maxfield AZ, Landegger LD, Brook CD, Lehmann AE, Campbell AP, Bergmark RW et al (2018) Periostin as a Biomarker for Nasal Polyps in Chronic Rhinosinusitis. *Otolaryngol Head Neck Surg* 158:181–186
25. Ninomiya T, Noguchi E, Haruna T, Hasegawa M, Yoshida T, Okano M et al (2018) Periostin as a novel biomarker for postoperative recurrence of chronic rhinosinusitis with nasal polyps. *Sci Rep* 30:11450
26. Clark RA, Erickson HP, Springer TA (1997) Tenascin supports lymphocyte rolling. *J Cell Biol* 137:755–765
27. Midwood KS, Orend G (2009) The role of tenascin-C in tissue injury and tumorigenesis. *J Cell Commun Signal* 3:287–310
28. Paivaniemi OE, Maasilta PK, Alho HS, Vainikka TLS, Salminen US (2008) Epithelial tenascin predicts obliterative airway disease. *J Heart Lung Transplant* 27:400–4007

Publisher's Note

Springer Nature remains neutral with regard to jurisdictional claims in published maps and institutional affiliations.

Submit your manuscript to a SpringerOpen[®] journal and benefit from:

- Convenient online submission
- Rigorous peer review
- Open access: articles freely available online
- High visibility within the field
- Retaining the copyright to your article

Submit your next manuscript at ► [springeropen.com](https://www.springeropen.com)
