



# Atypical Locations of Non Hodgkin Lymphoma and Malignant Melanoma in the Intranasal Cavity

Gonca HANEDAN USLU,<sup>1\*</sup> Burak KART,<sup>1</sup> Gülname FINDIK GÜVENDİ<sup>2</sup>

<sup>1</sup>Department of Radiation Oncology, Recep Tayyip Erdoğan University Faculty of Medicine, Rize-Türkiye

<sup>2</sup>Department of Diagnostic Pathology, Recep Tayyip Erdoğan University Faculty of Medicine, Rize-Türkiye

## Dear Editor,

Intranasal tumors (INTs) are rare among general malignancies and account for 3–4% of head and neck cancers; their symptoms are usually masked by other diseases and therefore they are diagnosed late in the advanced stage.[1] Squamous cell carcinoma is the most common malignant tumor type of the paranasal sinus and nasal cavity. Intranasal squamous tumors account for 1% of all head and neck cancers.[2] Other malignant tumors are more rare and include olfactory neuroblastoma, malignant diffuse B-cell lymphoma, and malignant melanoma.[3] Primary nasal malignant diffuse B-cell lymphoma is extremely rare. It constitutes 0.2%–2% of all non-Hodgkin lymphomas.[4]

Malignant melanoma is a malignancy originating from melanocytes and responsible for 75% of deaths from skin cancer.[5] Although it has the potential to develop in all localizations where melanocytes are present, its development in the nasal cavity is extremely rare. Only 0.5% of all malignant melanomas originate from the nasal cavity.[6] The treatment of these tumors, which generally have a poor prognosis, has not been clarified. Radiotherapy (RT) and/or chemotherapy (CT) may be tried together with surgery. [7] INT treatments consist of surgery, chemotherapy, and radiotherapy, depending on histopathology and stage, and standard treatment schemes for these rare tumors are not clear. It requires a multidisciplinary approach.[8] INT treatments, which are rare in the literature, are not standardized due to the small number of cases. Studies with a sufficient number of patients are needed. In this article, we present two cases

of INT, one with DLBCL-Burkitt-like and another with malignant melanoma, scheduled for RT.

An 84-year-old man complained of right nasal congestion and shortness of breath for about four months and right eye pain for the last month. Rhinoscopic examination revealed a firm mass occluding the right nostril. Contrast-enhanced brain, face, and neck magnetic resonance imaging (MRI) was performed. Brain MRI did not reveal any findings in favor of metastasis. MRI of the face and neck revealed a 38×40 mm irregularly circumscribed malignant mass lesion with heterogeneous diffusion restriction and homogeneous contrast in contrast-enhanced series extending from the right nasal cavity to the ethmoid cells, maxillary-frontal sinus, and inferior orbit. Exophthalmos was present in the right eye due to the lesion (Fig. 1).

Tru-cut biopsy revealed atypical lymphoid cells with diffuse infiltration, large hyperchromatic nucleoli with a prominent nucleolus, partly visible cytoplasm, and diffuse typical-atypical mitotic activity, apoptosis, occasional starry-sky pattern, and focal necrosis. Immunohistochemical examination revealed CD 20 diffuse (+), CD 3 (-), bcl-2 diffuse (+), bcl-6 (-), MUM-1 (+), c-myc (+), and CD10 (-). The Ki-67 proliferation index was 90–100%. It was reported as compatible with high-grade B-cell lymphoma, including findings of Diffuse Large B-cell lymphoma and Burkitt lymphoma (Fig. 2).

Pre-CT PET-CT (F-18 FDG) performed for staging showed pathologic FDG uptake in a 3.9×4.7 cm mass lesion superior to the right nasal cavity, filling the ethmoid sinuses, entering the right orbit medially, and causing exophthalmos in the right eye (SUV<sub>max</sub>: 5.6). The lesion invaded the right maxillary sinus,

\*The current affiliation of the author: Department of Radiation Oncology, Istinye University Hospital, Medical Park Gaziosmanpaşa, İstanbul-Türkiye

Received: November 25, 2023

Accepted: January 27, 2024

Online: February 29, 2024

Accessible online at:

www.onkder.org

Dr. Gonca HANEDAN USLU

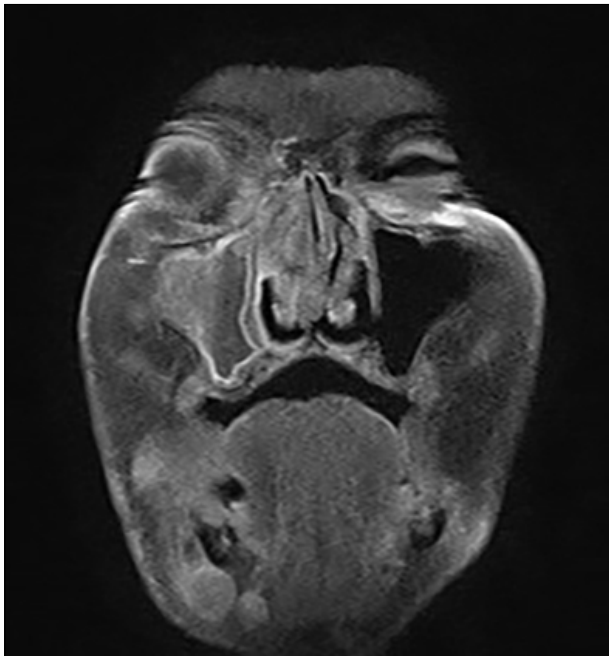Recep Tayyip Erdoğan Üniversitesi Tıp Fakültesi,

Radyasyon Onkolojisi Anabilim Dalı,

Rize-Türkiye

E-mail: gonca.uslu@erdogan.edu.tr





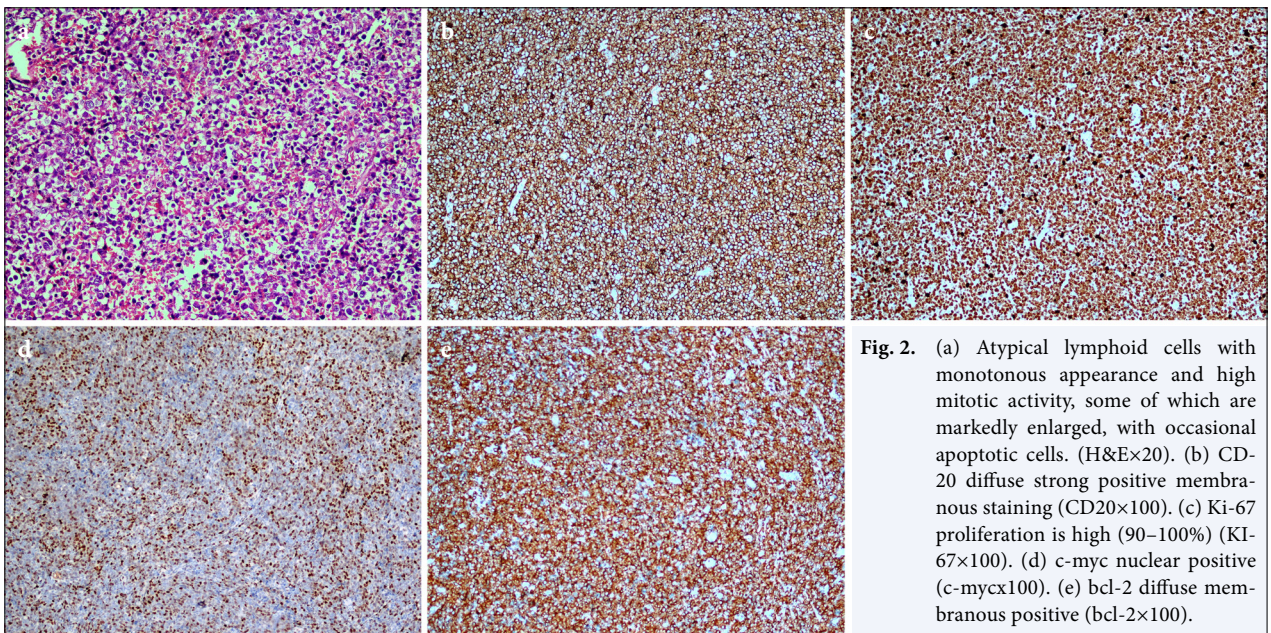
**Fig. 1.** Mass filling the right nasal cavity and maxillary sinus on face and neck MRI.  
MRI: Magnetic resonance imaging.

causing destruction of adjacent bone structures. The left palatine tonsil showed an appearance of asymmetrical filling and pathologic FDG uptake ( $SUV_{max}$ :12.7). Focal increased FDG uptake was also observed in the right palatine tonsil ( $SUV_{max}$ : 6.8). Pathologic FDG uptake was observed in right intraparotitis, right preauricular, bilateral cervical level 2A/2B and 3, right

cervical level 1B, and multiple lymph nodes, the largest of which was 3.1×2.4 cm ( $SUV_{max}$ :18.1) (Fig. 3).

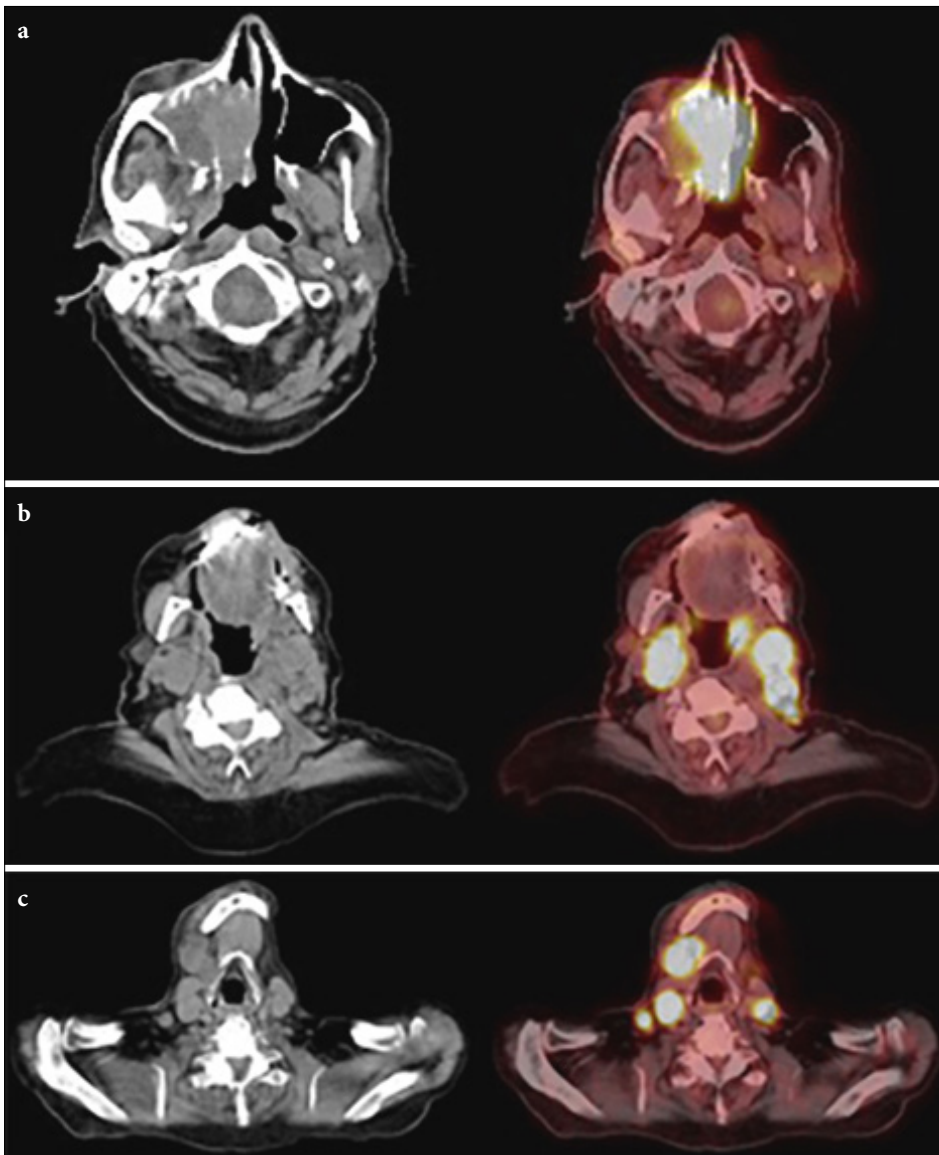
Chemotherapy (CT) and radiotherapy (RT) were planned for the treatment of the patient. Two cycles of chemotherapy R-CHOP (Rituximab 750 mg 1×1, Cyclophosphamide 800 mg 1×1, Vincristine sulfate 2 mg 1×1, Doxorubicin 50 mg 1×1, and Prednisolone 80 mg 1×1) were administered followed by PET-CT (F-18 FDG), which showed a metabolic complete response (Image 4). The patient, in whom a complete response was obtained, was included in RT planning, but RT was not performed because the patient did not accept the treatment. Two months later, the patient's general condition deteriorated, and he died.

A 65-year-old woman had a cream-colored nodular lesion on the skin of the nasal dorsum and brown lesions on the skin of the lateral skin of the right infra-orbital-nasal region, which occurred six years ago. Excisional biopsies were performed from these areas. The biopsy result was compatible with basal cell carcinoma. Lymphovascular and perineural invasion was not present. Since no tumor was observed at the surgical margins, she was followed up without treatment. Six years later (on 23.08.2022), the patient was admitted to the clinic with complaints of a feeling of congestion in the right nose, difficulty breathing, and occasional nosebleeds for about a month. On the rhinoscopic examination that was performed, nasal dorsum, vestibulum, and nares were normal, septum was deviated to the left, and a polypoid, rubbery to the touch, purple, hemorrhagic mass was detected covering the right naris and



**Fig. 2.** (a) Atypical lymphoid cells with monotonous appearance and high mitotic activity, some of which are markedly enlarged, with occasional apoptotic cells. (H&E×20). (b) CD-20 diffuse strong positive membranous staining (CD20×100). (c) Ki-67 proliferation is high (90–100%) (KI-67×100). (d) c-myc nuclear positive (c-mycx100). (e) bcl-2 diffuse membranous positive (bcl-2×100).

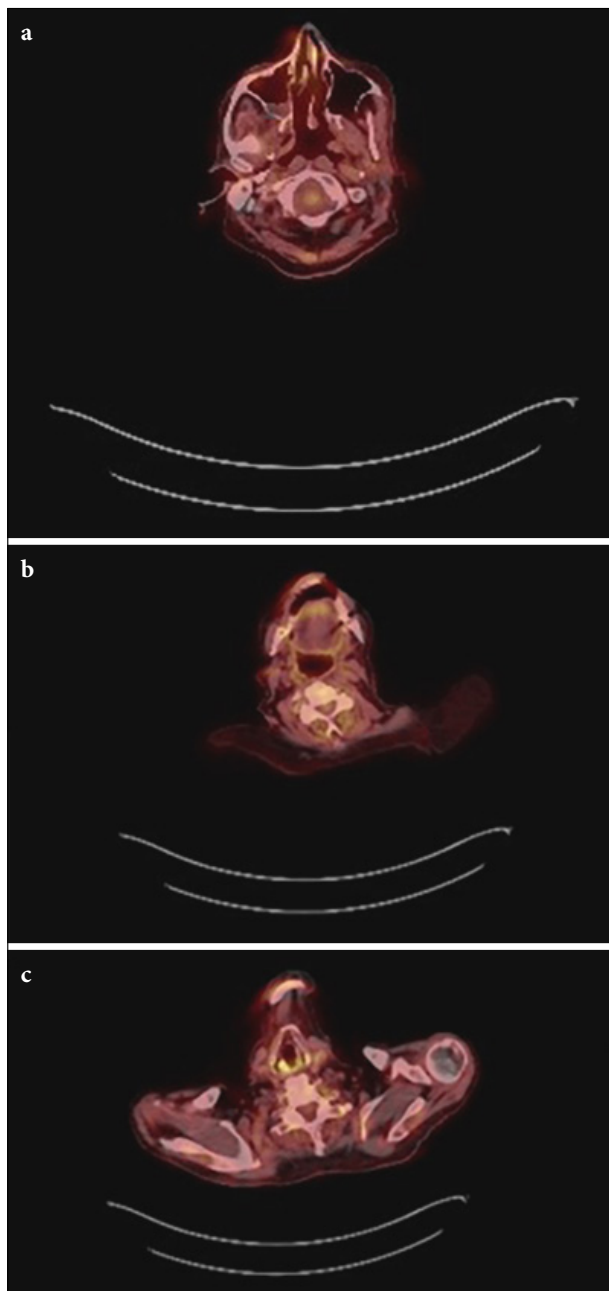




**Fig. 3.** (a) Hypermetabolic mass lesion in the right nasal cavity filling the right maxillary sinus and destructing adjacent bony structures (pre R-CHOP). (b) Pathologic FDG uptake in both palatine tonsils (pre R-CHOP). (c) Bilateral cervical multiple hypermetabolic lymph nodes (pre R-CHOP).

filling the right nasal cavity. Contrast-enhanced brain MRI showed no pathologic involvement. Contrast-enhanced facial MRI revealed mucosal thickening in all paranasal sinuses, left deviation of the nasal septum, and a large spur formation extending to the left. A mass lesion with a soft tissue signal, approximately 3×2 cm in size, associated with the middle turbinate, was observed in the anterosuperior part of the nasal cavity on the right. Diffusion-weighted imaging showed diffusion restriction at the level of the lesion and peripheral diffuse contrast enhancement in the lesion (Fig. 4).

Endoscopic surgery was performed for the mass in the right nasal cavity. In the right nasal cavity, a purple, 2 cm mass originating from the lateral wall and extending anteriorly to the anterior border of the inferior turbinate and above to the border of the lateral cartilage was dissected and removed. Histopathology showed tumoral infiltration consisting of atypical cells with large vesicular nuclei and prominent nucleoli under the epithelium in the tissue sample covered with squamous epithelium. In the immunohistochemical study, tumoral cells were S100 (+), HMB45 (+), SOX-10 (+),



**Fig. 4.** (a) Complete response to a mass in the right nasal cavity filling the right maxillary sinus (post R-CHOP). (b) Complete response in both palatine tonsils (post R-CHOP). (c) Complete response in bilateral cervical LAPs (post R-CHOP).

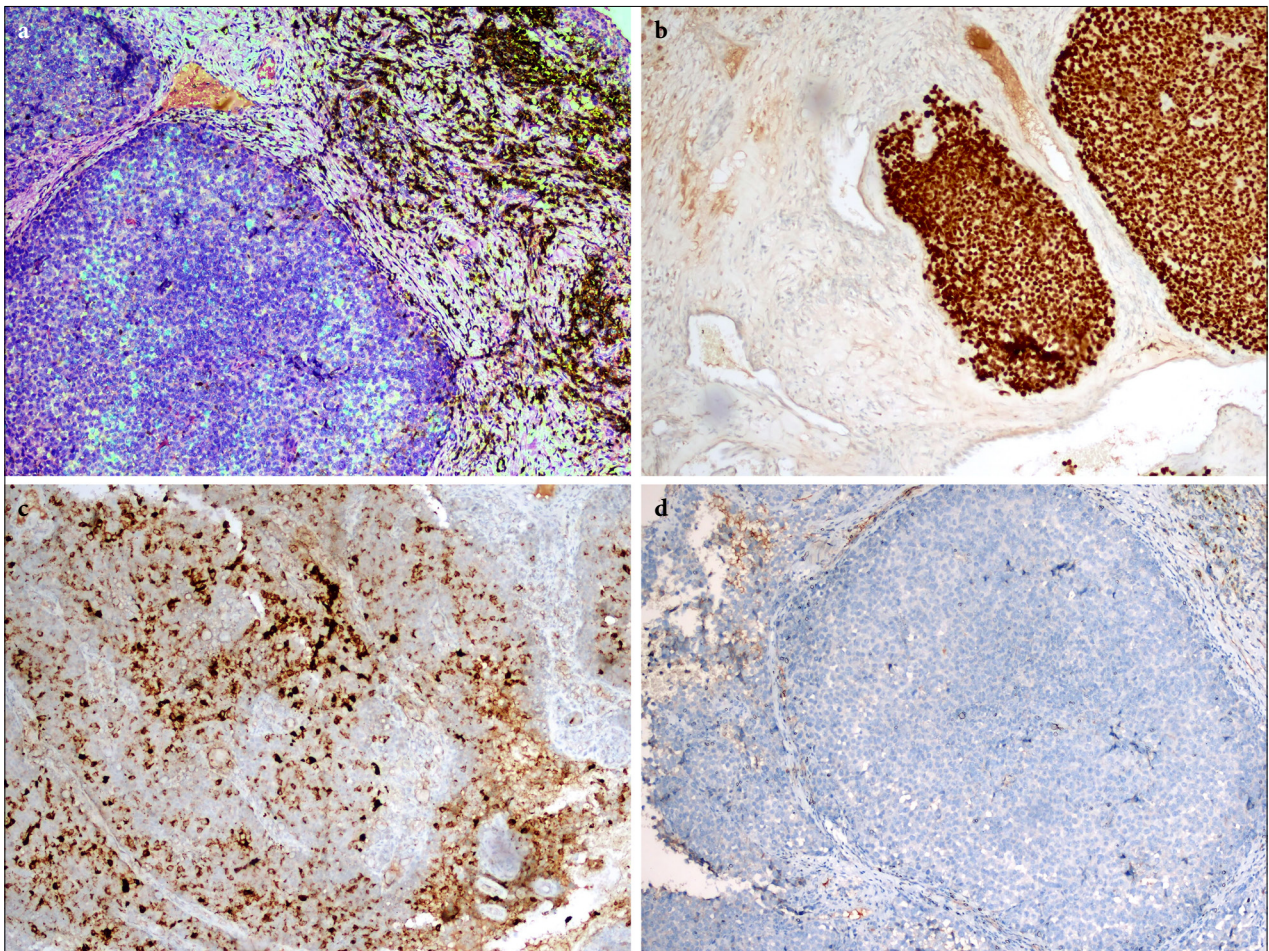
PAN-CK (-), LCA (-), CD34 (-), and the Ki-67 proliferation index was 40–45%. These findings were reported as compatible with malignant melanoma (Fig. 5).

On post-op PET-CT (F-18 FDG), FDG uptake in all systems was within the physiologic limits. The patient was evaluated at the head and neck tumor coun-

cil. Left nasal cavity mucosa resection was performed. No tumor was observed at the surgical margins, and the patient was scheduled for concomitant chemoradiotherapy. Cisplatin 100mg/m<sup>2</sup> was administered every twenty-one days simultaneously across the entire right nasal mucosa, including the nasopharynx, with a dose/fractionation of 200 cGy for a total of 5400 cGy, increasing the skin dose with a 0.5 bolus (Fig. 6). The patient is relapse-free at 2 months.

Tumors in the sinonasal area are rare, affecting less than one in 100,000 people per year. They can be potentially fatal because they are close to the intracranial cavity and can cause obstruction of the respiratory tract. Symptoms include unilateral nasal congestion, bloody discharge, and loss of smell. Although the unilateral nature of the symptoms raises suspicion, they often go unnoticed. It is therefore common for them to be diagnosed late. They may spread to the orbit, nasolacrimal system, cavernous system, pterygomaxillary fissure, and infratemporal fossa and cause disorders such as exophthalmos, proptosis, diplopia, epiphora, trismus, facial pressure, pain, and paresthesia.[9] The most prominent symptoms were epistaxis in the first case and exophthalmos and pain in the second case. Diffuse Large B Cell-Lymphoma is the most commonly occurring type of Non-Hodgkin Lymphoma. However, this may rarely be found primarily in extranodal sites.[10] Primary nasal cavity and paranasal sinus lymphoma demonstrate aggressive behavior and often relapse.[11] Chemotherapy is the primary treatment for nasal DLBCL followed by IFRT.[4] In a study by Kwak et al.,[12] the final local control rate after radiotherapy was 94%. In addition, early-stage patients tend to achieve longer overall survival than advanced-stage patients.[13,14] The median survival time and overall survival of advanced-stage patients are only 12.2 months and 20.3 months, respectively.[13] There is no standard treatment for this type of disease, but treatment of localized aggressive non-Hodgkin lymphoma (NHL) with a combination of radiotherapy and chemotherapy is widely accepted. Therefore, in our first case, the patient was planned to be treated with chemotherapy and sequential radiation therapy. According to previous studies, patients diagnosed with this disease were always treated with CHOP (cyclophosphamide, doxorubicin, vincristine, and prednisone) or CHOP-derived chemotherapy.[13,15] Considering that the classical CHOP regimen may fall short of treating this lymphoma, CHOP and rituximab were used in the treatment of our patient since CD20 expression was positive in the tumor. After treatment, PET-CT proved that the patient had a complete tumor





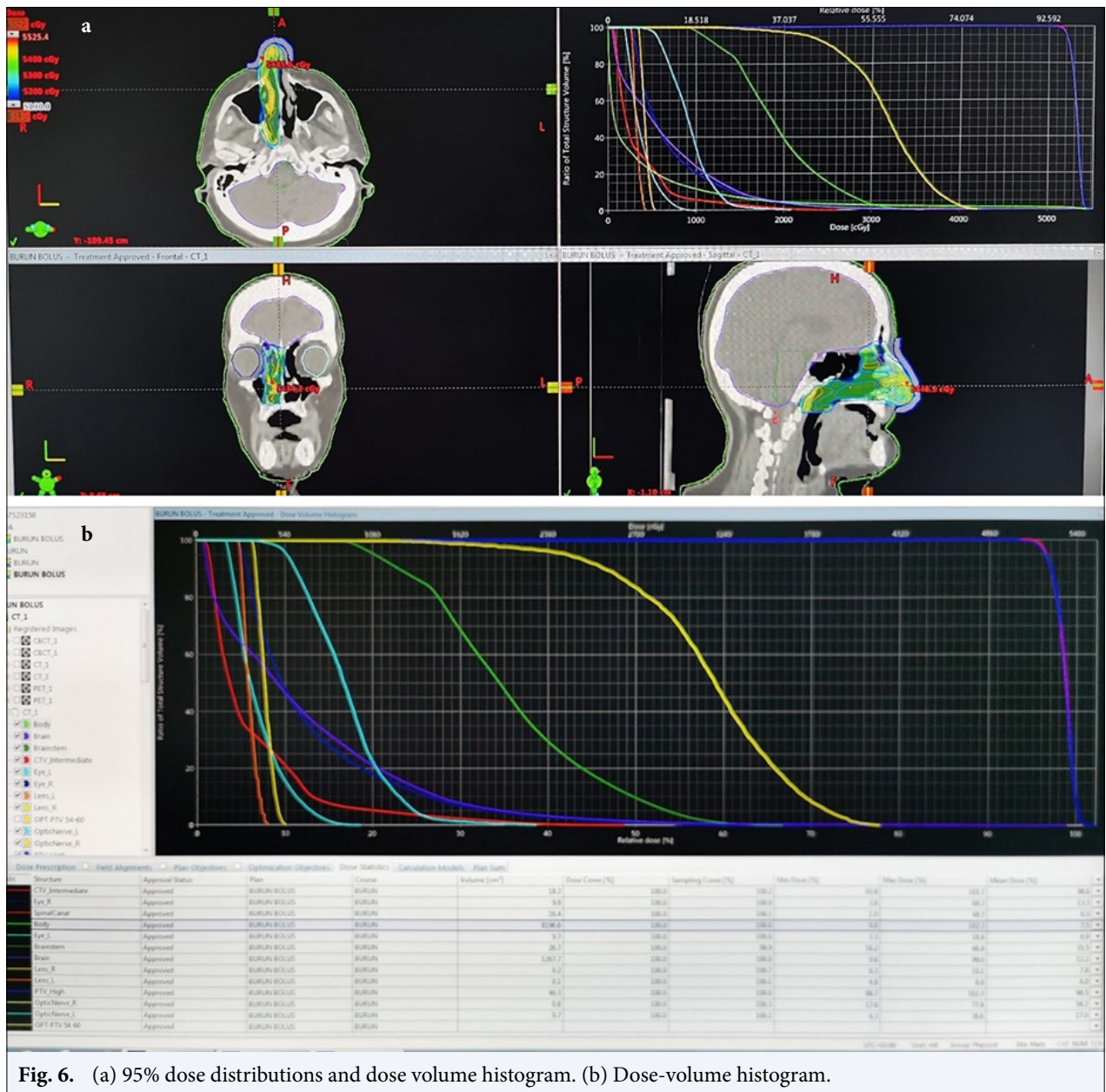
**Fig. 5.** (a) Nodular atypical cells with basophilic cytoplasm, vesiculated nuclei and frequent mitotic activity (H&E×100). (b) SOX-10 diffuse strong nuclear positive in atypical cells (SOX-10×100). (c) HMB-45 focal membranous type positive (HMB-45×100). (d) PAN-CK negative (PAN-CK×100).

response. The headaches and nosebleeds completely disappeared. Radiotherapy was then planned for the relevant region, but the patient did not accept RT. The patient died due to age and comorbidities.

Primary mucosal melanoma of the nasal cavity and paranasal sinuses is a rare tumor.[16,17] In Western Europe, melanomas of the head and neck account for less than 1% of all melanomas.[18,19] Histologically, tumors are composed of various cell groups. Immunohistochemical studies revealed that tumor cells generate a positive reaction with S-100 protein, tyrosinase, HMB-45, melan-A, and microphthalmia transcription factor.[20] In our case, pathologic findings were consistent with the literature. Treatment options essentially consist of radical surgery and radiotherapy, while chemotherapy is reserved for advanced forms. Despite a better knowledge of this tumor, the 5-year overall survival remains poor and does not

exceed 40% in any of the published studies.[21] In a clinicopathologic study of 115 patients with mucosal melanoma, the mean age was found to be 64.3 years.[20] Our patient was 65 years old. Since the tumor has a highly fatal course, the treatment plan should be administered immediately. Surgery is the most important factor in the local control and cure of malignant mucosal melanoma. Surgery can be accompanied by RT or CT or their combination.[20] In a multicenter retrospective study of 160 patients by Benlyazid et al.,[22] 82 patients who underwent surgery alone and 78 patients who received postoperative RT were evaluated. In this large-scale study, the rate of locoregional revision was higher in the postoperative RT group. Locoregional recurrence was 55.6% in the group that underwent only surgery and 24.5% in the group that received postoperative RT. In another study with thirty-four cases, surgical resection was performed in 27





**Fig. 6.** (a) 95% dose distributions and dose volume histogram. (b) Dose-volume histogram.

patients, while 4 patients were also administered RT, 1 received RT+CT, and 3 received CT along with surgery. Of the remaining 7 patients, 1 received only CT, and 6 received only RT, and as a result, it was shown that combined approaches provided a much better prognosis than single treatment options.[23] In our second case, chemoradiotherapy was performed after surgery for primary nasal mucosal melanoma. Progression-free follow-up two months after treatment. Since INT cases are limited in number, the standard treatment is not very clear and remains unambiguous. Prospective studies with large numbers of patients are needed to establish a gold standard treatment.

## REFERENCES

1. Perri F, Addeo R, Conson M, Faiella A, Scarpati GDV, Torre G, et al. Locally advanced paranasal sinus carcinoma: A study of 30 patients. *Oncol Lett* 2017;13(3):1338–42.
2. Bussu F, Tagliaferri L, Mattiucci G, Parrilla C, Dinapoli N, Miccichè F, et al. Comparison of interstitial brachytherapy and surgery as primary treatments for nasal vestibule carcinomas. *Laryngoscope* 2016;126(2):367–71.
3. Uslu GH, Canyilmaz E, Zengin AY, Mungan S, Yoney A, Bahadir O, et al. Olfactory neuroblastoma: A case report. *Oncol Lett* 2015;10(6):3651–4.

4. Lu NN, Li YX, Wang WH, Jin J, Song YW, Zhou LQ, et al. Clinical behavior and treatment outcome of primary nasal diffuse large B-cell lymphoma. *Cancer* 2012;118(6):1593–8.
5. Davis LE, Shalin SC, Tackett AJ. Current state of melanoma diagnosis and treatment. *Cancer Biol Ther* 2019;20(11):1366–79.
6. Bhartiya R, Prasad KM. Malignant melanoma of nasal cavity - a case report. *J Clin Diagn Res* 2015;9(12):ED21–2.
7. Nobuhiko W, Hiroshi I, Eiko K, Tadashi D, Susumu B, Kaori N, et al. A case report of primary malignant melanoma of the nasopharynx. *Practica Otologica Kyoto* 2004;97(4):307–12.
8. Llorente JL, López F, Suárez C, Hermsen MA. Sinonasal carcinoma: Clinical, pathological, genetic and therapeutic advances. *Nat Rev Clin Oncol* 2014;11(8):460–72.
9. Lund VJ, Clarke PM, Swift AC, McGarry GW, Kerawala C, Carnell D. Nose and paranasal sinus tumours: United Kingdom National Multidisciplinary Guidelines. *J Laryngol Otol* 2016;130(S2):S111–8.
10. Hao S, Sun Y, Hu C, Zhi Y, Xiao H, Li Y. Primary nasal diffuse large B-cell lymphoma with synchronous pulmonary involvement: A case report. *Medicine* 2019;98(17):e15439.
11. Karantanis D, Subramaniam RM, Peller PJ, Lowe VJ, Durski JM, Collins DA, et al. The value of [(18)F]fluorodeoxyglucose positron emission tomography/computed tomography in extranodal natural killer/T-cell lymphoma. *Clin Lymphoma Myeloma* 2008;8(2):94–9.
12. Kwak YK, Choi BO, Kim SH, Lee JH, Kang DG, Lee JH. Treatment outcome of diffuse large B-cell lymphoma involving the head and neck: Two-institutional study for the significance of radiotherapy after R-CHOP chemotherapy. *Medicine Baltimore* 2017;96(25):e7268.
13. Laurent C, Do C, Gascoyne RD, Lamant L, Ysebaert L, Laurent G, et al. Anaplastic lymphoma kinase-positive diffuse large B-cell lymphoma: A rare clinicopathologic entity with poor prognosis. *J Clin Oncol* 2009;27:4211–6.
14. Reichard KK, McKenna RW, Kroft SH. ALK-positive diffuse large B-cell lymphoma: Report of four cases and review of the literature. *Mod Pathol* 2007;20:310–9.
15. De Paepe P, Baens M, van Krieken H, Verhasselt B, Stul M, Simons A, et al. ALK activation by the CLTC-ALK fusion is a recurrent event in large B-cell lymphoma. *Blood* 2003;102:2638–41.
16. Chan RC, Chan JYW, Wei WI. Mucosal melanoma of the head and neck: 32-Year experience in a tertiary referral hospital. *Laryngoscope* 2012;122:2749–53.
17. Marcus DM, Marcus RP, Prabhu RS, Owonikoko TK, Lawson DH, Switchenko J, et al. Rising incidence of mucosal melanoma of the head and neck in the United States. *J Skin Cancer* 2012;2012:231693.
18. Douglas CM, Malik T, Swindell R, Lorrigan P, Slevin NJ, Homer JJ. Mucosal melanoma of the head and neck: Radiotherapy or surgery? *J Otolaryngol Head Neck Surg* 2010;39(4):385–92.
19. Mendenhall WM, Amdur RJ, Hinerman RW, Werning JW, Villaret DB, Mendenhall NP. Head and neck mucosal melanoma. *Am J Clin Oncol* 2005;28(6):626–30.
20. Thompson LD, Wieneke JA, Miettinen M. Sinonasal tract and nasopharyngeal melanomas: A clinicopathologic study of 115 cases with a proposed staging system. *Am J Surg Pathol* 2003;27(5):594–611.
21. Patrick RJ, Fenske NA, Messina JL. Primary mucosal melanoma. *J Am Acad Dermatol* 2007;56:828–33.
22. Benlyazid A, Thariat J, Temam S, Malard O, Florescu C, Choussy O, et al. Postoperative radiotherapy in head and neck mucosal melanoma: A GETTEC study. *Arch Otolaryngol Head Neck Surg* 2010;136:1219–25.
23. Folz BJ, Niemann AM, Lippert BM, Hauschild A, Werner JA. Mucous membrane melanomas of the upper aerodigestive tract: An analysis of 34 cases. *Laryngorhinootologie* 1997;76(5):289–94.