

Surprise Lesion in the Cecum: Benign Multicystic Peritoneal Mesothelioma

Çekumda Sürpriz Bir Lezyon: Benign Multikistik Peritoneal Mezotelyoma

Çiğdem Öztürk¹, Hasan Gündoğdu², Oğuzhan Okcu³, Tuğçe Bölme Şavlı⁴

¹Recep Tayyip Erdoğan University Training and Research Hospital, Department of Pathology, Rize, Turkey

²Recep Tayyip Erdoğan University Training and Research Hospital, Department of Radiology, Rize, Turkey

³Recep Tayyip Erdoğan University Faculty of Medicine, Department of Pathology, Rize, Turkey

⁴Gaziantep Cengiz Gökçek Gynecology and Pediatrics Hospital, Clinic of Pathology, Gaziantep, Turkey

Abstract

Benign multicystic peritoneal mesothelioma (BMPM) is a rare neoplasm that is difficult to distinguish from other cystic neoplasms radiologically. A 41-year-old female patient was admitted to the emergency service with a complaint of abdominal pain. After the physical examination, and radiological imaging, ovarian torsion was assumed, and a gynecological laparoscopy was planned. A firm mass was observed in the cecal region during gynecological laparoscopy, and a right hemicolectomy was performed. There was a multicystic mass measuring 4x4x2.5 cm in the cecal region of the specimen is sent to the pathology department. Morphological findings on hematoxylin-eosin sections and immunohistochemical studies supported it, and a diagnosis of BMPM was made. The diagnosis of BMPM, which can be a challenging process considering its clinical and radiological features, is mainly made pathologically. These lesions frequently recur and rarely show a malignant transformation. Therefore, it must be evaluated in the pathological differential diagnosis.

Keywords: Benign, cecum, mesothelioma, multicystic, periton

Öz

Benign multikistik peritoneal mezotelyoma (BMPM), radyolojik olarak diğer kistik neoplazmlardan ayırt edilmesi zor olan nadir bir neoplazmdir. Kırk bir yaşında kadın hasta karın ağrısı şikayeti ile acil servise başvurdu. Fizik muayene ve radyolojik görüntüleme sonrasında over torsiyonu düşünülerek jinekolojik laparoskopi planlandı. Jinekolojik laparoskopi sırasında çekum bölgesinde sert kitle görüldü ve sağ hemikolektomi yapıldı. Patoloji bölümüne gönderilen örneğin çekum bölgesinde 4x4x2,5 cm boyutlarında multikistik kitle mevcuttu. Hematoksilen-eozin kesitlerindeki morfolojik bulgular ve immünohistokimyasal çalışmalar ile BMPM tanısı konuldu. Klinik ve radyolojik özellikleri göz önüne alındığında zorlu bir süreç olabilen BMPM'nin tanısı esas olarak patolojik olarak konur. Bu lezyonlar sıklıkla tekrarlar ve nadiren malign transformasyon gösterirler. Bu nedenle ayırıcı tanıda mutlaka akılda bulundurulmalıdır.

Anahtar kelimeler: Benign, çekum, mezotelyoma, multikistik, peritoneal

Introduction

Benign multicystic peritoneal mesothelioma (BMPM) is an exceedingly rare tumor that is more common in women. It accounts for 3-5% of all peritoneal mesotheliomas, with an annual incidence of 2/1,000,000 (1). It is more common in women of reproductive age to an average age of 36 years (2).

Although the pathogenesis of BMPM has not yet been fully elucidated yet, past surgical operations, endometriosis, and pelvic inflammatory disease (PID) are blamed for the pathogenesis (3,4). In this article, we aimed to present benign peritoneal mesothelioma, a rare lesion that mimics malignancy, which should be taken into account in the differential diagnosis of cystic lesions.



Address for Correspondence: Çiğdem Öztürk, Recep Tayyip Erdoğan University Training and Research Hospital, Department of Pathology, Rize, Turkey

Phone: +90 506 806 95 55 **E-mail:** dr.ozturkciğdem@gmail.com **ORCID:** orcid.org/0000-0003-2587-214X **Received:** 06.11.2022 **Accepted:** 28.01.2023

Cite this article as: Öztürk Ç, Gündoğdu H, Okcu O, Bölme Şavlı T. Surprise Lesion in the Cecum: Benign Multicystic Peritoneal Mesothelioma. Bagcilar Med Bull 2023;8(1):99-102

©Copyright 2023 by the Health Sciences University Turkey, Bagcilar Training and Research Hospital
Bagcilar Medical Bulletin published by Galenos Publishing House.

Case Report

A 41-year-old female patient was admitted to the emergency service with the complaint of abdominal pain lasting for 4 days. The patient's clinical history indicates no relevant disease. However, she had a history of cholecystectomy 4 years ago and a tubal ligation operation 10 months ago. She was also hospitalized for PID 8 months ago and recovered after receiving treatment for the infection. In the first examination, tenderness was detected in the right lower quadrant of the abdomen. Abdominal ultrasonography (USG) revealed an increased size of the right ovary, decreased blood supply, and the presence of free fluid in the Douglas cavity. Findings observed in the USG were interpreted as ovarian torsion. In the abdominal computed tomography (CT), a 45x40 mm hypodense lesion was observed in the right lower quadrant (Figure 1). The obstetrician performed a diagnostic laparoscopic examination and the uterus and ovaries were observed naturally. However, the procedure was terminated to obtain a general surgical opinion due to the appearance of a mass on the intestine in the ileocecal region.

Magnetic resonance imaging (MRI) demonstrated a thick-walled, multicystic mass lesion with heterogeneous

contrast enhancement in the paracecal region (Figure 2). The patient was operated on with a preliminary diagnosis of plastron appendicitis. Right hemicolectomy was performed due to a 3 cm mass observed in the ileocecal region during the operation. After the operation, 32 cm long right hemicolectomy material was sent to our pathology department. In the cecal region, a lesion of 4x4x2.5 cm with a multicystic appearance with a raised serosa was observed (Figure 3a). In the microscopic examination, numerous cystic structures of varying diameters, sometimes flat, some of them swollen and with large eosinophilic cytoplasm, some of them lined with cells in the appearance of hobnails, were observed. Eosinophilic amorphous material was present in the cystic spaces. The surrounding stroma of the cyst structures was composed of loose fibrovascular connective tissue (Figure 3b-d). In immunohistochemical studies, staining of Calretinin with PanCK was observed in these cells surrounding the cystic structures. No staining was observed with CD31, CD34, D2-40, ER, and Pax8 (Figure 3e, f). With the support of immunohistochemical studies, the case was diagnosed as benign multicystic peritoneal mesothelioma. No additional treatment was planned for the patient after diagnosis, close follow-up by

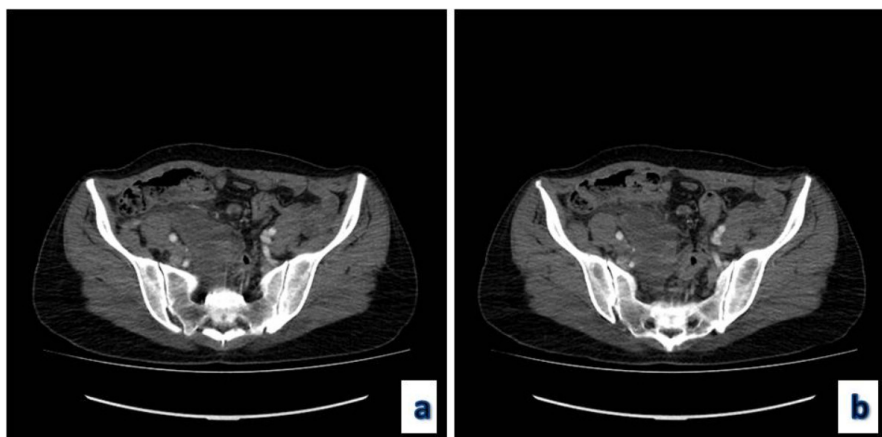


Figure 1 a, b. Abdominal computed tomography images of the patient before the laparoscopy

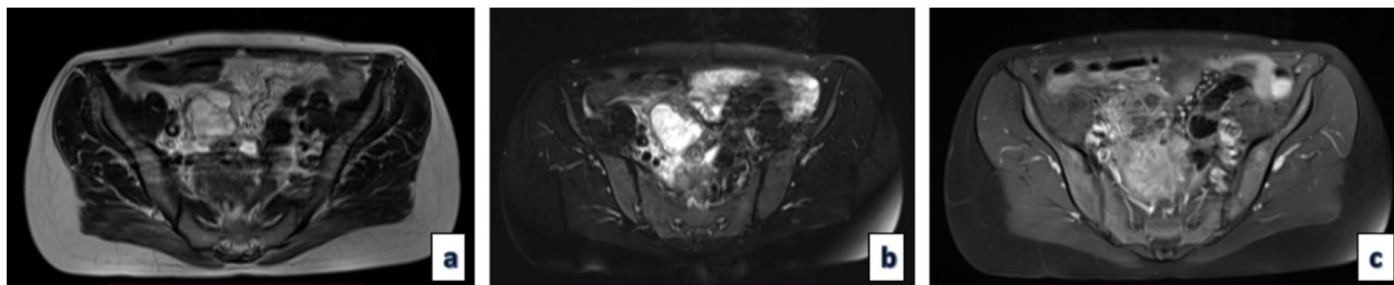


Figure 2. a) T2-weighted axial MR images showed a thick-walled, multicystic mass lesion in the paracecal region, **b)** no signal loss on fat-suppressed T2-weighted images, **c)** heterogeneous contrast enhancement on post-contrast images

MR: Magnetic resonance

general surgery was recommended and no recurrences were detected during the 36-month post-operative period.

Discussion

A benign peritoneal mesothelial cyst is extremely rare. Multiple peritoneal cysts were first described by Plaut in 1928, and in 1979 it was confirmed that they were of mesothelial origin (5,6). Although it is not related to asbestos, the etiology is not fully known. However, previous surgery, endometriosis, and PID have been reported in the pathogenesis (3,4). Chronic inflammation and previous surgery are thought to trigger the migration of mesothelial cells. The history of previous surgery and PID in our case support this. However, it has been suggested that this disease has a neoplastic etiology since patients without a history of chronic inflammation and surgical operation have also been reported in the literature (7,8). The appearance of the lesion after previous surgery varies between 6 months and 20 years (8). Patients are mostly diagnosed incidentally on imaging or during laparotomy performed for different reasons. When clinically present,

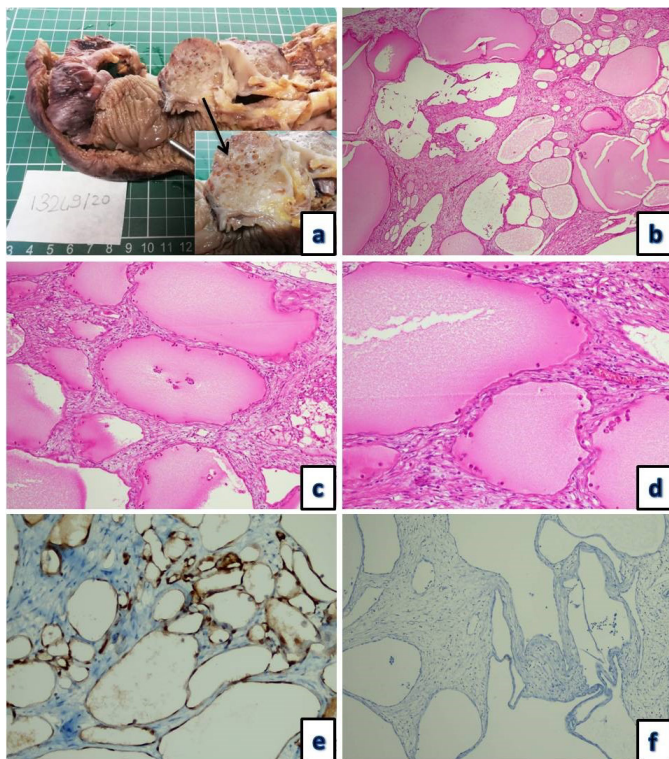


Figure 3. Multicystic lesion in the cecum on the surgical specimen (a). Variable-sized cysts lined by flattened mesothelial cells and filled with amorphous eosinophilic material (b: HEx40, c: HEx100, d: HEx200). Immunohistochemical staining shows calretinin in the lining cells (e: Calretinin x100) and the negative staining of D2-40 (f: D2-40x100)

it triggers symptoms such as abdominal pain, distention, intestinal obstruction, nausea, and vomiting, depending on the location of the lesion (5,9).

In pre-operative imaging, these lesions can often mimic different lesions, such as ovarian malignancy and cystic lymphangioma. On ultrasonographic examination, it typically presents as grape-like, multilocular, thin-walled cysts containing fluid and multiseptated anechoic cysts. In magnetic resonance imaging, it is observed as multilocular, thin-walled septal, fluid density masses (10). Lymphangioma, malignant peritoneal mesothelioma, and cystic adenomatoid tumor should be considered in the differential diagnosis (11). On MRI, BMPM exhibits low signal intensity on T1-weighted images and high signal intensity on T2-weighted images, reflecting high fluid content (10). In our case, the initial CT could not distinguish between ovarian cystic neoplasia. Usually, it is not possible to distinguish other cystic lesions with USG, CT, and MRI. Therefore, the diagnosis is often made postoperatively (10,11).

Although there is no consensus yet on treatment, complete resection is the recommended first step (12). Complete surgical excision helps to prevent the risk of malignant transformation and recurrence, yet more aggressive approaches can also be recommended since half of the cases suffer from recurrence. After cytoreductive surgery, hyperthermic intraperitoneal chemotherapy can be preferred to reduce the risk of recurrence and malignant transformation. Hormonal treatments such as antiestrogen and gonadotropin analogs are also recommended. Recurrence has been reported frequently, ranging from 27% to 75% (11). The risk of malignant transformation is much less common. Only 2 cases have been reported in the literature so far (13).

Conclusion

Because the preoperative diagnosis of BMPM is challenging via clinical findings and imaging methods, its diagnosis is commonly made by postoperative pathological examination. Although the risk of malignant transformation is low, recurrence is seen in almost half of the cases. It should be taken into account in the differential diagnosis from other cystic lesions in the pathological examination, and these cases should be followed up closely after the operation.

Ethics

Informed Consent: The patient was informed about her published histopathological and radiological images and her written consent was obtained.

Peer-review: Externally and internally peer-reviewed.

Authorship Contributions

Surgical and Medical Practices: Ç.Ö., Concept: Ç.Ö., H.G., O.O., Design: Ç.Ö., H.G., O.O., Data Collection or Processing: Ç.Ö., H.G., O.O., Analysis or Interpretation: Ç.Ö., O.O., T.B.Ş., Literature Search: Ç.Ö., T.B.Ş., Writing: Ç.Ö., T.B.Ş.

Conflict of Interest: No conflict of interest was declared by the authors.

Financial Disclosure: The authors declared that this study received no financial support.

References

- Noiret B, Renaud F, Piessen G, Eveno C. Multicystic peritoneal mesothelioma: a systematic review of the literature. *Pleura Peritoneum* 2019;4(3):20190024.
- Pitta X, Andreadis E, Ekonomou A, Papachristodoulou A, Tziouvaras C, Papapoulou L, et al. Benign multicystic peritoneal mesothelioma: a case report. *J Med Case Rep* 2010;4:385.
- Chand MT, Edens J, Lin T, Anderson I, Berri R. Benign multicystic peritoneal mesothelioma: literature review and update. *Autops Case Rep* 2020;10(3):e2020159.
- Gussago S, Spina P, Guerra A. Benign Multicystic Peritoneal Mesothelioma (BMPM) as a rare cause of abdominal pain in a young male: case report and review of the literature. *J Surg Case Rep* 2019;2019(3):rjz057.
- Dzieniecka M, Kałużnyński A. Benign multicystic peritoneal mesothelioma (BMPM) - case report and review of the literature. *Pol J Pathol* 2011;62(2):122-124.
- Zeiler M, Santarelli S, Cangiotti AM, Agostinelli RM, Monteburini T, Marinelli R, et al. Giant mesenteric cyst of mesothelial origin in a haemodialysis patient with previous peritoneal dialysis therapy. *Nephrol Dial Transplant* 2010;25(3):1004-1006.
- Zhang CH, Yu JW, Luo M. Multicystic peritoneal mesothelioma: A short review. *Curr Probl Cancer* 2017;41(5):340-348.
- McFadden DE, Clement PB. Peritoneal inclusion cysts with mural mesothelial proliferation. A clinicopathological analysis of six cases. *Am J Surg Pathol* 1986;10(12):844-854.
- Alvir I, Bevanda B, Danolić D, Mamić I, Kostić L, Starčević-Božović A, et al. Benign multicystic peritoneal mesothelioma mimicking gynecologic pathology. *Acta Clin Croat* 2021;60(2):323-325.
- Momeni M, Pereira E, Grigoryan G, Zakashansky K. Multicystic benign cystic mesothelioma presenting as a pelvic mass. *Case Rep Obstet Gynecol* 2014;2014:852583.
- Cha KS, Choi YH, Lee YS, Park EK. Benign multicystic peritoneal mesothelioma treated with laparoendoscopic single site surgery: a case report and review of the literature. *Obstet Gynecol Sci* 2018;61(1):170-174.
- Lee CE, Agrawal A. Remote Recurrence of Benign Multicystic Peritoneal Mesothelioma. *J Obstet Gynaecol Can* 2017;39(11):1042-1045.
- Takemoto S, Kawano R, Honda K, Nakazono A, Shimamatsu K. Benign multicystic peritoneal mesothelioma mimicking recurrence of an ovarian borderline tumor: a case report. *J Med Case Rep* 2012;6:126.